

МИНИСТЕРСТВО ЗДРАВООХРАНЕНИЯ РЕСПУБЛИКИ БЕЛАРУСЬ
УЧРЕЖДЕНИЕ ОБРАЗОВАНИЯ
«ГОМЕЛЬСКИЙ ГОСУДАРСТВЕННЫЙ МЕДИЦИНСКИЙ УНИВЕРСИТЕТ»

Кафедра онкологии с курсом лучевой диагностики и лучевой терапии

Н. М. ЕРМОЛИЦКИЙ

ЛУЧЕВАЯ ДИАГНОСТИКА

Учебно-методическое пособие
для студентов 3 курса факультета по подготовке специалистов
для зарубежных стран медицинских вузов

В двух частях

Часть 1

RADIOLOGY

Teaching workbook
for 3rd year students of the Faculty of preparation of experts
for foreign countries of medical higher educational institutions

In two parts

Part 1

Гомель
ГомГМУ
2016

УДК 615.849(072)=111

ББК 53.6я73

Е 74

Рецензенты:

кандидат медицинских наук, доцент,
директор Институт радиобиологии Национальной академии наук Беларуси

И. А. Чешик;

кандидат медицинских наук, доцент,
заведующий клинико-диагностической лабораторией
Республиканского научно-практического центра
радиационной медицины и экологии человека

Ю. И. Ярец

Ермолицкий, Н. М.

Е 74 Лучевая диагностика: учеб.-метод. пособие для студентов 3 курса факультета по подготовке специалистов для зарубежных стран медицинских вузов: в 2 ч. = Radiology: Teaching workbook work for 3rd year students of the Faculty of preparation of experts for foreign countries of medical higher educational institutions: in two parts / Н. М. Ермолицкий. — Гомель: ГомГМУ, 2016. — Ч. 1. — 108 с.

ISBN 978-985-506-828-1

Учебно-методическое пособие подготовлено в соответствии с типовой программой по специальности «Лечебное дело», включены темы, изучаемые в начальном семестре, и в связи с этим содержит необходимые для усвоения разделы дисциплины: принципы и методы диагностической радиологии; основы защиты от ионизирующих излучений; радиология опорно-двигательной системы, грудной клетки и сердечно-сосудистой системы.

Материалы адаптированы к русскоязычному варианту изложения лучевой диагностики и лучевой терапии с учетом объема часов, могут быть использованы студентами старших курсов факультета по подготовке специалистов для зарубежных стран при изучении терапевтических и хирургических дисциплин.

Предназначено для студентов 3 курса факультета по подготовке специалистов для зарубежных стран медицинских вузов.

Утверждено и рекомендовано к изданию научно-методическим советом учреждения образования «Гомельский государственный медицинский университет» 29 июня 2016 г., протокол № 3.

УДК 615.849(072)=111

ББК 53.6я73

ISBN 978-985-506-784-0

ISBN 978-985-506-828-1 (Ч. 1)

© Учреждение образования

«Гомельский государственный
медицинский университет», 2016

CONTENTS

1. Overview and principles of diagnostic radiology imaging.	
Contrast radiologic examinations. An approach to image interpretation.	
Protection in radiological practice	4
2. Radiology of musculoskeletal system.....	38
3. Chest imaging.....	60
4. Cardiovascular system imaging	95
References	105

1. OVERVIEW AND PRINCIPLES OF DIAGNOSTIC RADIOLOGY IMAGING

Introduction

The realm of diagnostic radiology encompasses various modalities of imaging that may be used individually or, more commonly, in combination to provide the clinician with enough information to aid in making a diagnosis.

Of high importance in today's managed care environment, diagnostic imaging can also be used for the early identification of potential medical problems, to help prevent their occurrence.

Radiologists and other physicians interpret the resulting images to diagnose various medical illness or injury so that patient treatment and therapy can be specifically planned and implemented. Diagnostic imaging is also used to guide surgical planning and is often used to follow surgery and/or monitor the outcomes of therapeutic procedures.

The newest frontier in diagnostic imaging, molecular imaging, makes possible the identification of certain molecules within cell structures.

Main areas of diagnostic radiology imaging

The specialty of radiology includes conventional techniques that use ionizing radiation: X-ray examinations, computed tomography (CT); and nuclear medicine (NM).

High quality diagnostic radiology images also may be obtained via the techniques of magnetic resonance imaging (MRI) and ultrasound (US), thereby avoiding the risks of radiation.

Three modes of image production

There are three basic means by which radiologic images are produced: transmission of energy, reflection of energy, and emission of energy. Physicians have understood this, and they also know that the three methods are complementary, each providing information at a different level.

Transmission imaging

Radiograph is produced by the transmission of energy. A beam of high-energy photons is passed through the body, some of which are attenuated or blocked when they strike subatomic particles. The principal transmission modalities include plain radiography (such as chest radiographs and abdominal radiographs), fluoroscopy, and CT.

Fluoroscopy represents a kind of «movie», or moving picture, in which continuous detection and display of the pattern of photon transmission enables the visual

lization of dynamic processes in real time. CT gathers transmission data from multiple perspectives and employs a mathematical algorithm (the Fourier transform) to reconstruct an image of the slice of tissue through which the x-ray beams passed.

Reflection imaging

The radiologic modality that exemplifies reflection imaging is ultrasound. As we shall see, ultrasound creates images not according to the density differences between various tissues, but by their acoustic differences. A very low-density structure such as fat, which appears black on a radiograph, may be very «echogenic» acoustically, and hence appear bright on a sonogram.

Emission imaging

The emission modalities include MRI and nuclear medicine. MRI creates images by distinguishing between the nuclear magnetic properties of various tissues. MRI also utilizes no ionizing radiation, generating images using a magnetic field and radio waves.

The other emission modality, nuclear medicine, creates images by introducing radioisotopes into the human body and then detecting their emission of gamma rays (like x-rays, except from a different source). In contrast to MRI, nuclear medicine involves ionizing radiation.

Different types of ionizing radiation

The gamma (γ) ray corresponds to the emission of short wavelength and variable energy photons (figure 1.1–1.2). This radiation translates the loss of excessive energy in the nucleus and its transformation into a more stable state, as opposed to the production of X-rays, obtained after excitation and ionization of electrons. X- and gamma rays are ideal medical diagnosis tools. As they are very penetrating, they can go through large thicknesses of matter and travel for hundreds of meters in the air. Dense materials such as lead, very thick concrete or deep water are able to stop them or, at least, strongly attenuate them.

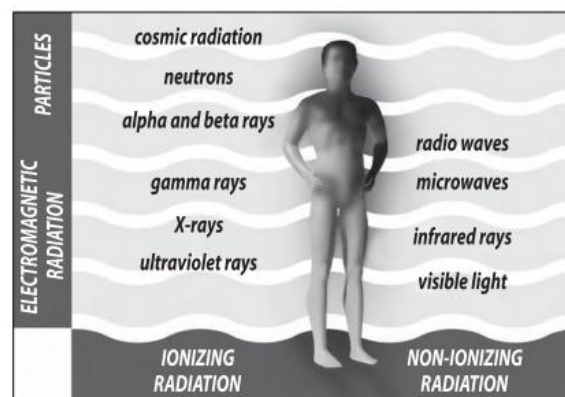


Figure 1.1 — Different types of radiations to which man is daily exposed

An X-ray is an electromagnetic wave of the same type as light waves, but with a higher energy level, thus capable to some extent of travelling through matter. The technique is based on matter's capacity to attenuate an external beam of X-rays depending on whether it is solid, liquid or gaseous. Therefore, organs will allow radiation to pass through them according to their density, thickness and constitution; the intensity of the rays is measured on photographic film or using a specific detector. Initial applications distributed on organs and tissues presenting a different coefficient of absorption.

Definition

X-rays, or roentgen rays, are a form of electromagnetic radiation or energy of extremely short wavelength. X-rays in the diagnostic range are near the end of the spectrum of short wavelengths. The shorter the wavelength of an electromagnetic radiation form, the greater its energy and, as a rule, the greater its ability to penetrate various materials.

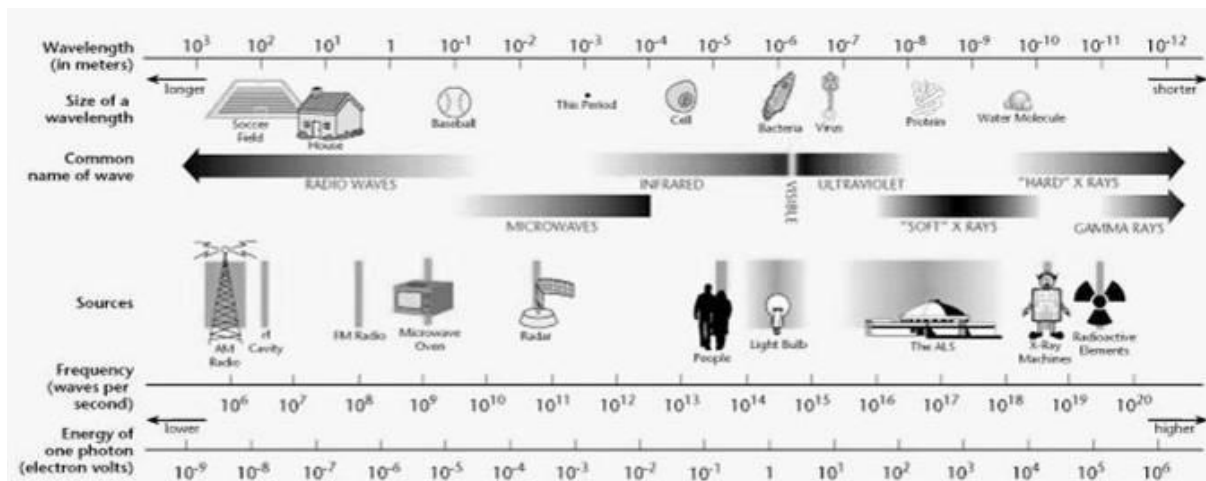


Figure 1.2 — Electromagnetic spectrum extending over several orders of magnitude listing values of wavelengths, frequency, and identifying values in some of the more common regions of the spectrum. Ionizing radiation has sufficient energy to penetrate human tissue.

X-rays are described in terms of particles or packets of energy called quanta or photons, which travel at the speed of light. The amount of energy carried by each photon depends on the wavelength of the radiation. This is measured in electron volts. An atom is ionized when it loses an electron. Any photon with approximately 15 or more electron volts of energy is capable of producing ionization in atoms and molecules (ionizing radiation). X-rays, γ -rays, and certain types of ultraviolet radiation are all typical ionizing radiation forms.

Production of X-Rays

X-rays used in diagnostic radiology require a vacuum and the presence of a high potential difference between a cathode and an anode. Moving these elec-

trons toward the anode at an energy level sufficient to produce x-rays requires a high potential — up to 125,000 V (125 kV). When the accelerated electrons strike the tungsten anode, x-rays are produced.

X-rays follow the same physical laws as light, and as such, will darken photographic (or, in the past x-ray) film. For the purpose of this discussion, the word «film» is used interchangeably with any type of recording medium (digital receptor plates).

Production of images

Image production by x-rays results from attenuation of those x-rays by the material through which they pass. Attenuation is the process by which x-rays are removed from a beam through absorption and scatter. In general, the greater the material's density — that is, the number of grams per cubic centimeter — the greater its ability to absorb or scatter x-rays. Absorption is also influenced by the atomic number of the structure. The denser the structure, the greater the attenuation, which results in less blackening of the «film» (fewer x-rays strike the «film»). Less-dense structures attenuate the beam to a lesser degree and result in more blackening of the «film» (more x-rays strike the «film», figure 1.3). A small percentage of the incident radiation beam exits the patient and strikes a detector. An image receptor is required to convert the radiation into an image after it has passed through the area of interest.

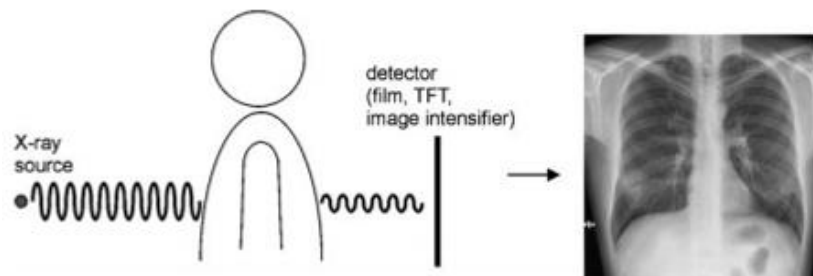


Figure 1.3 — X-rays penetrate the human body and produce an image that shows of tissue-specific absorption along a path from the X-ray source to a detector

Radiographic density

It is important to differentiate between two types of densities that you will hear mentioned when discussing radiographs with radiologists or other colleagues: physical density and radiographic density. Physical density is the type of density just described. Radiographic density refers to the degree of blackness of a film. Radiographic contrast is the difference in radiographic densities on a film. The radiographic density of a substance is related to its physical density. The effect on film or other recording media occurs paradoxically: structures of high physical density produce less radiodensity and vice versa. Structures that produce more blackening on film are referred to as being radiolucent; those that produce less blackening are called radiopaque or radiodense. There are four

types of radiographic densities; in increasing order of physical density, these are gas (air), fat, soft tissue (water), and bone (metal). Radiographically, these appear as black, gray-black, gray, and white, respectively.

Both density and thickness tissues, then, are factors to take into account in assessing the degree of opacification noted on a radiograph (figure 1.4). Radiographs were initially referred to as «skiagraphs», from the Greek for «shadow pictures», because they represent recordings of the shadows cast by anatomic structures as photons pass through the body.

Plain radiography may be conceptualized as a snapshot: it provides a static view of anatomic structure obtained in a fraction of a second.

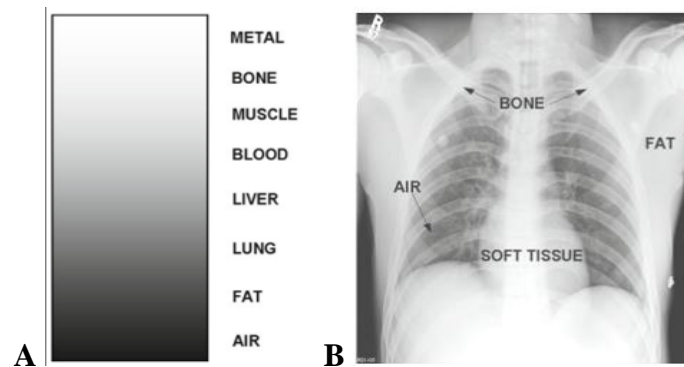


Figure 1.4 — (A) Diagram of radiographic densities on NEGATIVE image. (B) Note how the four basic densities are visible on negative frontal chest radiograph

Recording media (detector)

X-ray film

The most common type of recording medium used to be x-ray film. X-ray film is still used in many parts of the world. However, state-of-the-art radiology departments have replaced x-ray film with electronic recording media.

X-ray film consists of a plastic sheet coated with a thin emulsion that contains silver bromide and a small amount of silver iodide. This emulsion is sensitive to light and radiation. A protective coating covers the emulsion. When the film is exposed to light or to ionizing radiation and then developed, chemical changes take place within the emulsion, resulting in the deposition of metallic silver, which is black. The amount of blackening on the film depends entirely on the amount of radiation reaching it and therefore on the amount attenuated or removed from the beam by the subject.

The classic imaging receptor is a film/screen combination into cassette. The x-ray beam strikes a fluorescent screen (into cassette), which produces light that exposes the film, and then the film is developed.

Fluoroscopic screen (for fluoroscopy)

A fluoroscopic screen is coated with a substance (phosphor) that gives off visible light (or fluoresces) when it is irradiated. The brightness of the light is

proportional to the intensity of the x-ray beam striking the plate and depends on the amount of radiation removed from the beam by the object being irradiated. Today, the fluoroscopic screen is combined with an electronic device that converts the visible light into an electron stream that amplifies the image (makes it brighter) by converting the electron pattern back into visible light.

This system allows the radiologist to see the image clearly without requiring dark adaptation of the eyes, as was necessary in non-image-enhanced fluoroscopy. The technology of image intensification was originally developed around 1950 for military use at night. Intensifying screens, variants of fluoroscopic screens, were used in most film cassettes to reduce the amount of radiation needed to produce an acceptable exposure.

A little bit of history

In 1895, Dutch physicist Wilhelm Conrad Roentgen developed equipment that could generate an unknown radiation, unknown because indefinable and original, which he called X. Wilhelm Roentgen succeeded in creating the first image of an X-rayed hand and demonstrated that human tissues behave differently depending on their density.

This first radiography of Mrs Roentgen's hand, dating from 1896, became famous and opened the way for a new discipline of medicine, diagnostic and therapeutic radiology (figure 1.5).

The recognition of the value and advantages of this technology was such that special radiology services were created within five years.

Plain film (x-ray, projection, conventional) radiography

The x-rays are directed in a limited beam towards the patient (figure 1.5). The radiograph itself is a two-dimensional representation of the three-dimensional structures of the patient's body. These structures are visible because of the differences in attenuation of the x-ray beam. Attenuation refers to the process by which x-rays are removed.

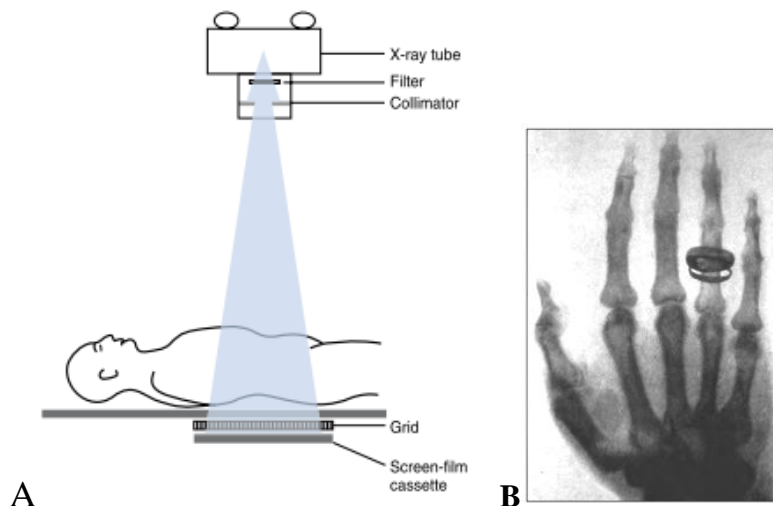
Plain radiographs are often called «plain X-rays» — but you can't see the X-rays, only the images created by them. Radiographs can be produced using a variety of imaging methods. The image or picture is basically a shadow of the parts of the patient that absorb or block the X-rays.

The radiographic image is a «photographic negative» of the object — the «shadows» are white regions (where the X-rays were blocked by the object). The image is black in the regions that did not stop the X-rays, and they passed through to expose the film or sensor.

Plain radiographs («plain films») are usually taken by a trained registered radiologic technologist. The resulting films or images are then interpreted by the radiologist to make a diagnosis or suggest further tests.

Radiography is more particularly used in orthopaedics, rheumatology and orthodontics. It is also very informative in pneumology (preventive radiology of the lungs or where there is a suspicion of lung cancer) and in oncology (mam-mography, preventive examination for the detection of breast cancer).

Principle radiography: the rays pass through the area under investigation, and depending on the tissues, a variable amount is absorbed — this is known as differential attenuation. The exact amount of whiteness depends on how much calcium or other heavy metal is present. Bone containing calcium — absorbs almost all of the rays and so shows up as white, fat absorbs much less, and air absorbs none so it appears black. The rays can then be imaged either using film, to get a conventional x-ray, or can be detected using special equipment to get digital radiographs. The routine x-ray is a shadow picture.



**Figure 1.5 — (A) Scematic representation of film screen radiography.
(B) Radiograph of Mrs Roentgen's hand, taken in 1896**

A patient that has just been subject to a radiological examination is not radioactive, even if X-rays are a form of radioactivity. Outside the field, the effect of the radiation disappears. Progress in these last years has effectively aimed at reducing both the time taken to acquire the image and the dose necessary for this acquisition, while still maintaining, even improving, quality.

Projection radiography terminology

Typical x-ray projections (figure 1.6)

X-ray projections are typically listed as AP or PA. This depends on whether the x-ray beam passed to the patient from anterior to posterior (AP) or the reverse. Lateral (LAT) and oblique (OBL) views also are commonly obtained.

Note: the word 'view' is often used erroneously to describe a radiographic projection.

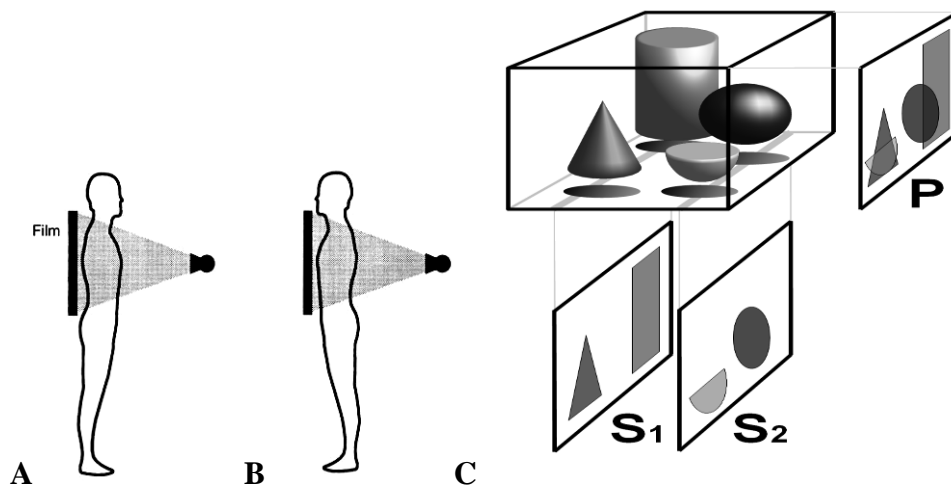


Figure 1.6 — (A) Variants antero-posterior and (B) postero-anterior of the projections. (C) Principles (P) of projections and (S) tomography

Basic radiologic projections:

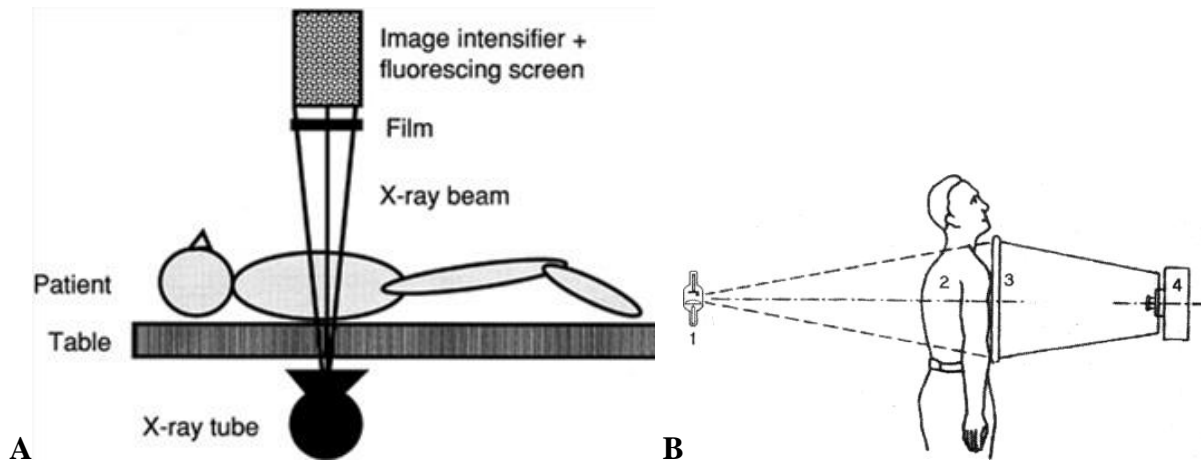
- *frontal* — projection taken with the central ray to the midsagittal plane;
- *lateral* — projection taken with the central ray perpendicular to the midsagittal plane;
- *oblique* — projection taken with the central ray at an angle to any of the body planes. Described by the angle of obliquity and the portion of the body the X-ray beam exits; right or left and posterior or anterior. For example «a 45 degree right anterior oblique of the cervical spine»;
- *prone* — patient lies on their front, also known as «planking»;
- *supine* — patient lies on the back;
- *decubitus* — patient laying down. Further described by the downside body surface: dorsal (backside down), ventral (frontside down), or lateral (left or right side down).

Fluoroscopy

Fluoroscopy enables real-time radiographic visualization of moving anatomic structures. A continuous x-ray beam passes through the patient and falls onto a fluorescing screen (figure 1.7). The faint light pattern emitted by the fluorescing screen is amplified electronically by an image intensifier, and the image is displayed on a television monitor and recorded digitally as a single image or series of images for real-time viewing (i.e., a movie). Fluoroscopy is extremely useful to evaluate motion such as GI peristalsis, movement of the diaphragm with respiration, and cardiac action. Fluoroscopy is also used to perform and monitor continuously radiographic procedures, such as barium studies and catheter placements. Video and static fluoroscopic images are routinely stored in digital format. Fluoroscopy is a technique for obtaining «live» X-ray images of a living patient.

Fluorography (X-ray photography)

Fluorography is used mostly as a preventive X-ray method for examination of much amount of people. Sometimes it can be used as a diagnostic procedure for revealing changes in X-ray picture at therapy of a patient. Fluorography must never be applied as a primary diagnostic procedure for it has low resolution.



**Figure 1.7 — (A) This diagram of a fluoroscopic unit illustrates the components of the system. The real-time fluoroscopic images are viewed on a television monitor and may be recorded on videotape. Radiographs are obtained by digital image capture or by placing a film cassette between the patient and the image intensifier and exposing the image receptor with a brief pulse of radiation. (B) Scheme of fluorography. The components of the method:
1 — X-ray tube; 2 — patient; 3 — output fluorescent screen; 4 — photo camera**

Principle: the x-ray radiation is produced in an x-ray tube, passes through a patient's body and gets on the fluorescent screen (figure 1.7). Under influence of radiation the screen shines and the image appears on it. Then the image is automatically photographed by the special camera with a narrow film. The film is developed and studied with the help of enlarging opticians.

Advantages:

- speed of a method;
- cheapness of a method — small sizes of the image — small amount of used silver in a film;
- the objectivity — fluorogram (video) is the document;
- opportunity of carrying out of mass examinations — owing to cheapness and speed of a method;
- no limit of time for examine of fluorogram.

Disadvantages:

- high radiation doze for patient;
- low resolution — because of the small sizes of the image the small details are poorly visible;
- impossibility of study of function — image on a film is static.

Conventional tomography

Conventional (linear) tomography provides radiographic images of slices of a living patient. This is done by simultaneously moving both the x-ray tube and the x-ray detector around a pivot point centered in the patient in the plane of the anatomic structures to be studied (figure 1.8). Structures above and below the focal plane are blurred by the motion of the tube and detector. Objects within the focal plane are visualized with improved detail as a result of the blurring of the overlying and underlying structures. With wide availability of cross-sectional imaging, the use of conventional tomography is currently quite limited.

Mammography

Mammography is a specific type of imaging that uses a low-energy x-ray system for the examination of breasts with high resolution of structures. Example indications: palpable breast mass, screening for breast cancer.

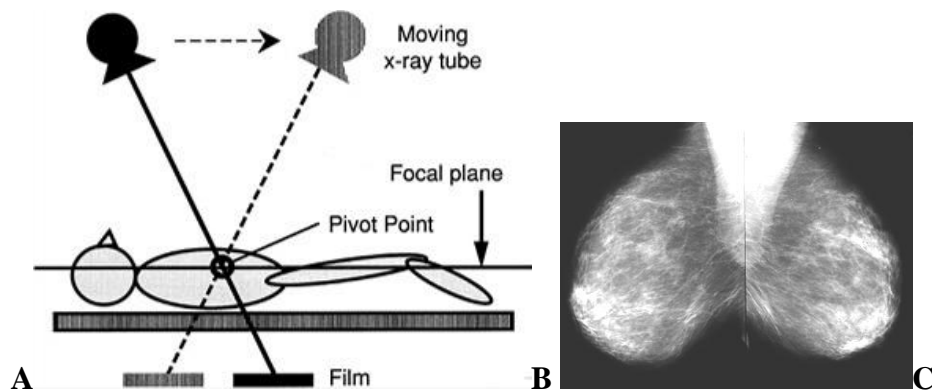


Figure 1.8 — (A) Scheme of linear tomography. In this technique, the x-ray tube and film simultaneously move about a pivot point at the level of the desired focal plane. Anatomic structures within the focal plane remain in sharp focus, whereas the structures above and below the focal plane are blurred by the motion of the tube and film. (B-C) Mammograms, craniocaudal projections: (B)-right mammary gland; (C)-left mammary gland (age-normal variant)

Mammography is the first investigation of choice for a breast lump in women over 30 years of age, though US is increasingly used in younger women. Diagnostic mammography may also be performed for other reasons such as nipple discharge, or to search for a primary breast tumour where metastases are found elsewhere. Screening mammography is performed to search for early cancers in asymptomatic women.

The standard mammographic examination consists of two views: craniocaudal and lateral oblique. A range of further views may be used to delineate an abnormality seen on the two standard views. These include spot compression, magnification, and craniocaudal views angulated medially or laterally (figure 1.8).

X-ray mammography is performed utilizing a radiographic film, screen and digital combination.

Digital radiography

X-ray technologies was revolutionized by the advent of digital imaging. Digital radiography (computed radiography) replaces the screen/film system of conventional radiographic techniques by processing image data in digital (computer) rather than analog form. The essential parts of a digital radiography system are the image plate and the image reader (figure 1.9). Any conventional x-ray system can be used for the x-ray generation.

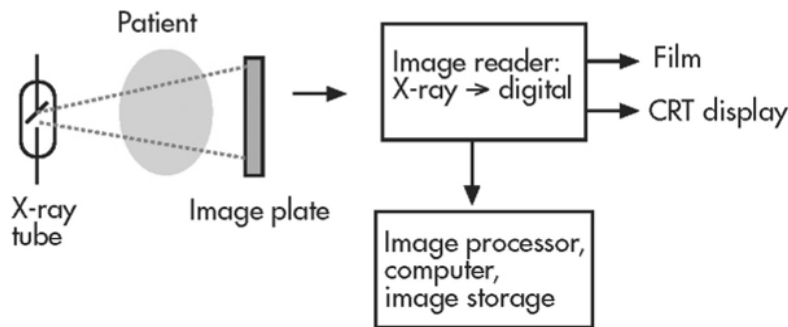


Figure 1.9 — Diagram of the digital radiography system

Digital images often look sharper and cleaner than the analog version. Many of the fluoroscopic x-ray procedures have benefited greatly from the addition of digital technology. Using picture archiving and communication systems (PACS), images are acquired, stored, and retrieved electronically, making images available anytime and anywhere. The advantages of this technology include high detection efficiency and rapid image display. These systems have excellent image quality and allow a significant reduction in effective dose compared with conventional film-screen based systems.

Cross-sectional imaging techniques

CT, MR, and US are techniques that produce cross-sectional images of the body. All three interrogate a three-dimensional volume or slice of patient tissue to produce a two-dimensional image. The resulting image is made up of a matrix of picture elements (pixels), each of which represents a volume element (voxel) of patient tissue.

To produce an anatomic image, shades of gray are assigned to ranges of pixel values. The middle gray shade is assigned to the pixel values centered on a selected window level. Pixels with values greater than the upper limit of the window width are displayed white, and pixels with values less than the lower limit of the window width are displayed black. To analyze optimally all of the anatomic information of any particular slice, the image is viewed at different window-width and window-level settings, which are optimized for bone, air-filled lung, soft tissue, and so forth.

The digital images obtained by CT, MR, and US examination are ideal for storage and access. Among the features that can be used are interactive altera-

tions in window width and window level, magnification, fusing of images from different modalities, reformatting serial images in different anatomic planes, creation of three-dimensional reconstructions, and marking of key images that summarize major findings.

Computed tomography

Computer (assisted) tomography (CAT-scanning), X-ray computed tomography, also computed tomography (CT) or computed axial tomography (CAT) is the process where a computer can fabricate a model of the densities of an object or a person by rotating the source of x-rays around the object and looking at the shadows (figure 1.10).

CT-scanning, another name for tomography (from the Greek *tomein* meaning «to slice»), has improved the quality of results of X-ray examinations.

Principle: computed tomography uses x-rays, but the x-ray tube rotates around the patient as the table moves, creating a vast number of images. The principle behind the computed tomography image is differential absorption of x-rays by various tissues. The only difference is that the images are produced by computer rather than directly on film.

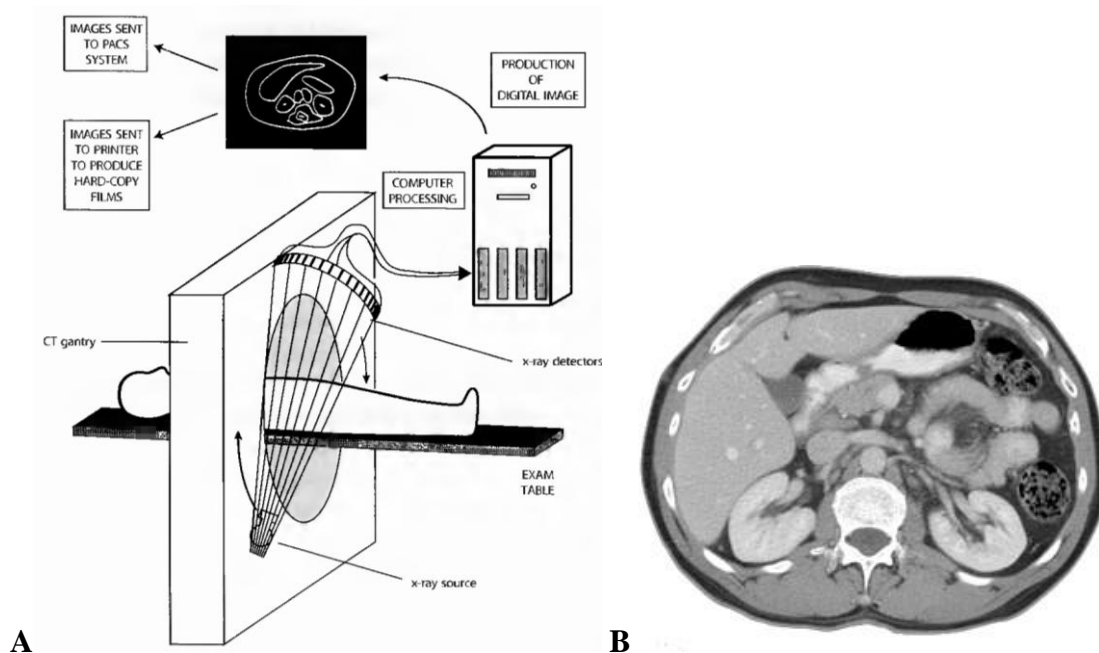


Figure 1.10 — (A) Diagram of the standard computed tomography system. (B) axial tomogram of abdomen displayed using «soft tissue windows» to evaluate the upper abdominal structures. Gas is black; bone and contrast medium of aorta and stomach are white; muscle and hepar are light grey; and fat is dark grey

The x-rays are processed by computer to form axial, coronal, or sagittal images. These may be adjusted by the radiologist to show detail of the soft tissue;

bone; or, in the thorax. Modern scanners allow this volume of data to be reformatted in various planes or even as volumetric 3D representations of structures.

Once an image is produced, however, further processing is possible to optimize desired image characteristics, such as the contrast between soft tissue structures. This accounts for the difference between so-called soft tissue windows, bone windows, and lung windows on a chest CT examination. Through postimaging processing, it is also possible to «reconstruct» the data acquired in one plane (in CT, generally the axial plane, figure 1.11) in other planes (e.g., the coronal or sagittal planes).

CT has the ability to detect minute differences in the densities of tissues and portray them in varying shades of gray. These CT densities are measured in Hounsfield units, after Godfrey Hounsfield, the father of CT. Distilled water at a standard pressure is given a value of 0 and air is given a value of $-1,000$. Bone densities are very high, up to $+1,000$; soft tissue values falling in between.

Once an image is produced, however, further processing is possible to optimize desired image characteristics, such as the contrast between soft tissue structures. This accounts for the difference between so-called soft tissue windows, bone windows, and lung windows on a chest CT examination. Through postimaging processing, it is also possible to «reconstruct» the data acquired in one plane (in CT, generally the axial plane) in other planes (e.g., the coronal or sagittal planes).

Once the digital information has been acquired, the software equipping these tools gives the radiologist the option of navigating from one organ to another, and of isolating a particular element in order to be able to focus on the element of interest. Then, the entire data, including the images, can be sent to a colleague for confirmation or additional expertise with a simple click of the mouse.

CT and MR usually present images as transverse (axial) slices of the body. If, as you stand and look at the patient from the foot of the bed, you think of these images as slices lifted out of the body, you will have the orientation correct.

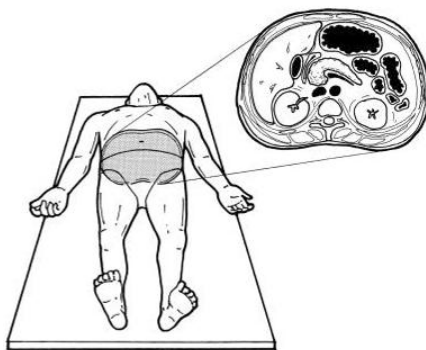


Figure 1.11 — Orientation of computed tomography axial images

Advantages:

- CT produces images that are far more detailed than a chest x-ray.
- CT is especially useful because it can simultaneously show many different types of tissue, including the lungs, heart, bones, soft tissues.

— Because of the inherent high-contrast resolution of CT, differences between tissues that differ in physical density by less than 1 % can be distinguished. Ideal for evaluation of mediastinal masses.

— Data from a single CT imaging procedure consisting of either multiple contiguous or one helical scan can be viewed as images in the axial, coronal, or sagittal planes, depending on the diagnostic task. This is referred to as multiplanar reformatted imaging.

Limitation:

— Patient doses from CT examinations are relatively high. Compared with plain x-rays, CT uses about 10 to 100 times more radiation.

Nuclear medicine

In nuclear medicine studies, however, carrier molecules labelled with a radioactive tracer, usually metastable ^{99m}Tc , are injected into the patient. Because the patient is injected with the tracer, he or she becomes the source of the radiation and emits gamma rays (figure 1.12). A patient who has been injected with a radioactive tracer is slightly radioactive, but the activity is constantly falling.

Principle: uses unsealed radioactive substances in diagnosis (and therapy).

How it is done:

- Studies start with by injecting or inhaling or ingesting a radionuclide.
- The type of isotope used varies with each study.
- The radionuclide concentrates in the organ that is being tested.
- Scanning of body or organ follows.
- When to start and end scanning, varies with each study.
- Majority of diagnostic tests involve formation of an image using gamma camera.
- Most diagnostic radionuclides emit gamma rays.

Example indications:

- Renal scintigraphy: to evaluate renal function.
- Bone scintigraphy: to evaluate bone metastasis.
- Perfusion lung scan: suspected patients with pulmonary embolism.
- Myocardium view: suspected patients with coronary artery disease.
- Testicular scan: to evaluate testicular torsion.

Advantages:

— Radionuclide imaging is safe since it does not carry the risk of allergic reaction encountered with contrast.

- Primarily useful to evaluate the function of the organ studied.
- High sensitivity.
- Radiation exposure is minimal.

Disadvantages:

- Non-specificity.
- Not good resolution.

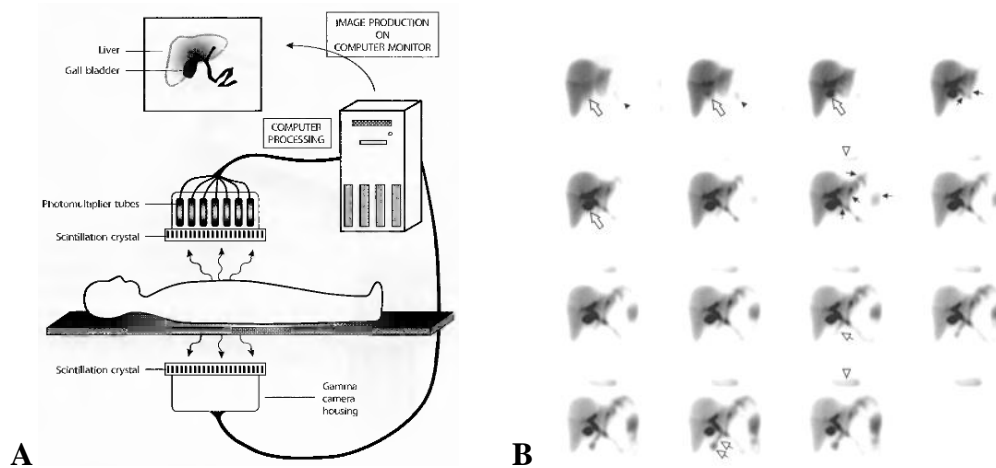


Figure 1.12 — (A) Diagram of the standard two-head gamma camera and production of nuclear medicine scintigraphy images. (B) Normal dynamic hepatobiliary scintigrams

In nuclear medicine studies, a dose of radiation is given internally to the patient and the x-rays are counted as they leave his or her body. Some nuclear medicine studies provide functional information in addition to the anatomic information of conventional radiographic techniques.

Ultrasound

In ultrasonography (US, sonography), a probe is applied to the patient's skin, and a high frequency (1 to 20 MHz) beam of sound waves is focused on the area of interest (figure 1.13). The sound waves propagate through different tissues at different velocities, with denser tissues allowing the sound waves to move faster. A detector measures the time it takes for the wave to reflect and return to the probe. Ultrasounds are waves that are imperceptible to the human ear, but which retain such properties as reverberation (echo) or matter absorption (attenuation). By taking advantage of these two characteristics and the properties of tissue subject to ultrasound, it has been possible to develop a tool capable of measuring and analysing the nature of its reflection according to the tissue through which it has travelled and off which it has bounced. Measurement of the time required for the wave to be detected also permits the distance travelled to be calculated.

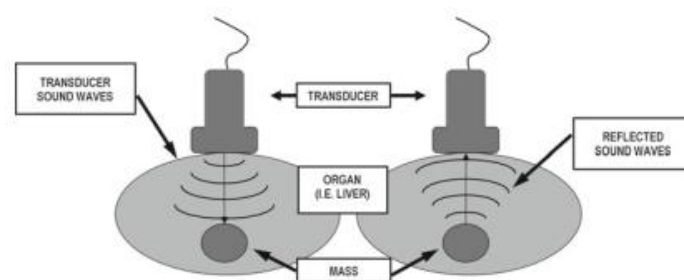


Figure 1.13 — Principle of ultrasound. The transducer sends a short burst of high frequency sound into the tissue. Some part of the sound is reflected back by the tissues and the reflected signal is «read» by the transducer and an image is created

Tissue density is determined by the reflection time and an image is produced on the screen for the ultrasonographer to see in real time (figure 1.14). Normal soft tissue appears as medium echogenicity. Fat is usually more echogenic than soft tissue. Simple fluid, such as bile, has low echogenicity, appears dark, and often has «through-transmission» or brightness beyond it. Complex fluid, such as blood or pus, may have strands or separations within it, and generally has lower through-transmission than simple fluid.

Calcification usually appears as high echogenicity with posterior «shadowing», or a «dark band» beyond it. Air does not transmit sound waves well and does not permit imaging beyond it, as the sound waves do not reflect back to the transducer. Therefore, bowel gas and lung tissue are a hindrance to ultrasound imaging.

Principle:

- The use of high-frequency sound waves to produce real-time images, provides a simple and painless way to examine structures.

- A transducer sends out sound waves, which reflect off body structures.

- A computer receives these reflected waves and uses them to create a picture.

How it is done:

- A clear, water-based conducting gel is applied to the skin over the area being examined to help with the transmission of the sound waves.

- A hand held transducer is then moved over the area being examined.

- Transducer sends high frequency sound waves into the body.

- The waves are reflected back by various tissues they go through.

- The reflected waves, with a help of a computer, form an image on the screen.

- Color coding of the various reflected echoes gives color images.

Example indications:

- Pregnancy evaluation.

- Echocardiography.

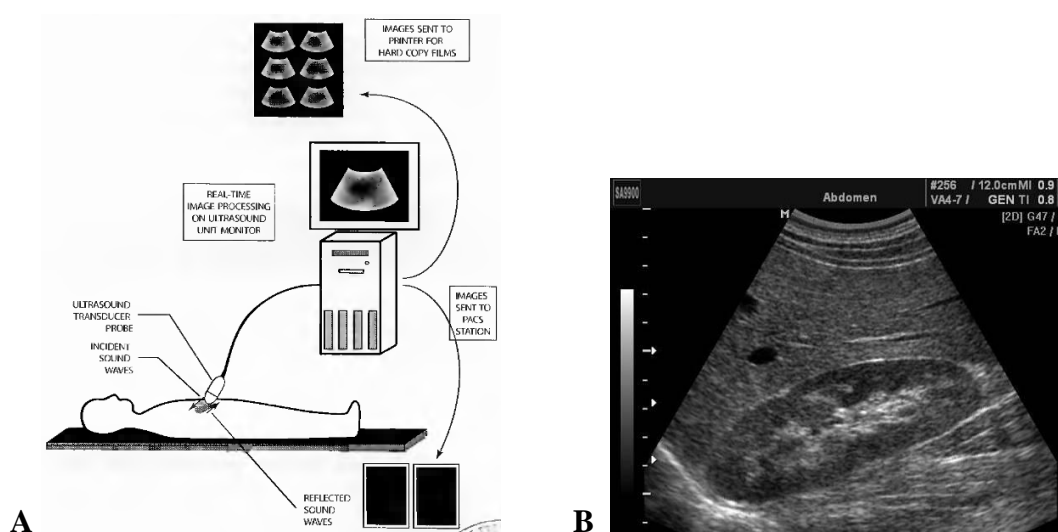


Figure 1.14 — (A) Diagram of the principle standard ultrasound system. (B) Normal sonogram of hepar and right kidney in longitudinal view (B-mode, parasagittal plane)

Advantages:

- Non-invasive test.
- Requires no preparation.
- No pain.
- Provides accurate anatomic information, including dimensions.
- No radiation risk.
- Avoiding the potential allergic and toxic complications of contrast media.
- Can be used on individuals with poor kidney function in whom contrast cannot be given.
- No complications.
- Can be done at bedside.
- Relatively economical exam.

Limitation:

- Operator dependant.
- Gas as in GI tract and lungs prevent the sound waves from passing through; therefore not useful in portions of abdomen and lungs.

Modes of sonography

Several different modes of ultrasound are used in medical imaging. Main these are:

— **A-mode:** A-mode (amplitude mode) is the simplest type of ultrasound. A single transducer scans a line through the body with the echoes plotted on screen as a function of depth. Therapeutic ultrasound aimed at a specific tumor or calculus is also A-mode, to allow for pinpoint accurate focus of the destructive wave energy. A-scan is a one-dimensional technique. The echoes received are displayed on a screen as vertical reflections. This technique is rarely used today except for measurements.

— **B-mode:** More often. In B-mode (brightness mode) ultrasound, a linear array of transducers simultaneously scans a plane through the body that can be viewed as a two-dimensional image on screen. B-scan is a technique in which the echo amplitude is depicted as dots of different brightness (gray scale). It is mostly used as a two-dimensional B-scan to form a two-dimensional ultrasound image by multiple ultrasound beams, arranged successively in one plane. The images are built up by mechanically or electronically regulated scanning in a fraction of a second.

— **M-mode:** In M-mode (motion mode, also sometimes referred to as TM-scan) ultrasound, pulses are emitted in quick succession – each time, either an A-mode or B-mode image is taken. Over time, this is analogous to recording a video in ultrasound. As the organ boundaries that produce reflections move relative to the probe, this can be used to determine the velocity of specific organ structures. M-scan is a way to display motion, e.g. of parts of the heart. The echoes produced by a stationary ultrasound beam are recorded over time, continuously.

— **Doppler mode:** This mode makes use of the Doppler effect in measuring and visualizing blood flow, moving tissues. Doppler techniques use the Doppler effect as a further source of information: if the ultrasound waves are reflected by an interface moving towards the transducer or away from it, the reflected frequency will be higher or lower respectively than the transmitted frequency. The difference between the emitted and received frequencies is proportional to the speed of the moving reflector. This phenomenon is called the Doppler effect, and the difference is called the Doppler frequency or Doppler shift. The Doppler shift depends on the ultrasonic frequency, the velocity of the reflector, and the angle between the ultrasound beam and the blood stream.

- **Continuous Doppler:** Doppler information is sampled along a line through the body, and all velocities detected at each time point is presented (on a time line). There is no information about the distance of the reflector(s), but only about the velocity, at which the reflector (the blood stream) moves.

- **Pulsed wave (PW) Doppler:** Doppler information is sampled from only a small sample volume (defined in 2D image), and presented on a timeline (figure 1.15). In this way, the movement of the reflectors in a particular distance (gate, selected by the operator) can be displayed and analyzed (spectral Doppler), or displayed in the B-scan image (duplex techniques).

- **Color-Doppler** and power-Doppler techniques are used as duplex techniques integrated in the B-scan image. The echoes arising from stationary reflectors (tissue) are displayed as bright spots (gray-scale technique). The echoes from moving reflectors are analyzed by the Doppler technique separately, but displayed in the same image «color-coded». The different colors indicate the direction of the blood flow (color-Doppler, CD). It has become common practice to represent flow towards the transducer as red and flow away as blue.

- **Power Doppler** technique (synonyms: color Doppler energy or, not as suitable, «ultrasound angiography») is based on the total integrated power of the Doppler signal. This Doppler technique is more sensitive for the detection of small vessels (that are too small to be resolved in the 2D image and that otherwise could not be studied) and slow flow and is angle-independent, but does not give information about the direction of the flow.

- **Duplex:** a common name for the simultaneous presentation of 2D and (usually) PW Doppler information. (Using modern ultrasound machines color Doppler is almost always also used, hence the alternative name **Triplex**.)

This Doppler shift falls in the audible range and is often presented audibly using stereo speakers: this produces a very distinctive, although synthetic, pulsating sound.

Spectral content (figure 1.16)

The distribution of the shades of grey in each time slot indicates the range of flow velocities present in the vessel at that time. If there is plug flow, this distribution is very narrow, whereas parabolic flow gives rise to a wider range of frequencies. The spectral broadening produced by a stenosing lesion.

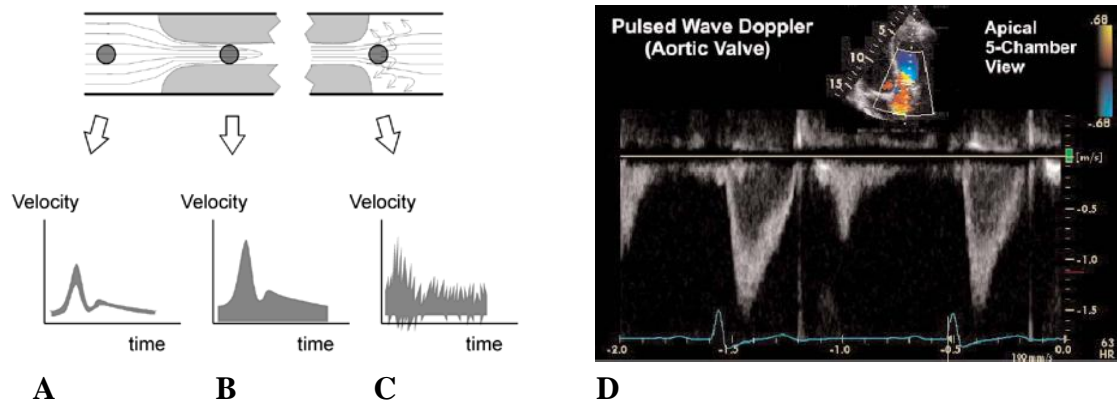


Figure 1.15 — (A to D) Images of different flow profiles. Spectral tracing shows (A-C) variants stenotic of arterial blood flow on diagrams (black circle is control volume, point registration of velocity) and (D) of aortic valve normal blood flow (triplex US complex image, B-color sector sonogram of heart at top)

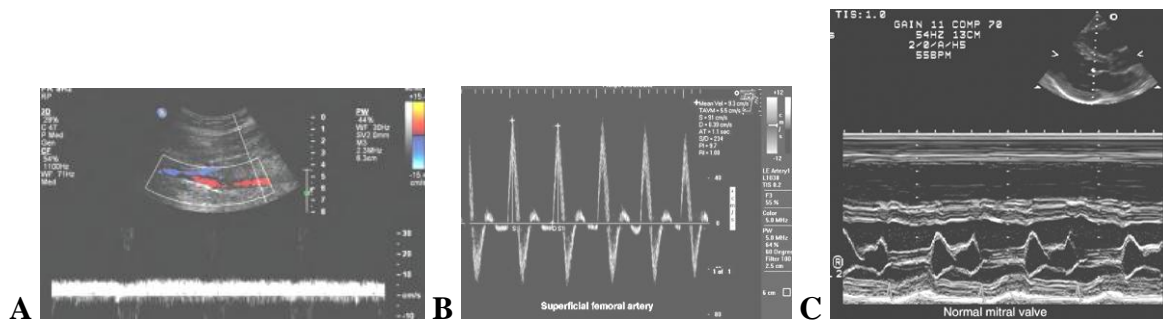


Figure 1.16 — (A) Spectral distribution in venous flow, triplex image, B-color Doppler sector sonogram of thigh at top image. Normal venous Doppler waveforms. Spectral Doppler analysis from the femoral vein demonstrates normal venous spectral signal. The slower flow in this vein gives rise to a wide range of velocities during each time interval. (B) Spectral distribution in plug flow. Pulsed Doppler display for a femoral artery with calculations displayed. A very narrow band of velocities is present throughout the cardiac cycle in this artery. In this case peak systolic and end diastolic velocities are displayed on the real-time image. (C) Duplex US of heart images complex. The insert of B-mode scan (above right of the sector image) of heart shows the orientation of the M-mode image of moved structures normal mitral valve

Contrast agents were originally developed and used to obtain a stronger signal from blood flows. So-called microbubbles, more or less stabilized encapsulated gas bubbles, somewhat smaller than erythrocytes, are used for this purpose. The use of these contrast agents considerably improves the visibility of small vessels with slow flow. However, the real advantage is the possibility to get more detailed information about the static and especially the dynamic vascularity of tissues and tumors. Special software programs and efficient equipment are necessary to use this interesting technique, including, for example, contrast harmonic imaging. With this technique the nonlinear interaction of the microbubbles with ultrasound power is used, to improve the Doppler signals. This

new technology improves the quality of ultrasound in a way similar to that seen with the tissue harmonic imaging technique used for the B-mode.

Common uses of ultrasound include evaluating the gall bladder for suspected cholecystitis, the pancreas for pancreatitis, and the right lower quadrant of the abdomen in suspected appendicitis. Other indications include evaluation of the liver, pancreas or kidneys for masses or evidence of obstruction. Ultrasound is also very helpful in the evaluation of pelvic pain in women and in suspected ectopic pregnancy, ovarian torsion, or pelvic masses. This technique is useful in cardiology, and of course, in obstetrics and endocrinology.

Finally, with the use of Doppler imaging in US, which detects flow velocity and direction, one can image blood vessels such the technique has become well-known in monitoring pregnancy, but it was also developed in other fields ranging from cardiology to oncology, as the aorta for suspected aneurysm, and the deep leg veins or portal vein for thrombosis.

Image definition has been very clearly improved, and colour, as well as animated sequences, have made their appearance. Several contrast agents, composed of air micro-bubbles trapped in biodegradable substances, have been developed. As ultrasounds are completely reflected by air, these products allow images to be taken of cavities in the same way that contrast agents are used in radiology. The resolution of traditional devices seems low, but the information obtained is sufficient for most analysis, avoiding investment in a more powerful device. The latest, top-of-the-range tools offer a resolution lower than a tenth of a millimetre and are used more particularly in eye and skin analysis.

Displaying the image, understanding the composition of the image

Images from the sonographic scanner can be displayed, captured, and broadcast through a computer using a frame grabber to capture and digitize the analog video signal. The captured signal can then be post-processed on the computer itself (figure 1.17).

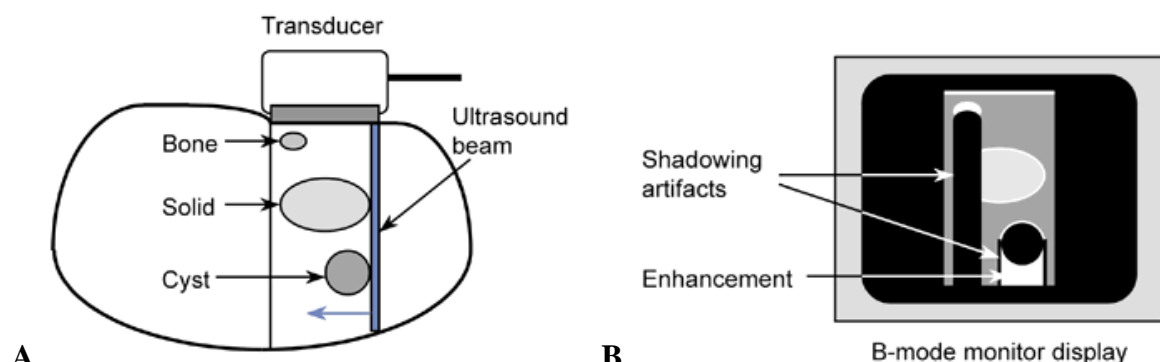


Figure 1.17 — (A to B) Schematic diagrams of displaying the US image. Typically, a cyst has few if any echoes, because it is mostly water. Tissues such as liver and spleen give a picture with rather homogeneous small echoes due to the fibrous interstitial tissue. High-intensity echoes are caused by calcification, fat, and air

Basic glossary

An anechoic structure yields (any liquid) a black image, since no echo is generated. Inversely, an echoic structure generates echoes, and will give a gray image. It can be more (closer to white) or less (closer to black) echoic.

An image defined as hypoechoic, isoechoic or hyperechoic. The approach from the anatomical structure means:

— A solid tissular mass is echoic: parenchyma, muscle, thrombosis, alveolar consolidation, or tumor (figure 1.18).

— A pure fluid mass is anechoic (with acoustic enhancement: circulating blood, vesicular bile, urine, pure fluid collections).

— A pathological fluid mass can be rich in echoes: abscess, hematoma, thick bile, necrosis, etc. If the collection contains tissular debris or bacterial gas, it can be highly heterogeneous.

— A gas structure is hyperechoic with posterior echoes of reverberation: air or microbial gas.

— Deep fat is hyperechoic such as mesenteric fat.

— An ossified structure is hyperechoic with posterior shadow: bone or calculus.

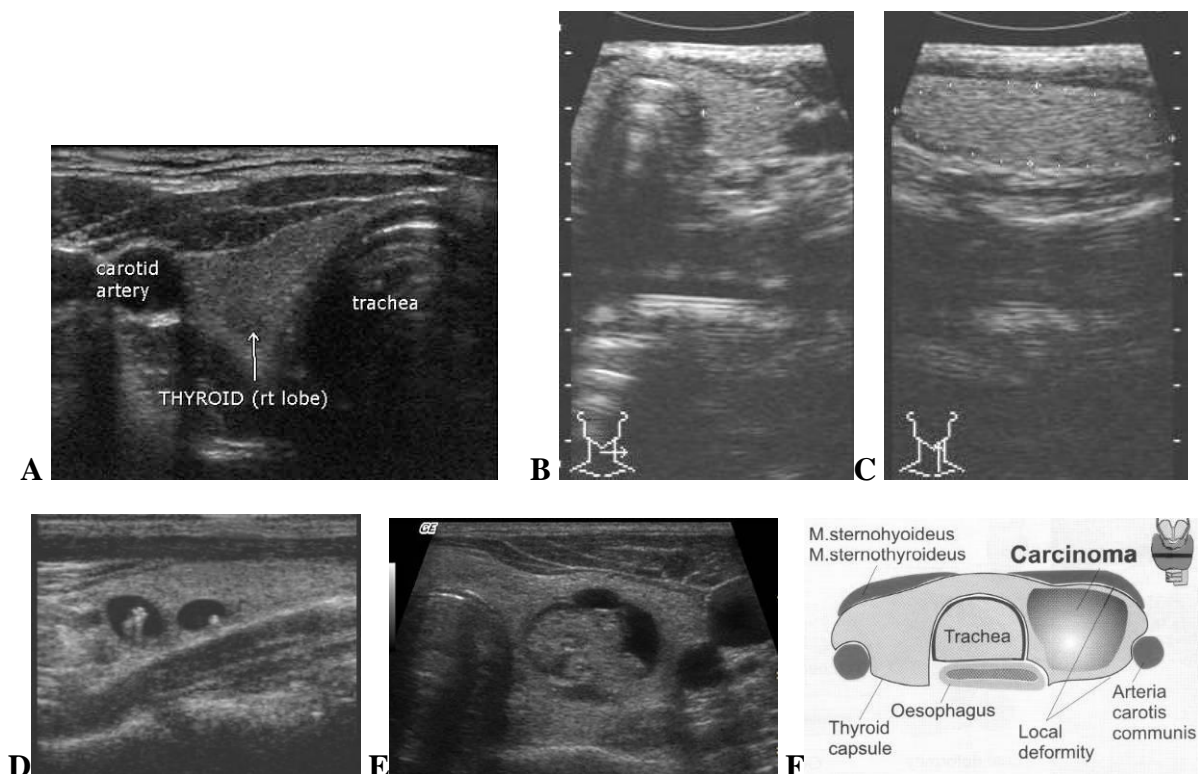


Figure 1.18 — (A, B) Transverse anterior cervical sonoscan at the thyroid isthmus. The posterior shadow of the trachea are recognized. Since an air barrier is visible immediately posterior to the anterior wall of the trachea, it can be possible to conclude that the anterior wall, at this level, is thin. (C) Longitudinal paramedian sonogram of the neck. Note marker of right lobe thyroid gland and marker of position probe (bottom). (D) Sonogram of thyroid cysts into parenchyma lobe. (E) Transverse cervical sonogram at cancer of left lobe thyroid gland and (F) diagram. All of the sonograms is result B-mode diagnostic ultrasonography

A patient who has just been subject to an ultrasound examination is, of course, not radioactive. But as with X-rays, ultrasounds can be used as a diagnosis procedure limited to anatomical imaging.

Magnetic resonance imaging

Magnetic resonance imaging does not use X-rays (or any other type of «ionizing» radiation). Instead, it is a technique that combines a large magnetic field and some radio frequency antennas («coils»). The pictures look like «sections» or «cuts» — just like in CT. Except in the MR, the resulting image primarily reflects the water protons in the patient, as well as their chemical association with proteins, etc.

Principle: first, the magnetic field causes the protons in the atoms of water within the patient to all «line-up». Then, a high-frequency electro-magnetic pulse knocks many of the protons out of alignment. Next, a very sensitive radio antenna «listens» for the «resonance» signal that each proton gives off, as it goes back into alignment. These minute resonance signals occur in a pattern that a computer uses to create 3D information. By using gradients in different directions 2D images or 3D volumes can be obtained in any arbitrary orientation.

Advantages:

- No ionizing radiation.
- Multi planar imaging.
- High contrast resolution between the different soft tissues of the body, which makes it especially useful in imaging the brain, muscles, the heart, and cancers compared with other medical imaging techniques.

Non-invasive vascular imaging.

Disadvantages:

- Have been artifacts due to patient motion.
- The inability to bring ferrous objects near the magnet.
- Cost.
- MRI is less sensitive than CT in the detection of small amounts of calcification and in the detection of acute haemorrhage (brain).

MRI utilizes the physical principle that hydrogen protons will align when placed within a strong magnetic field. The patient's tissues will generate different signals for the final MR image, depending on relative hydrogen proton composition. MRI generally provides better anatomic detail of soft tissues than CT.

The major safety problem with these magnets is that they are so strong that if bring a ferromagnetic object (such as a wrench) into the room, it can accelerate to 150 miles per hour as it is ripped out of hand and flies into the bore of the magnet. If a patient is in the machine at the time, lethal consequences will result.

In their natural state, hydrogen atoms are spinning with their axes of rotation randomly oriented. When placed in a magnetic field, they align in a uniform direction. An RF pulse is applied, knocking the H-atoms out of their magnetic fi-

eld orientation. Once the RF pulse is stopped, the atoms return to their previous alignment, giving off a signal which is then used to form the image (figure 1.19).

Subject to a magnetic field of a defined intensity, the nuclei of certain atoms, themselves being able to be considered as mini-magnets, align themselves to this field. By subjecting these atoms to a wave of very short radio frequency and specific to this atom, one of their parameters can be changed, their direction of rotation or spin. They enter into resonance with this wave, that is to say, they start to vibrate at the same frequency. When this external radiofrequency is switched off, their return to a normal state is expressed by the restitution of this energy in the form of a signal which can be captured and measured. The origin of the signal can be found practically atom by atom as these are located in space. In organic tissue, hydrogen is the most common atom with this property.

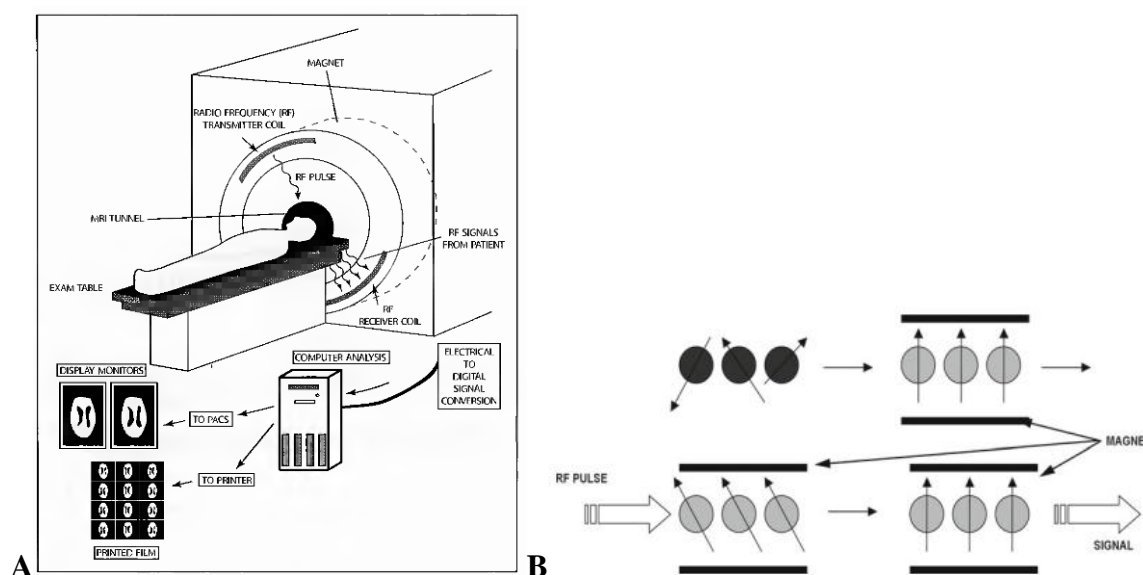


Figure 1.19 — (A) Diagram of the standard magnetic resonance imaging (MRI) and production of MR images. (B) The basic principles behind MRI. In their natural state, hydrogen atoms are spinning with their axes of rotation randomly oriented. When placed in a magnetic field, they align in a uniform direction. An RF pulse is applied, knocking the H-atoms out of their magnetic field orientation. Once the RF pulse is stopped, the atoms return to their previous alignment, giving off a signal which is then used to form the image

Hydrogen is also the majority atom in human tissue because it is the main element in water and fats, matter making up almost nine tenths of our body weight. Therefore, three-dimensional displays of the body density of water, fats and other organic matter containing hydrogen can be obtained with MRI (figure 1.20). As this density differs from one organ to another, it is easy to obtain the outline of these elements with precision to within a few millimetres. Much more powerful tools are being developed that will give a resolution of under a millimetre.

As the technique is still costly, it is preferable to use traditional radiological methods to display a broken arm, and the result is just as convincing. Hydrogen

is by far not the only element that could be used in MRI, but the density of its atoms remains the greatest.

Functional analysis is possible in some very specific cases, like brain irrigation or heart functioning monitoring, via live analysis of the rate of oxygen contained in the blood.

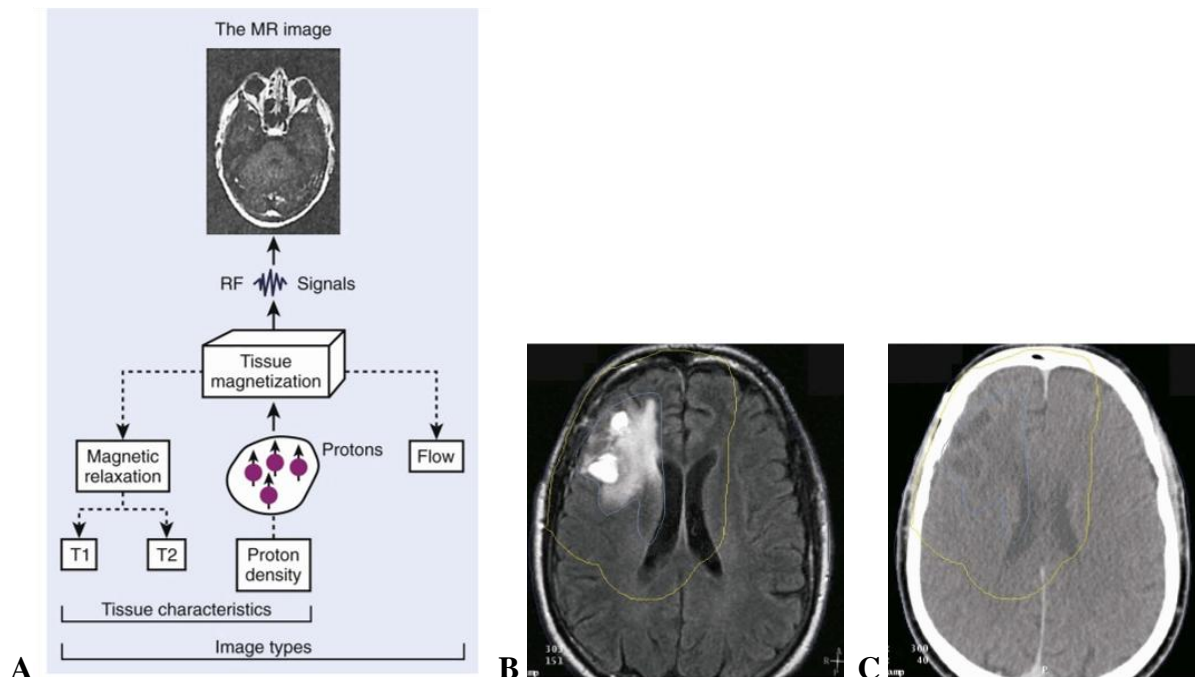


Figure 1.20 — (A) Physical characteristics of tissue that are displayed in the magnetic resonance image. MR, Magnetic resonance; RF, radiofrequency; T1, spin-lattice relaxation time; T2, spin-spin relaxation time. (B) Axial T1 magnetic resonance image of the head and brain. Malignant tissue appears as brighter areas in the upper left. (C) Axial computed image of the same patient (for comparison)

If MRI was not as expensive and was more widely available, it would easily replace most of the techniques described above. For the time being, it is kept for examinations for which diagnosis seems more difficult (soft tissue such as muscles, tendons, brain, tumours) or in indications for which this method is much more effective or unique (neurology, ophthalmology, cardiovascular, endocrinology, oncology, etc.)

A patient that has just undergone an MRI examination is no more radioactive than a patient that has received ultrasounds, or are they magnetised or magnetic. But as with X-rays and ultrasound, for the moment MRI can only be used as a diagnosis procedure limited to anatomical imaging.

Three-dimensional reconstruction in radiology

The majority of work performed in radiology is presented as 2-D information, from conventional x-ray images to the most advanced CT, MRI or PET-CT

studies. When axial imaging began with CT and US, imaging information became available in digital form. The next step was to try and obtain volumetric information from the 2-D slices. Reconstruction uses the 3-D data to show other planes that were not acquired directly during the acquisition, including sagittal and coronal cross-sections reconstructed from the axial images.

Two methods for 3-D reconstruction are available *in radiology*; the first is 3-D Surface Shaded Display (3-DSSD) that recognizes tissue by its density (similar to CT) or manually by drawing the contour of the organ. The view is as though one is looking from a certain point and what surface the viewer can see. This method actually shows only the surface of the organs as an opaque object. A virtual light source is computed for each polygon and the object is displayed with the resulting surface shading.

Secondary method for 3-D reconstruction is volume rendering reconstruction (VR) — takes the entire volume of data, calculates the contributions of each voxel (volume pixel) along a line from the viewer's eye through the data set, and displays the resulting composite for each pixel of the display. Opacity values range from 0, which is totally transparent, to 1, which is totally opaque. So surfaces are displayed by mapping the corresponding data values to almost opaque values and the remainder to transparent values.

It is possible for a software program to build a volume by «stacking» the individual slices one on top of the other. The program may then display the volume in an alternative manner. A big advantage of volume rendering is that this interior information is not discarded, so that it enables one to look at the 3-D data set as a whole.

Multiplanar reconstruction is the simplest method of reconstruction. A volume is built by stacking the axial slices. The software then cuts slices through the volume in a different plane (usually orthogonal). Modern software allows reconstruction in non-orthogonal (oblique) planes so that the optimal plane can be chosen to display an anatomical structure. This may be particularly useful for visualising the structure of the bronchi as these do not lie orthogonal to the direction of the scan.

Unlike other reconstruction techniques, CT and MRI perfusion use time as the third dimension. Acquisition is performed on a set of slices without contrast material. Then, at known intervals after the injection of contrast material, changes in the tissue enhancement over time are followed. The results are displayed as color maps which include blood volume in the region of interest, blood flow and time of travel of the blood through the region of interest.

Post-processing 3-D application used with MRI, CT, US and NM studies. When the two sets are aligned, it is possible to fuse them into one image.

Reconstructed 3-D data offers several advantages:

1. It enhances viewing of pathology.
2. It to more easily compare current and previous exams.
3. It improves service to referring physicians, since selected 3-D images can be attached to the radiology report. These images illustrate the diagnosis and

may even be shown to patients while discussing the condition and recommended treatment.

Contrast radiologic examinations

At the same time, contrast agents used in radiology have made considerable progress, adding to the quality and resolution of the images. As soon as it was understood that the density of the matter crossed by the ray was linked to the opacity of the image, it was also understood that a specific image could be taken of irrigated regions, as long as a contrast liquid could be injected into them. A contrast medium that was neutral, therefore non-toxic, and which could be eliminated rapidly still needed to be found.

Table 1.1 — Radiographic contrast agents at practice

<i>Groups of medias</i>	<i>Chemical variant and solubility</i>	<i>Contrast agents</i>	<i>Usage</i>
Radiopositive medias (on X-ray image look like shadow)	Salts of heavy metals, unsoluble	Barium sulphate	Gastrointestinal organs (as a barium meal or barium enemas)
	Organic iodide preparations, water soluble, ionic	Urographin, uerographin, bilitrast, bilignost and so on	Normal and pathologic cavities, fistulas, to use intravenously or to arteries
	Organic iodide preparations, water soluble, non-ionic	Omnipaque, ultravist	Vessels, normal and pathologic cavities, fistulas, various ducts
	Organic iodide preparations, fat-soluble (iodinated oils)	Iodolipolum, lipiodolum	Bronchography, lymphography
Radionegative medias (on X-ray image look like enlightenment)		Gas (air)	Different normal cavities and spaces (pneumogastrography, pneumoencephalography, pneumomediastinum and so on)

Contrast agents, often based on iodine or barium, have now become unavoidable, as they give an extremely precise display of certain anatomic details such as very small vessels for example (table 1.1).

Radiography is adequate for situations in which natural radiographic contrast exists between body structures, such as the heart and lungs, or between the bones and adjacent soft tissues. To examine structures that do not have inherent contrast differences from the surrounding tissues, it is necessary to use one of several contrast agents. Three areas deserve specific mention: gastrointestinal tract, urinary tract, and blood vessels.

Radiographic contrast agents

Various structures within the body are recognizable on imaging studies either because of their inherent densities (e.g., bone distinguished from muscle) or because they contain one of the basic natural materials (e.g., air). However, because most of the internal viscera are of the radiographic density of water or close to it, it is necessary to introduce into these structures a material that will outline walls, define anatomy, and demonstrate any pathologic conditions.

X-ray contrast medium is an exogenous substance used to alter the contrast in X-ray imaging by affecting the attenuation of X-rays. Introducing of gases into hollow viscera, cavities will reduce the attenuation of X-rays; such substances are called negative contrast media. The vast majority of X-ray contrast media are positive or radiopaque, for they increase the attenuation of X-rays. The increased attenuation is accomplished by two different atoms: barium, which is used in the form of insoluble barium sulphate for examinations of the gastrointestinal tract, and Iodine, which is the main component of all other X-ray contrast media.

Barium preparations

Barium sulfate (water-suspension), in one of its many forms, provides the mainstay for radiographic examinations of the gastrointestinal tract. Barium is of high atomic weight, which results in considerable absorption of the x-ray beam, thus providing excellent radiographic contrast. In the usual preparation, finely pulverized barium mixed with dispersing agents is suspended in water. When administered orally or rectally, it provides excellent coating and distention of the GI tract.

Water-soluble contrast media

Water-soluble contrast agents can be categorized based on their osmolality: high-osmolality contrast media, iso-osmolality contrast media, and low-osmolality contrast media, which have different biochemical profiles and prices.

Water-soluble contrast agents can be injected directly or indirectly into the body to provide contrast enhancement. After the contrast has had time to pass through the body (30 to 60 seconds), contrast-enhanced images can be taken with excellent resolution of soft tissue organ and vascular detail.

Water-soluble contrast can also be injected into various body parts with subsequent diagnostic imaging, including the blood vessels (angiography), the spinal canal (myelography), and joints (arthrography). Water-soluble contrast can also be injected into the GI and into the genitourinary tract (cystogram, nephrogram, hysterosalpingogram, etc.) for detailed radiology evaluation.

CT with contrast

Sometimes the patient may feel hot as a result, but usually this is the only reaction they have. Rarely, the patient comes out in a rash after receiving the contrast, and patients who are asthmatic or have a history of previous reaction to contrast need to be made known to the imaging department before they attend.

The request form will have a section for you to complete in such cases, and the risks will be explained to the patient by the radiologist.

Example indications: pulmonary embolism, aortic dissection, aneurysm.

Limitation: contrast sensitivity, renal failure.

Arteriography

Principle: arteriography is a procedure in which a contrast material is injected into an artery to evaluate the vasculature.

How it is done:

— contrast material is injected into the blood vessel and x-rays are taken.

Example indications:

— cerebral angiography: aneurysms, tumors;

— renal angiography: renovascular hypertension;

— pulmonary angiography: pulmonary embolism.

Advantages:

— arteriograms give the best pictures of the arteries;

— arteriograms are used to make specific diagnoses.

Limitation:

— invasive procedure;

— bleeding and injury to the artery;

— contrast complications.

Adverse reactions of contrast examinations

Extravasation

Contrast does not always end up in the intended location. For example, when a patient is injected with intravenous contrast for a CT examination, it is possible for that agent to extravasate into the subcutaneous tissues of the arm. This can be a painful condition, which can lead to morbidity with skin necrosis if not treated correctly.

Allergic reaction

Although normal persons may not suffer any severe, long-lasting effects from the administration of contrast, one must remember that contrast, like any drug or medication, can result in an allergic reaction which can potentially result in death. Depending on the severity of the allergy, the patient can be premedicated with a combination of steroids and diphenhydramine before receiving the intravenous contrast.

Contrast-induced nephropathy

Excretion of these intravenous agents is largely performed by glomerular filtration within the kidney. In the kidneys, especially in a dehydrated patient and patients with borderline renal function (including diabetics), glomerular and

tubular damage may result in temporary impairment of renal function and oliguria, which has been labeled contrast-induced nephropathy. In patients with poor renal function contrast is contraindicated and the radiologist needs to discuss the case with the referring physician and the patient.

With the intravenously or intra-arterially administered agents, a small but real risk of contrast reaction exists. This is something that you should consider before ordering an intravenous pyelogram or a contrast-enhanced CT scan. About 5% of patients will experience an immediate mild reaction, such as a metallic taste or a feeling of warmth; some experience nausea and vomiting, wheeze, or get hives as a result of these contrast agents. Some of these mild reactions can be treated with 50 mg of intramuscular diphenhydramine (Benadryl). Because contrast agents also can reduce renal function, they should not generally be used in patients with compromised renal function.

A small number (about 1 in 1000) patients have a severe reaction to intravascular contrast. This may be a vasovagal reaction, laryngeal edema, severe hypotension, an anaphylactic-type reaction, or cardiac arrest. A vasovagal reaction can be treated with 0.5 to 1.0 mg of intravenous atropine. The most important initial therapeutic measures in these severe reactions are to establish an airway, ensure breathing and circulation, and give intravenous fluids. Other drugs obviously also may be necessary. The risk of death from a study using intravenously administered contrast agents is between 1 in 40,000 and 1 in 100,000.

Interventional radiology

New, minimally invasive surgical procedures are emerging which can be performed on an outpatient basis together with the diagnostic imaging procedure, for instance CT, MR or ultrasound. By combining delivery of therapy with the diagnostic procedure, the healthcare system can realise significant savings.

Like angiography, interventional radiology is not a distinct imaging modality, but it too plays a major role in contemporary medical and surgical therapeutics. Interventional radiology involves the use of various imaging modalities, including fluoroscopy, CT, ultrasound, and even MRI, in conjunction with equipment such as wires, catheters, needles, and endoluminal stents, to perform a variety of therapeutic procedures that were formerly either impossible or required more laborious, hazardous, and costly techniques. It should be noted that angiography and interventional radiology are closely related fields, and both are often practiced by the same subspecialists. To develop a general sense of what interventional radiology does, let us briefly review one very common interventional procedure, percutaneous abscess drainage (using CT, US, fluoroscopy).

Other interventional radiology procedures and activities include but are not limited to the following:

1. Intraoperative cases (e.g., thoracic and abdominal aortic stent grafts).
2. Noninvasive cardiac and vascular imaging.
3. Percutaneous oncologic interventions.
4. Percutaneous biopsies (using CT, ultrasound, and/or fluoroscopy).

Multi-modality radiology and molecular imaging

Molecular imaging is defined as the ability to visualize and quantitatively measure the function of biological and cellular processes in vivo. Molecular imaging can be applied to all avenues of medical imaging: early detection/screening, diagnosis, therapy delivery/monitoring, and treatment follow-up. The current status of clinical molecular imaging is limited, with most current applications using positron-emission tomography (PET) and single photon-emission computed tomography (SPECT) imaging, and less for MRI and US.

Contrast-enhanced molecular ultrasound with molecularly-targeted contrast agent microbubbles is explored as a clinically translatable molecular imaging strategy for screening, diagnosing, and monitoring diseases at the molecular level. Doxorubicin, to a superparamagnetic iron oxide nanoparticle, which is then encapsulated in liposomes, attach to tumour angiogenic vessels, and the localization of these magnetic particles can be visualized using MRI.

The main advantage of in vivo molecular imaging is its ability to characterize diseased tissues without invasive biopsies or surgical procedures.

The development of combined imaging SPECT-CT and PET-CT systems allows the superimposition of nuclear medicine and CT images, a technique known as functional–anatomical mapping. Technical and clinical advances in medicine have led to the understanding that one modality cannot be a substitute for the other; they are complementary to each other. The combined PET/CT is more sensitive and specific for detecting otherwise occult malignancy, tumor staging, and detecting disease recurrence and/or metastasis.

An approach to image interpretation

Typically, one expects to find the exact location of a problem and hopes to make the diagnosis. Although some diseases present a very characteristic picture, most can appear in a variety of forms depending on the stage. As a result, image interpretation will yield a differential diagnosis that must be placed in the context of the clinical findings.

Examination of images requires a logical approach. First you must understand the type of image, the orientation, and the limitations of the technique used. For example, you begin by mentally stating, “I am looking at a coronal computed tomography scan of the head done with intravenous contrast.” This is important, because intravenous contrast can be confused with fresh blood in the brain.

Next, look at the name and age on the film label to avoid mixing up patients, and it allows making a differential diagnosis that applies to a patient of that age and sex. You would not believe the number of times that this seemingly minor step will keep you from making very dumb mistakes.

The next step is to determine the abnormal findings on the image. This means that you need to know the normal anatomy and variants of that particular part of the body as well as their appearance on the imaging technique used. After this, you should describe the abnormal areas, because it will help you mentally to order a differential diagnosis. The most common mistake is to look at an abnormal image and immediately to name a disease. When you do this, you will find your mind locked on that diagnosis (often the wrong one). It is better to say to yourself something like, «I am going to give a differential diagnosis of generalized cardiac enlargement with normal pulmonary vasculature in a 40-year-old male», rather than to blurt out «viral cardiomyopathy» in a patient who really has a malignant pericardial effusion.

After reviewing the common causes of the x-ray findings that you have observed, you should reorder the etiologies in light of the clinical findings. At this point, you probably think that you are finished. Not so. Often a plethora of information is contained in the patient's film jacket or in the hospital computer information system. This comes in the form of previous findings and histories supplied for the patient's other imaging examinations. Reviewing the old reports has directed us to areas of pathology on the current film.

You probably think that you are finished now. Wrong again. A certain number of entities could cause the findings on the image, but you just have not thought of them all. After radiologists have finished looking at a case, they try to go through a set sequence of categories in search of other differential possibilities. The categories they use are congenital, physical/chemical, infectious, neoplastic, metabolic, circulatory, and miscellaneous.

Protection in radiological practice

The benefit of using ionizing radiation in medicine is widely acknowledged. Although alternative methods of imaging — for example, ultrasound and magnetic resonance imaging — have been developed, ionizing radiation will continue to be used for the foreseeable future. However, it is recognized that ionizing radiation can cause harm and it is therefore important that the users of radiation are aware not only of the clinical benefits, but also of the possible risks to their patients and themselves and the legislation that is in place to control the risks.

Soon after the discovery of X-rays and radioactivity, it became evident that radiation could cause somatic damage to tissues (e.g. erythema), but it was not for some years that the long-term and genetic effects began to be appreciated. Current knowledge of risks of ionizing radiation is based on a wide range of epidemiological evidence from animal and cell biology.

Epidemiological analysis gives a derived risk of radiation-induced fatal cancer of 5% per sievert for the general population (table 2.2). For children and young people the risk is assumed to be two or three times this value, whereas for those over the age of 60 the risk is about a factor of five less, due to limited time for expression of the detriment. Risk factors have also been estimated for nonfatal cancers and hereditary effects in both the workforce and the general population.

Aims and principles of radiation protection are:

- to prevent deterministic effects
- to limit the probability of stochastic effects by keeping all justifiable exposure as low as is reasonably achievable (ALARA principle): this includes keeping as low as possible doses to individuals, the number of people exposed, and the likelihood of others being exposed.

Table 2.2 — Common imaging examinations, their cost, radiation dosage, risk of fatal cancer and equivalent to number of cigarettes smoked

Examination	Cost ⁻¹ (\$) (in Europe)	Dose (mR)	Risk of fatal cancer (per million)	Equivalent to number of cigarettes smoked
Chest (PA, Lateral)	130	100	1.6	12
Abdomen (supine, upright)	130	1500	48.0	350
Wrist	110	4	—	—
Lumbar (5 view)	200	900	85.0	615
Mammogram	200	300	4.0	29
Barium enema	300	5000	350.0	2540
Intravenous urogram	330	600/image	170.0	1225
Abdominal aortoiliac angiogram	1500	150 /image	—	—
Cranial CT	700	4500	72.0	525
Chest CT	800	1500	300.0	2280
Abdominal CT	830	3500	300.0	2220
Abdominal ultrasound	500	0	0	—
Pelvic obstetric US	550	0	0	—
Cranial MR	1200	0	0	—
Pelvic MR	1200	0	0	—
Bone scan (radionuclide)	300	1000-bone, 300-whole body	—	—
Lung scan (radionuclide)	300	1000-lung, 60-whole body	—	—

Distance

The intensity of X-radiation decreases with the square of the distance from a point source and applies at distances greater than 1 m from an irradiated pa-

tient or a patient containing radionuclide. Application of the use of distance is seen in the following practices:

- making as full a use as practicable of the length of the exposure cable in fluoroscopy or mobile radiography;
- ensuring adequate distance between patients when they are radiographed;
- stepping back when carrying out image acquisition in a fluoroscopy act;
- using remote handling tools to maximize the distance of the hands from a radioactive source;
- arranging the nuclear medicine waiting area so that injected patients do not have to wait in close proximity to reception staff or visitors;
- ensuring nuclear medicine patients returning home are given instructions if they should avoid close contact with others for a period of time.

Time

The amount of radiation received is directly proportional to the length of the exposure time and so may be minimized by conducting procedures as quickly as possible. Application of the use of time to minimize dose is seen in:

- the use of as fast imaging systems as practicable to reduce exposure times;
- the use of image storage facilities and last image hold;
- training, including the use of simulators to practise technique, so that the procedure can be done as quickly as possible in the patient;
- practising radioactive manipulations with an inactive material.

Shielding

Positioning of a barrier between the source of radiation and the recipient will reduce the dose by an amount dependent on the energy of the radiation source and the nature and thickness of the barrier. It is most effective to place barriers as close to the radiation source as practicable. The use of shielding is seen at all levels — from the design of an X-ray room and provision of protective clothing, down to syringe shields used in nuclear medicine.

In undercouch fluoroscopy, the X-ray tube is located beneath the table, while the intensifier is mounted above. Most of the scattered radiation is in the downward direction (with the table horizontal) and is absorbed in the floor or the protection side-panels of the table.

Staff working close to the patient during fluoroscopic procedures should wear personal protection consisting of lead-equivalent aprons. Aprons of 0.3mm lead equivalent attenuate the radiation by a factor of about 10, depending on thickness and the kVp and provide a reasonable compromise between weight and attenuation. Lead gloves should be worn if the hands are near the X-ray beam.

Dose monitoring

There is a legal requirement for radiation doses to be monitored. This is normally done by film or thermoluminescent dosimeter badges to assess whole body dose. The badge should be positioned at waist level under the lead apron if one is worn. In addition, if there is potential for the eyes, hands, feet to be irradiated significantly, additional dosimeters should be worn to assess these doses.

Protection of patient

Each exposure justified on a case-by-case basis. Minimize number of X-ray films taken and minimize screening time. Only trained personnel to operate equipment. Good equipment to be used including rare earth screens, adequate filtration of X-ray beams, etc. Use ultrasound or MRI where possible. Quality assurance programmes in each department, including correct installation, calibration and regular testing equipment.

Protection of staff (including medical students)

Only necessary staff to be present in a room where X-ray procedures are being performed: TV monitors placed outside the screening room usually mean that students may observe procedures at a safe distance. Staff to wear protective clothing (e.g. lead aprons). At no time should staff be directly irradiated by the primary beam: lead gloves must be worn if the hands may be irradiated (e.g. in immobilizing patients or performing stress views). All X-ray rooms should have lead lining in their walls, ceilings and floors.

There is no threshold for stochastic effects so any imaging procedure or therapy that involves the use of radiation involves some risk. When performed properly, the risk is usually very small and is far outweighed by the medical benefit of having the procedure. Regardless, the concept of ALARA (keeping the radiation dose As Low As Reasonably Achievable should always be employed to minimize the risk).

Radiation therapy and interventional fluoroscopy procedures may result in radiation doses that exceed the threshold dose for skin injuries, and less frequently for cataract induction. The procedures performed in these areas are often life-saving and every effort to minimize the magnitude of these effects is taken.

2. RADIOLOGY OF MUSCULOSKELETAL SYSTEM

Introduction

The human skeleton contains 206 bones. All of these bones can be classified into five groups based on shape. Below are the definitions and a few examples of the five bone classifications.

— Long bones — bones of the extremities that have a length greater than the width (e.g., femur).

— Short bones — bones of the wrist, ankle and foot that are cuboidal in shape (e.g., carpals and tarsals).

— Flat bones — diploic bones of the vault of the skull (e.g., parietal and frontal) and the iliac bone.

— Sesamoid bones — small, rounded bones located in tendons.

— Irregular bones — bones have irregular shapes (e.g., vertebrae, coccyx).

The process of reading a bone radiograph should be an active one, looking at cortical margins and bone alignment and looking for typical fracture patterns. Therefore, the habit of looking for abnormalities is more valuable than a passive look at the x-ray. Review the parts of a long bone in a child with the open epiphyses. In an adult, the epiphyses would either be closed and evidenced by a sclerotic scar. Soft tissue abnormalities are valuable indirect signs of injury.

Examination techniques of musculoskeletal system

Routine radiography

Today, routine radiography continues to be the most appropriate screening technique for musculoskeletal disorders. Appropriate evaluation of routine radiographs results in diagnosis or selection of the next most appropriate imaging procedure.

Multiple views are required for minimal evaluation of osseous and articular anatomy. Specific views will be discussed in subsequent anatomic chapters. In some cases, fluoroscopically positioned spot views are useful to optimize positioning and reduce bony overlap. This approach is especially useful in the foot and wrist. This technique also is appropriate to evaluate interfaces of arthroplasties and metal fixation devices. Fluoroscopic positioning is particularly useful in the shoulder and knee.

Computed tomography

CT is a fast and efficacious technique for evaluating the musculoskeletal system. The basic components of the system are a gantry, which houses a rotating x-ray tube and radiation detectors, and a movable patient table. The output of the radiation detectors is manipulated by a computer to produce the images. The table is moved in increments to obtain axial images with conventional scanners. Spiral (helical) scanners move the patient continuously as the tube and detectors rotate, resulting in a spiral volumetric data set. Skeletal imaging typically is performed using sections 3 to 5 mm thick, but thinner sections are used for fine detail, if reformatting, or if three-dimensional reconstruction is required.

CT is particularly suited for evaluating complex skeletal anatomy in the spine, shoulder, pelvis, foot, ankle, hand, and wrist. Thin-section images allow reformatting in multiple planes. This provides excellent osseous and articular detail. CT characterize complex fractures (pelvis, ankles, hips). Precontrast and postcontrast images (intravenous iodinated contrast) are useful for evaluation of soft tissue lesions. CT is useful for evaluating numerous musculoskeletal disorders, including neoplasms, arthropathies, and subtle or complex fractures.

Magnetic resonance imaging

MRI is a proven technique with expanding musculoskeletal applications. Most imaging is performed at 1.5 Tesla; however, 3T imaging is more common today, and there are multiple open bore units and extremity units available at lower field strengths for musculoskeletal imaging. Before considering MRI as an imaging technique, one must consider certain screening issues and patient safety factors. We prefer to use a written questionnaire with specific easily answered questions to improve detection of patients who may be at risk for MRI. Obvious risk factors, such as cardiac pacemakers, cerebral aneurysm clips, metallic foreign bodies, and electronic devices, which may place the patient at risk, can be detected using the questionnaire and by verbal clarification of questions from patients. When metallic foreign bodies are suspected, radiographs or CT should be obtained for confirmation.

Metallic implants may create artifacts that significantly degrade image quality, especially if the implants contain ferromagnetic impurities. Fortunately, most orthopedic implants, except screws, cause minimal local distortion. The extent of image degradation depends on the size and configuration of the implant. Cast material do not create significant image artifacts.

Ultrasound

Musculoskeletal applications for ultrasound have expanded considerably in recent years. The joints, soft tissues, and vascular structures are particularly suited to ultrasound examination. Evaluation of cortical and trabecular bone now is feasible and per-

mits examination of the calcaneus for osteoporosis. Because of its low cost and availability, ultrasound now is being used more frequently to evaluate various conditions.

Bone scan (osteoscintigraphy) is inexpensive, very sensitive for detecting occult fractures.

Normal developmental anatomy

A thorough understanding of normal developmental anatomy is essential for accurate interpretation of radiographs of the pediatric wrist and hand (figure 2.1). Table 2.1. outlines the age of appearance and fusion of the primary and secondary ossification centers.

Table 2.1 — Wrist and hand: approximate age of appearance and fusion of ossification centers

<i>Ossification center</i>	<i>Primary (P) or Secondary (S)</i>	<i>No. of centers age of appearance</i>	<i>Age of appearance</i>	<i>Age of fu- sion (years)</i>
Wrist				
Capitate	P	1	Birth to 6 months	
Hamate	P	1	Birth to 6 months	
Triquetrum	P	1	1–3.5 years	
Lunate	P	1	1.5–4.5 years	
Navicular	P	1	3–9 years	
Trapezium	P	1	3–9 years	
Trapezoid	P	1	3–9 years	
Pisiform	P	1	7–13 years	
Distal radial epiphysis	S	1	6–24 months	20–25
Distal ulnar epiphysis	S	1	5.5–9.5 years	19–25
Hand				
Metacarpal heads	S	4	10–24 months	14–21
Metacarpal base (first)	S	1	1–3.5 years	14–21
Phalangeal bases	S	4	1–2.5 years	14–21
Phalangeal bases (first)	S	1	1–2.5 years	14–21

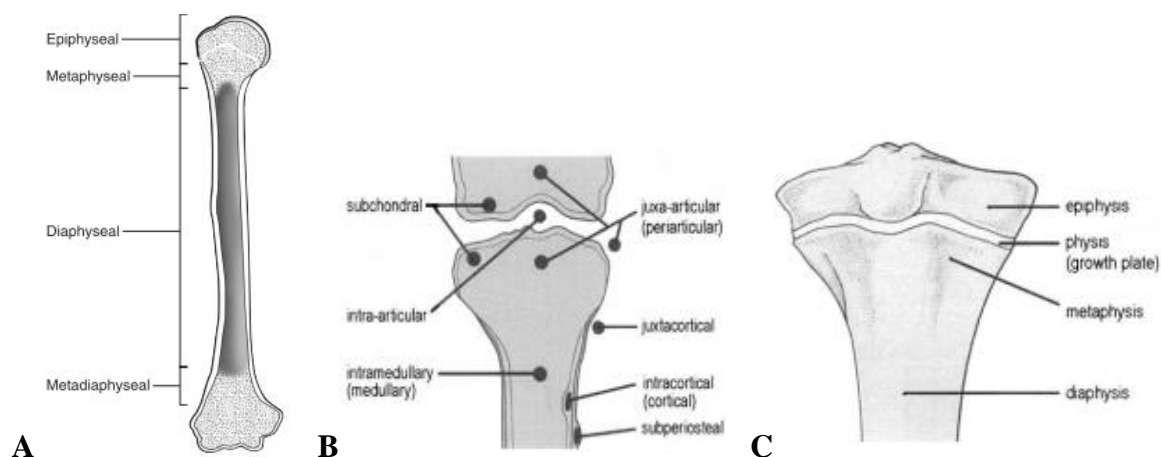


Figure 2.1 — (A) The principal parts of a long bone, in this case the femur. (B) Terminology

used to describe the different portions of a long bone. Terminology used to identify the location of a lesion in the long bone of the growing skeleton. (C) At maturity (post-skeletal fusion) the physis (growth plate) fuses and is no longer visible

Both the chronologic age and skeletal age are listed for each of these examples. These radiographs show the radiographic appearance of many important ossification centers and other developmental landmarks from infancy through adolescence (figure 2.2). For precise assessment of skeletal age, the Greulich and Pyle atlas or similar publications should be consulted.

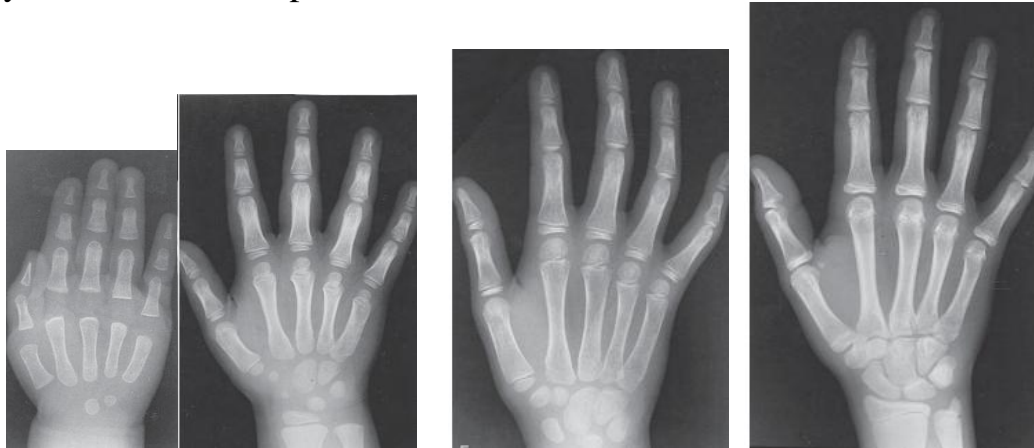


Figure 2.2 — Skeletal maturation and normal development: posteroanterior radiographs of the hand and wrist. (A) Male; CA = 13 mo; (D) Female; CA = 4 yr; SA = 4 yr.

(E) Male; CA = 7 yr; SA = 7 yr. (K) Female; CA = 15 yr; SA = 13 yr.

CA, Chronologic age in months (mo) or years (yr); SA, estimated skeletal age in months (mo) or years (yr). Note: These radiographs were randomly selected from teaching files from a variety of sources to demonstrate only general trends in osseous development

X-ray diagnostics of skeletal traumatic lesions

The easiest way of showing a fracture in a bone is using conventional x-rays. Fracture is a broken bone. Fractures can be classified according to the type and complexity of the break, the location of the break, and certain other special features.

Classification of fractures

1. Direct signs:
 - line (plane) of fracture;
 - displacement of bone's fragments.
2. Indirect signs:
 - enlargement of volume of soft tissues (because of an edema and hematoma);
 - step-shaped deformation of cortical layer;
 - breakage of cortical layer.
3. Complete, incomplete and comminuted.

At complete fracture the line of fracture intercrosse both cortical layers of a bone; the rift intercrosse one cortical layer and disappears inside a bone. The bone breaks completely into pieces.

Incomplete (partial): the bone does not break completely into two or more pieces. Comminuted: a fracture that results in more than two fracture fragments.

4. Localization:

- epiphyseal;
- metaphyseal;
- diaphyseal;
- apophyseal.

5. Direction of a line of fracture:

- transverse fracture;
- Longitudinal fracture;
- oblique fracture;
- t-shaped fracture;
- v-shaped fracture;
- impacted fracture: the bone is broken when one part is forcefully driven into another.

6. Traumatic and pathologic.

7. Intraarticular and extraarticular.

8. Apophyseolysis.

9. With and without displacement of fragments.

Fracture definition: a complete or incomplete break in the continuity of bone or cartilage (figure 2.3). Here are the definitions for the fracture patterns:

— Simple transverse fracture — a fracture in which the fracture line is perpendicular to the long axis of the bone and that results in two fracture fragments.

— Spiral fracture — a severe form of oblique fracture in which the fracture plane rotates along the long axis of the bone. These fractures occur secondary to rotational force.

— Avulsion fracture — a fracture in which the tendon is pulled away from the bone, carrying a bone fragment with it.

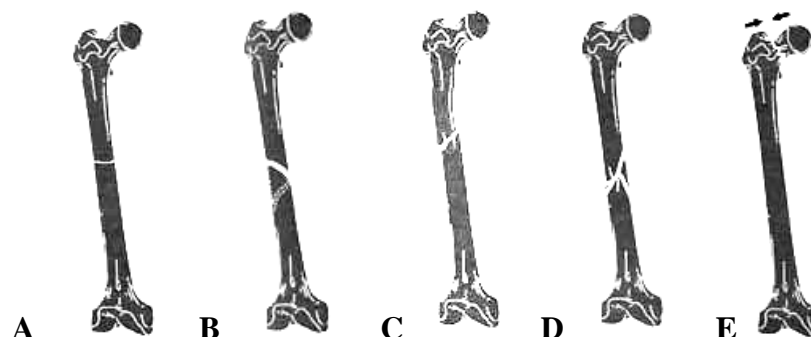


Figure 2.3 — Diagram (A to E) common the X-ray signs of fractures patterns.
(A) Transverse fracture; (B) oblique fracture; (C) spiral fracture; (D) comminuted fracture (2 or more fragments); (E) impacted fracture (arrows)

Displacement of fragments at a bone fracture

Fractures are also described in terms of alignment. Below are the definitions of the various types of alignment that result from the fracture patterns just described. Displacements are described according to direction of movement of the distal fragment relative to proximal fragment (figure 2.4).

— Longitudinal displacement with a divergence of fragments (distraction) — is a separation of fragments.

— Longitudinal displacement with convergence of fragments (foreshortening) — fragments override each other.

— Longitudinal displacement with impacting fragments — occurs when fragments have been driven together.

— Angular displacement (angulation) — occurs when there is an angular deformity created by fragments.

— Rotation — occurs when fragments rotate over long axis.

— Displacement is a change in the anatomic axis of lateral fragment with respect to proximal fragment.

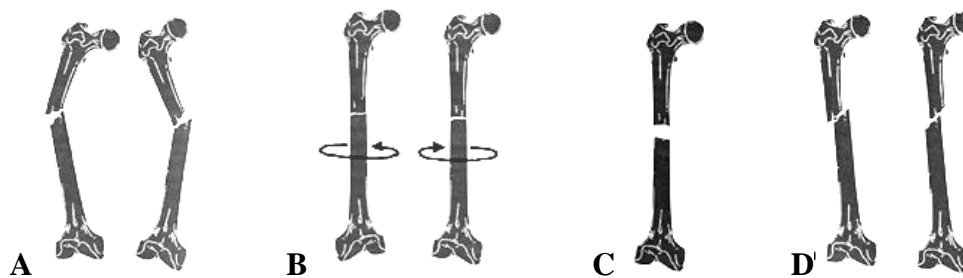


Figure 2.4 — Diagrams of fractures (A to D). (A) Varus vs valgus — varus and valgus deformities are both angulations. In varus deformity, there is apex angulation away from the midline and the distal structure moves medially. In valgus deformity, there is apex angulation toward the midline and the distal structure moves laterally. (B) Rotation of fragments. (C) Distraction — longitudinal separation of fracture fragments. (D) Displacement of fragments medial vs lateral

Fractures through abnormal bone are called «pathological» fractures. Probably the most common cause of this is an underlying tumor, either benign or malignant.

With chronic repetitive stress, one can break any bone in the body. If the fracture is fairly new, then there may be no plain film evidence of it. Later, once the fracture has been around long enough, periosteal reaction is often seen adjacent to the fracture site. A radionuclide bone scan or MRI can be used to screen for stress fractures. The bone scan will show a stress fracture as an area of increased uptake of tracer, while MRI will show focal or diffuse marrow edema at the fracture site.

The main reason prompting the early diagnosis of stress fracture is so that the patient can be advised to rest the affected part. If the affected part continues

to be loaded, then a stress fracture may develop into a completed fracture through the bone.

Fractures in children

The patterns of bony injuries in the child are somewhat different to the adult as the skeleton is more elastic and less brittle. Children have fractures more often than adults because children have slender bones and are more active.

Healthy bones of children mend faster and better than the more brittle bones of older people. (A femur broken at birth is fully united within 3 weeks, but a similar break in a person over 20 may take 5 months to heal completely.)

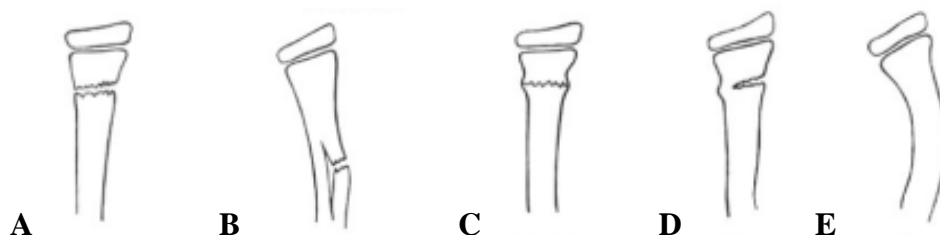


Figure 2.5 — (A to E) Diagrams of typical fracture patterns in children. (A) Complete fracture. (B) Greenstick fracture. (C) Buckle fracture. (D) Pipe fracture. (E) Bow fracture

Fractures in children (figure 2.5) are classified as:

- Complete.
- Greenstick fracture. A greenstick fracture is an incomplete fracture. The cortex is broken on one side and buckled on the other with a bending deformity concave to the buckled side.
- Torus (buckle) fracture. A buckle fracture is a buckling of the cortex produced by compression (impaction) forces.
- Pipe fracture. A pipe fracture is a combination of an incomplete transverse fracture of one cortex and a torus fracture of the opposite side.
- Bowing injury. A bowing injury results without a line of fracture.
- Epiphyseal/metaphyseal fractures.
- Avulsion injuries.
- A fragment of bone may be avulsed (pulled-off) at the insertion of a ligament or tendon at any age.

Fracture healing

Successful fracture healing is dependent on fragment apposition, fracture fixation, and ample blood supply.

Consolidation. Osteoclasts are introduced by the penetrating capillary buds and assist the osteoblasts to alter the bone callus from woven to lamellar bone. Callus — new bone formed at/around fracture site approximately 3 weeks after the initial trauma. It is visible on a radiograph. X-ray signs of fracture's consolidation:

- smoothing of the bone's margins (at recent fracture they are sharp);
- tender calcifications in fracture area (in 3 weeks after trauma);
- bone callus formation;
- disappearance of fracture line.

Remodeling. Over a period of months to years, the bony bridge is remodeled to the pretrauma size and shape, or as near to it as possible. Excessive callus is removed and the medullary canal is recanalized. Children have greater powers of remodeling and may correct deformities and even discrepancies of length after a fracture.

The time it takes for union varies depending on age, health status, and bone injured. Generally a weak bone callus is formed by weeks 3 to 6, becoming thicker over months. This callus may be faintly seen on radiographs. Healing continues as the bone regains much of its initial strength by 3 to 6 months.

Dislocation and subluxation

Dislocation — complete disalignment of articular surfaces, complete and constant shift of the articular ends of bones (figure 2.6). It is considered to be dislocated a peripheral (distal) bone.

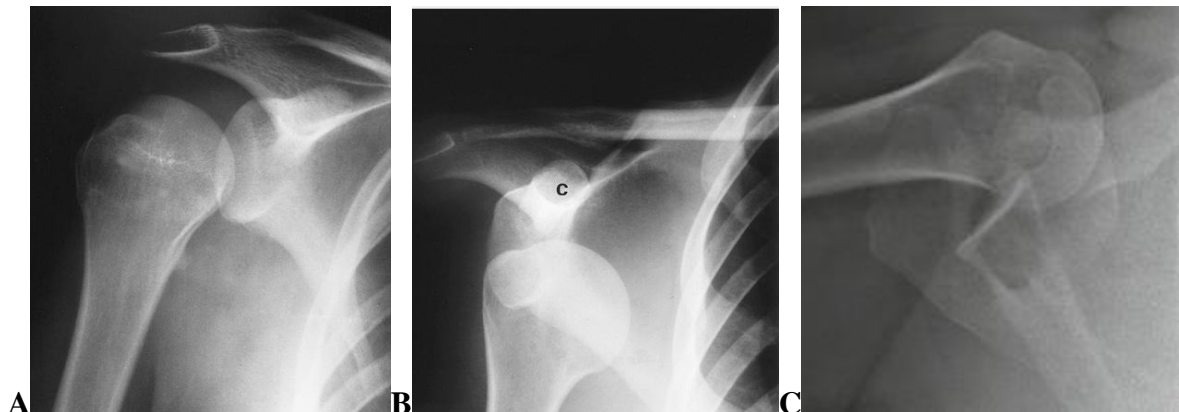


Figure 2.6 — (A) Normal anteroposterior view region of the right shoulder. Note in this example of a normal shoulder that the humeral head slightly overlaps the glenoid, which has been termed the crescent sign. (B) Anterior shoulder dislocation, anterior view. An anteroposterior view of the right shoulder shows the humeral head to lie medial to the glenoid and inferior to the coracoid process (c). This is diagnostic of an anterior dislocation of the shoulder. (C) Anterior shoulder dislocation, axillary view

The main X-ray signs of a dislocation: complete absence of contact of articular surfaces with complete incongruence of articular surfaces, apposition between them is lost. Dislocation may occur in isolation or with a fracture (so-called fracture-dislocation).

The main X-ray signs of a dislocation:

— a joint is dislocated (luxated) when its articular surfaces are wholly displaced one from the other, so that apposition between them is lost;

— subluxation exists when the articular surfaces are partly displaced but retain some contact with each other;

— dislocation may occur in isolation or with a fracture (so-called fracture-dislocation).

Subluxation — incomplete conformity (discrepancy between) of articular surfaces. Subluxation exists when the articular surfaces are partly displaced but retain some contact with each other. The main X-ray signs of a subluxation:

— incomplete conformity (dislocation) of articular surfaces

— clinoid deformation of an X-ray articular fissure

— shift of an axis of the dislocated bone.

Order radiological examination at of fractures and dislocation to included rule of 2's:

— 2 views — AP and lateral;

— 2 joints — include the joints above and below fracture.

Additional views should be pursued when there are uncertainties or in areas with complex anatomy.

When describing a fracture, one should describe the location, pattern and alignment. Remember, the alignment is described for the distal fragment relative to the proximal, with the patient in anatomical position.

The plan of the description of a roentgenogram at trauma:

— Image's name, age (osteal age).

— Area and of projection (view) of examination.

— Method of examination.

— At presence of fracture specify it on classification.

— Are there signs of a consolidation (smoothing of fragment's edges, presence of osteal callus)?

— Is there a luxation (subluxation)?

— Conclusion (diagnosis) (Example: Oblique complete fracture of a distal thirds of diaphysis of the right humerus with a lateral displacement 2cm of distal bone fragment and 1cm distraction).

Non tumour diseases

The non tumour diseases of bones and joints can be divided into majority of groups among which the main are the next: inflammatory diseases, degenerative diseases and lesions at defects of the mineral metabolism (figure 2.7). Among the inflammatory diseases the most common are osteomyelitis and tuberculosis of bones and joints but other infections and even aseptic inflammation is possible. Degenerative bones and joints diseases are very common in clinical practice and the X-ray examinations allow to reveal it in the majority of cases.

Metabolic bone disease

Metabolic bone disease is best shown using x-rays. The commonest metabolic bone disease is osteoporosis, and this is best shown using a dual energy x-ray absorption scan, which scans the lumbar spine and pelvis on a special machine, and gives a value for bone density, compared with a standard matched for age, sex, and ethnic origin. This is a reproducible test, and can be used serially to monitor treatment for osteoporosis.

A common form of metabolic bone disease in the United Kingdom is Paget's disease. In this disease, there is extensive vascularity of the bone with increased marrow fibrosis and intense cellular activity. This accounts for the overgrowth of the bone and enlargement shown in x ray images.

Osteoporosis — decrease of amount of osteal matter without change of a bone volume. X-ray signs: thinning of cortical layer of bones, dilatation of the medullar canal, increase of a bone transparency for X-rays.

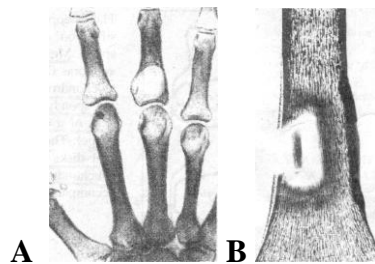


Figure 2.7 — (A) POSITIVE radiograph of part hand frontal projection. Local osteoporosis (white color) of phalanges and metacarpal bones. Rheumatoid arthritis. (B) Scheme sequestration, at centre of cavity is sequester of linear shape

Osteosclerosis — thickening and increase of amount of osteal trabecules in a constant volume of a bone, thickening of cortical layers, narrowing of the medullar canal. The volume of a bone does not change. The osteosclerosis can be physiological, pathological (posttraumatic, inflammatory, toxic), idiopathic.

Hyperostosis — increased amount of osteal tissue with the increase of the bone's volume.

Osteodestruction — destruction of a bone with displacing by pathological tissue (tumoral tissue, pus, granulations etc.). It is detected at an osteomyelitis, tuberculosis, tumors etc.

Osteonecrosis — necrosis of a fragment of a bone as a result of affection of its nutrition, inflammatory lesion, radiation injury or functional overload.

Sequestration — casting-off of a dead fragment of a bone. The formation of a sequester always is preceded by an osteonecrosis. It is detected at bone's tuberculosis or osteomyelitis.

Periosteal reactions

The periosteum is a membrane several cell layers thick that covers almost all of every bone. About the only parts not covered by this membrane are the parts covered by cartilage. Besides covering the bone and sharing some of its blood supply with the bone, it also produces bone when it is stimulated appropriately. What does it take to make this happen? Practically anything that breaks, tears, stretches, inflames, or even touches the periosteum.

With slow-growing processes, the periosteum has plenty of time to respond to the process. That is, it can produce new bone just as fast as the lesion is growing. Therefore, one would expect to see solid, uninterrupted periosteal new bone along the margin of the affected bone (figure 2.8).

With rapidly growing processes, the periosteum cannot produce new bone as fast as the lesion is growing. This may result in a pattern of one or more concentric shells of new bone over the lesion. This pattern is sometimes called lamellated or «onion-skin» periosteal reaction.

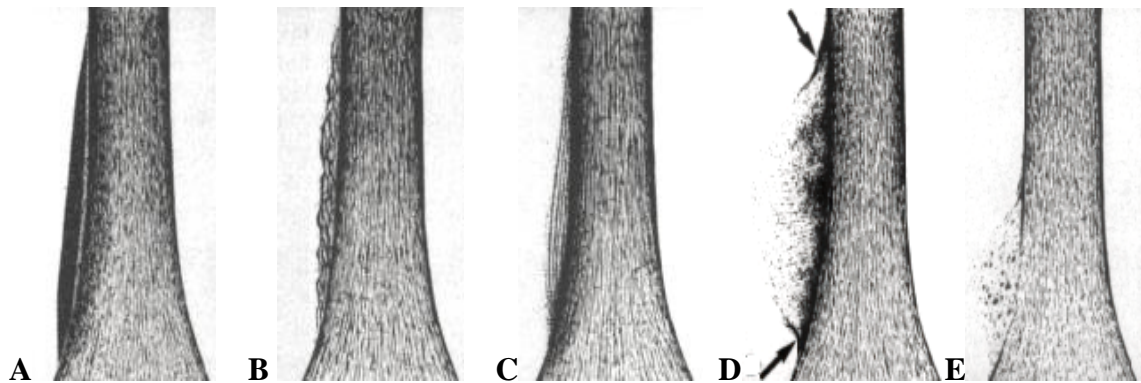


Figure 2.8 — The schemes various types of periosteal reaction. Types A and B are benign in appearance, and may be described as (A) thick and (B) undulating. Types C through E are more aggressive and more likely malignant and may be described as (C) lamellated or «onion skin», (D) perpendicular or «sunburst» (Codman's triangle figures, arrows), and (E) amorphous

Although not a perfect indicator, the pattern of periosteal reaction is one visual manifestation of a lesion's biological behavior.

If the lesion grows rapidly but steadily, the periosteum will not have enough time to lay down even a thin shell of bone, and the pattern may appear quite different. In such cases, the tiny fibers that connect the periosteum to the bone ossify, they produce a pattern sometimes called «sunburst» or «hair-on-end» periosteal reaction.

Another pattern seen in rapidly growing processes is called the Codman's triangle. This is a bit of a misnomer, since there really is not a complete triangle. When a process is growing too fast for the periosteum to respond with even thin shells of new bone, sometimes only the edges of the raised periosteum will ossify. When this little bit of ossification is seen tangentially on a radiograph, it forms a small angle with the surface of the bone, but not a complete triangle.

If we see a solid pattern of periosteal reaction, the usual way that this may manifest is when there is a fracture or infection in the same area as a tumor. In this case, may see a fairly complex pattern of periosteal reaction that demonstrates some elements that look benign and some that look very aggressive.

Causes of solid periosteal reaction:

- infection;
- benign neoplasms;
- eosinophilic granuloma;
- hypertrophic pulmonary osteoarthropathy;
- deep venous thrombosis (lower extremity).

Causes of aggressive periosteal reaction:

- osteomyelitis;
- malignant neoplasms:
 - osteosarcoma;
 - chondrosarcoma;
 - lymphoma;
 - metastasis.

Approaches to arthropathies

Many classifications of joint diseases are available based on differing criteria (X-ray appearances, a etiology, etc.). It most useful to decide first whether there is involvement of a single joint (monoarthropathy), or multiple joints (polyarthropathy).

Polyarthropathies may be divided into three large categories: inflammatory, degenerative, metabolic.

These arthropathies tend to present with symmetrical arthropathy involving the peripheral small joints, especially the metacarpophalangeal and proximal interphalangeal joints. X-ray signs may be subtle and include soft tissue swelling and periarticular osteoporosis. Erosions are less common than with rheumatoid arthritis (RA). Soft tissue calcification is common, especially around joints. Inflammatory arthropathies present with painful joints with associated soft tissue swelling.

The presence of crystal deposits (chondrocalcinosis or tophi) indicates one of the crystalline arthropathies. In calcium pyrophosphate dihydrate deposition (CPPD) disease, the most common site of radiographic calcifications is in cartilage and in the joint capsule or synovial membrane.

Degenerative conditions

Degenerative bone disease is common, and is most usually imaged with conventional x-rays, although degenerative change in soft tissue is best shown using ultrasound.

A common etiology for osteoarthritis of the knee joint is development of a varus or valgus deformity at the knee. In a varus deformity, increased stress applied across the medial femorotibial articulation; in a valgus deformity, the increased stress is applied across the lateral femorotibial articulation. In either deformity, the stress produces subchondral osteosclerosis in the underlying tibial condyle and loss of its articular cartilage. Other common findings are periarticular osteophytes (a consequence of subchondral bone formation and remodeling) and subchondral cysts.

The radiographs were taken with the patient standing upright, so as to show the configuration of the knee when weight-bearing. The pertinent findings exhibited in the radiographs are as follows:

- The AP view shows a varus deformity at the knee. There is a marked loss of articular cartilage in the medial femorotibial articulation, as evidenced by the almost obliterated space between the medial femoral and medial tibial condyles. Such localized narrowing of a joint cartilage space is characteristic of osteoarthritis.

- There is subchondral osteosclerosis of the medial tibial condyle, as evidenced by the fact that the subchondral bone of the medial tibial condyle is more radiopaque than that of the lateral tibial condyle.

- The AP view shows periarticular osteophytes along the medial margin of the medial tibial plateau,

- The lateral view suggests that there is also narrowing of the patetofemoral joint space.

- The AP and lateral radiographs together show a calcified body behind the medial part of the distal femur; this calcified body is not a fabella.

Deforming arthrosis — slowly developing degenerative non-inflammatory disease of joints, mostly large joints, mostly in elder people and occur due to intensive physical activity, vibrations, traumas etc. Pathological changes might be localised in a single joint or multiple affections are possible. In the basis of the disease is the degenerative process and destruction of the articular hyaline cartilage and the follow-up affection of articular surfaces of bones (figure 2.9). The main radiologic changes detected are:

- Narrowing of the joint space (at the severe affection, up to disappearance of the joint space).

- Sclerosis of the opposing articular surfaces.

- Roughness of the articular surfaces.

- Marginal bone peaks (osteophytes).

Additional findings: cystic bone resorption (so-called pseudocysts), osteoporosis, luxations and subluxations.

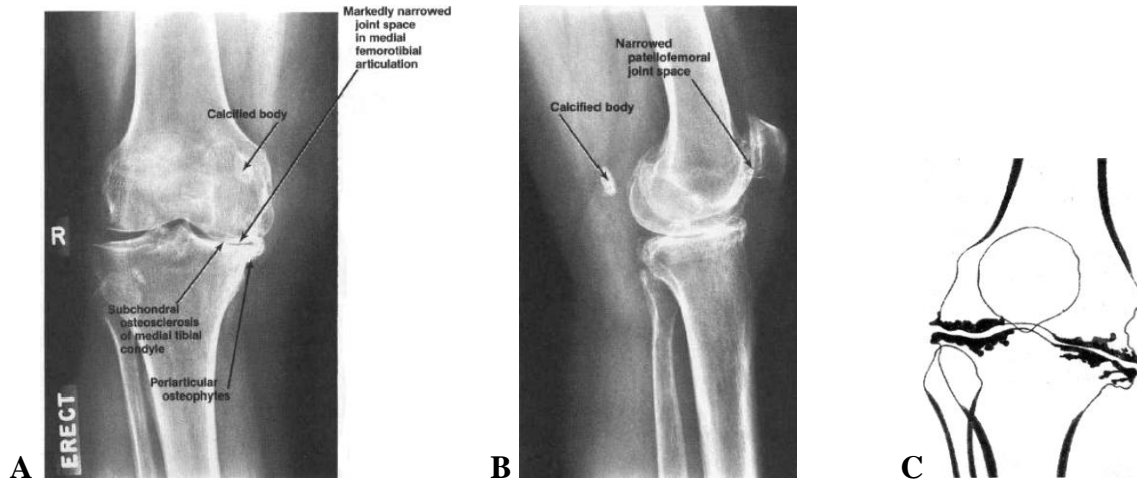


Figure 2.9 — The frontal (A) and lateral (B) radiographs show evidence of severe osteoarthritis of the right knee, x-ray showing serious degenerative disease. (C) Scheme of deforming arthrosis. Markedly narrowed of the joint space, osteoclerosis (subchondral) of articular surfaces, marginal bone peaks — periarticular osteophytes (lateral and medial)

Degenerative: osteoarthritis.

Primary osteoarthritis (OA) refers to degenerative arthropathy with no apparent underlying or predisposing cause. Secondary OA refers to degenerative change complicating underlying arthropathy such as RA, trauma or Paget's disease. Distribution of primary OA: asymmetric, large weight-bearing joint (hip, knee). X-ray signs of OA include:

- Secondary degenerative change with subchondral cysts and joint space narrowing is common.
- Osteophyte formation.
- Periarticular erosion and cyst formation.
- Periarticular sclerosis.
- Loose bodies due to detached osteophytes and ossified cartilage debris.

Any joint in the body can be affected by secondary osteoarthritis due to trauma, infection or another arthropathy. However, the findings of primary (idiopathic) osteoarthritis are usually seen in the distal interphalangeal and metacarpal joints.

Arthritis

Radiographic hallmarks: in general, the presence of erosions bespeaks some type of inflammatory disease, whether the erosions are due to synovial hypertrophy, crystalline deposits, or infection. Osteophytes can be seen in both primary and secondary osteoarthritis. Osteophytes can also be seen at various entheses (sites of tendinous or ligamentous attachment to bone), often due to altered or increased stress there.

Other findings, such as joint space narrowing, subchondral sclerosis, subchondral cyst formation, ankylosis, or subluxation are not especially specific and may occur in a wide variety of degenerative or inflammatory disorders in the appendicular skeleton. It is important to describe these findings, as they tell us a

lot about the severity of the patient's disease — it's just that they don't tell us a whole lot about what specific disease is causing them.

Septic arthritis: joint may be radiographically normal at time of initial presentation. Later a joint effusion and swelling of surrounding soft tissues may occur, followed by bone erosions and destruction.

Rheumatoid arthritis

Rheumatoid arthritis, characterized by periarticular osteoporosis, marginal erosions, boutonniere deformity, swan neck deformity, subluxations, and dislocations, tends to affect the metacarpophalangeal joints and proximal interphalangeal joints (figure 2.10).

- Symmetrical distribution.
- Affects predominantly the small joints, especially hand and wrist.
- Bone erosions: occur earlier in the feet than the hands.
- Periarticular osteoporosis.
- Abnormalities of joint alignment: subluxation of joints.

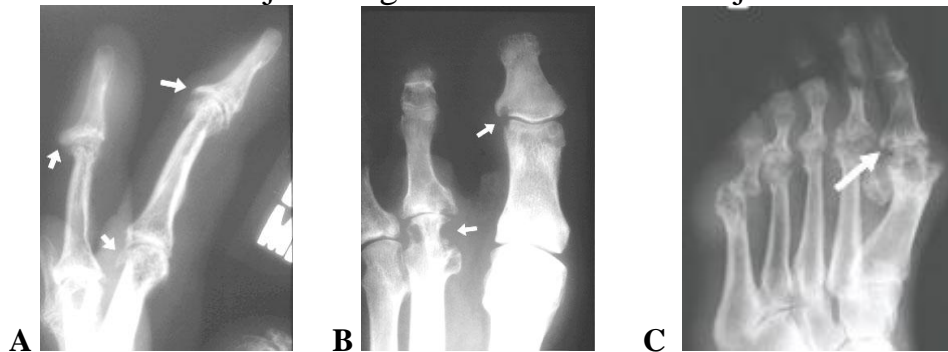

Figure 2.10 — (A) Marked osteophytosis (arrows) and (B) erosions (arrows) at rheumatoid arthritis. (C) Frontal radiograph part of foot, rheumatoid arthritis. Subluxation, concentric loss of joint space, erosions (arrow), and the destruction of the articular surfaces are hallmarks of RA. The soft tissue swelling is anti-cipated

Osteomyelitis

Osteomyelitis is an infection of bone and bone marrow. Although it is usually caused by bacteria, it also can be caused by fungi and other microbes. Although any bone can develop an infection, the bones of the knee, hip, and shoulder are most commonly affected. Osteomyelitis tends to affect long bones, particularly those in the lower extremities. In children, hematogenous osteomyelitis usually is located in the metaphyseal region of long bones, with the most commonly affected bones being the femur and tibia. The epiphysis is more commonly involved in neonates and adults than in children.

Plain film radiography may not detect the early stages of bone infection, the features of which often do not appear for several weeks or even months after implantation; repeat examinations usually are necessary. One of the earliest

signs of osteomyelitis is deep soft-tissue swelling. Distortion or obliteration of fat planes and subcutaneous edema may be evident 3 to 10 days after infection. Focal osteopenia within the medullary cavity typically occurs first, followed by cortical destruction in a focal or multifocal presentation (figure 2.11). Radiographic symptoms of osteomyelitis includes:

- Usually normal for up to 7–14 days following infection.
- Soft tissue swelling, loss of fat planes.
- Metaphyseal destruction and periosteal reaction.
- Epiphyseal lucency in infants.

During the middle stage of osteomyelitis, a cortical breach develops and leads to periostitis approximately 3 to 6 weeks after infection. As suppurative osteomyelitis develops, pus moves into the vascular channels, raising the intra-medullary pressure and impairing blood flow. Ischemic necrosis hastens the damage and results in pockets of dead bone called sequestra. The sequestra appear no earlier than 3 weeks after infection.

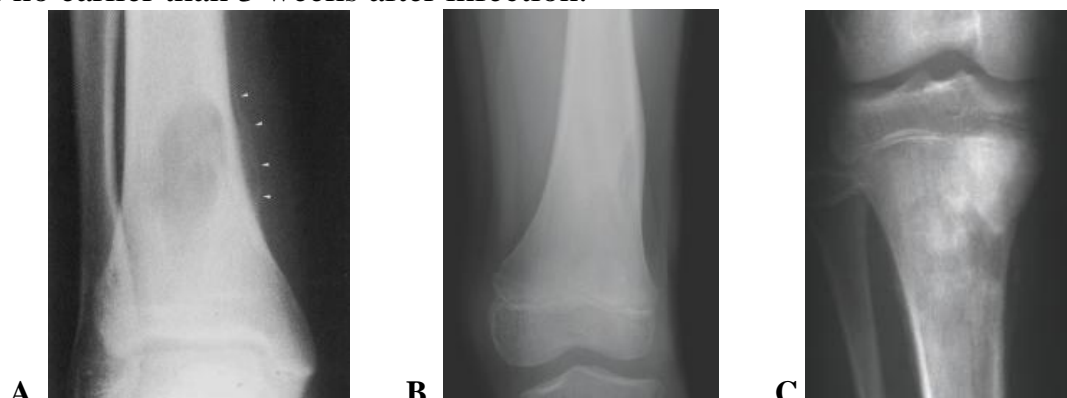

Figure 2.11 — Frontal radiographs of leg. (A) Osteomyelitis (i.e. Brodie's abscess). Magnified radiograph of the right ankle showing a large lytic tibial lesion. Notice the periosteal reaction medial to the tibia (arrow heads). (B) Radiograph of the distal thigh showing a lytic lesion of medial area of femur at early osteomyelitis. (C) Chronic osteomyelitis of proximal tibia.

Table 2.2 — Main principles of a differential X-ray diagnosis

Diagnostic criteria	Osteomyelitis of bones and joints	Tuberculosis of bones and joints
Patient's age	Any	Anv. but often not more than 20 years old
The most often localization	Metaphysis and diaphysis	Epiphysis and metaphysis, vertebral bodies
Number of the affected bones	As a rule — one	The adjacent bones can be affected
General characteristic of a bones lesion	Combination of destructive and sclerotic changes and a sequestration	Mainly destructive process with a sequestration
Condition of a surrounding osteal tissue	Osteosclerosis	Osteoporosis. The sclerotic changes arise only at decrease of inflammatory process

Periostitis	Linear or fimbria-shaped	Defected seldom — only at diaphyseal lesions
Condition of the adjacent joints	As a rule, are not changed	The destructive process often transfers to a joint
Sequestration	The sequesters are dense, surrounded with a area of an enlightenment	Small spongiform sequesters of small density
The contours of the destruction zone	In the beginning of disease — unclear and rough, later become clear	Unclear, blurred

Tuberculosis of bone

Tuberculosis of the skeleton is a pathology that was rare in recent times, except in those areas where there is recent immigration from the third world. Since more than a third of our catchment population is from Gujerat in India, we are used to seeing tuberculosis of bone.

The radiograph will show bone destruction and this process will breach fibrous tissues boundaries more easily than will tumour. Joint space loss would be as well as the patches of bone destruction. The characteristic feature of tuberculous arthritis as opposed to pyogenic infection is the relative preservation of the weight bearing surfaces and destruction at the joint margins (table 2.2, figure 2.12). The following of findings historically have suggested tubercular arthritis:

- juxtaarticular osteoporosis;
- peripherally located osseous erosions;
- gradually narrowing joint space.

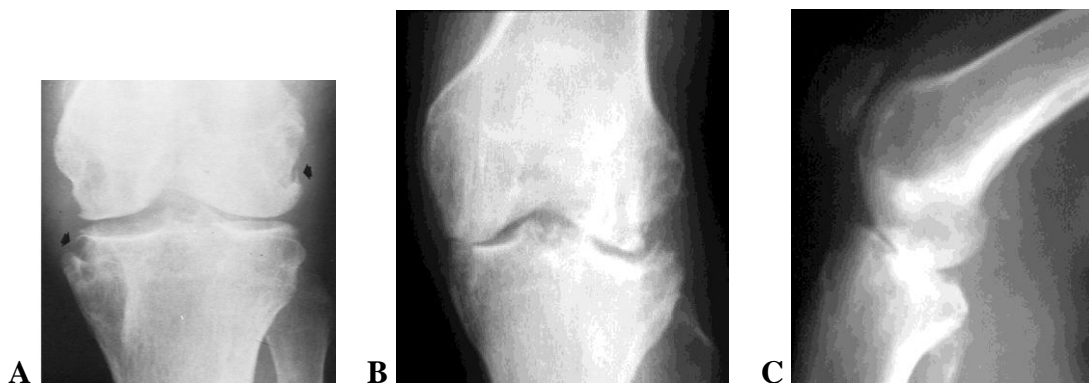

Figure 2.12 — Radiographs region of knee. (A) Tuberculous arthritis of the knee. On both sides of the joint there are destructive bone lesions (arrows) involving the medial and lateral condyles and the medial aspect of the proximal tibia. Note the relative sparing of the articular cartilage and preservation of the joint space in view of the degree of bone destruction. (B, C) Different patient with two views, tuberculous arthritis of the knee.

Neoplastic bone disease

Neoplastic bone disease may be either primary or secondary. Secondary malignant bone disease is much more common than primary, and is best imaged using either nuclear medicine or magnetic resonance imaging. Although magnetic resonance imaging is more sensitive than bone scanning and does not use io-

nising radiation, it is more expensive and takes much longer. For this reason, bone scanning is the primary investigation in the United Kingdom.

Imaging studies are essential for detecting, characterizing, and staging bone lesions. Radiographs, computed tomography, magnetic resonance imaging, and radionuclide scans all play a role (table 2.3). Angiography is useful for evaluating tumor vascularity and for preoperative embolization.

Table 2.3 — Effectiveness of imaging studies for evaluating features of bone tumors

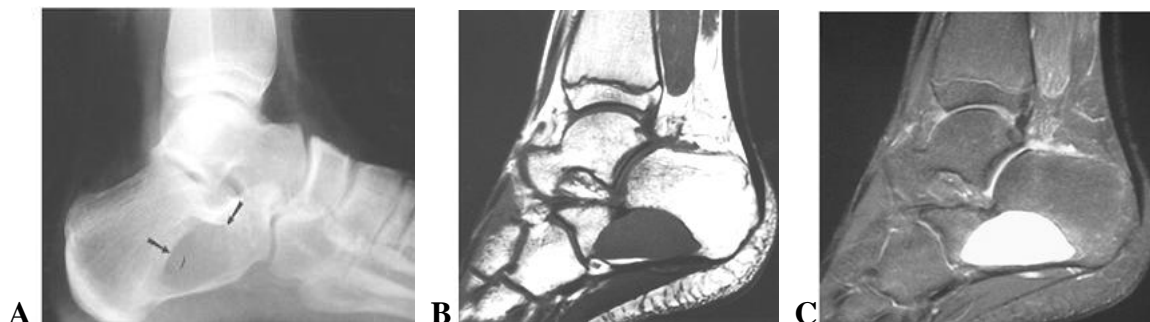
Radiographs	CT	MRI	Radionuclide scans
<i>Lesion morphology</i>	<i>Thin cortical bone</i>	<i>Lesion extent</i>	<i>Early detection in marrow and soft tissues</i>
Site (cortical, marrow, diaphysis, epiphysis)	Bone destruction or production	Joint space involvement	Skip lesions
Bone production or destruction	Periosteal response	Marrow edema	Metastasis
Periosteal response	Calcifications/matrix	Cortical destruction	—
Soft tissue calcification or ossifications	Trabecular destruction	—	—

Bone tumours can be further classified according to their tissue of origin including:

- bone-forming (osteogenic) e.g. osteosarcoma;
- cartilage-forming (chondrogenic) e.g. chondrosarcoma;
- fibrous (fibrogenic) e.g. fibrosarcoma;
- vascular e.g. angiosarcoma.

Radiographic patterns of bone destruction or production (figure 2.13):

- Geographic: least aggressive. Margins may be sclerotic, well defined without sclerosis, or ill defined.
- Moth-eaten: more aggressive, less well defined. Longer zone of transition. Seen with malignant lesions and osteomyelitis.
- Permeative: most aggressive with more rapid destruction. Margins not defined.
- Bone formation with calcification or ossification, periosteal response.



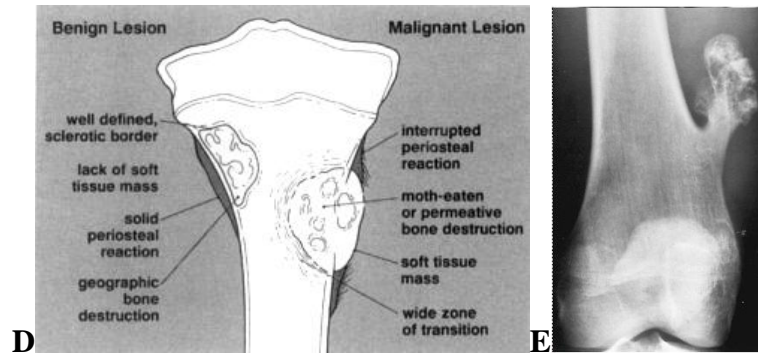


Figure 2.13 — Patterns of bone destruction «geographic». (A) Lateral radiograph of the calcaneus showing a well-defined geographic lytic lesion (arrows). (B) T1-weighted and (C) T2-weighted magnetic resonance images showing homogeneous fluid signal caused by a benign unicameral bone cyst. (D) Schematic diagram of the radiographic features that can help differentiate benign from malignant bone lesions. (E) Frontal radiograph distal region of thigh. Osteochondroma of the distal femur. The long axis of the tumor is parallel to that of the femur and pointed away from the knee joint

Primary bone tumors

There are several different types of bone tumors. Their names are based on the area of bone or surrounding tissue that is affected and the kind of cells forming the tumor. Some primary bone tumors are benign (not cancerous), and others are malignant (cancerous). Most bone cancers are called sarcomas. This is a term that describes the type of tissue that the cancer started in. Sarcomas are cancers that start in bone, muscle, fibrous tissue, blood vessels, fat tissue, and other tissues. In primary bone neoplasms, the age of the patient and the site of the disease are important pointers to the diagnosis. Although conventional x-ray images are often obtained, the best form of imaging is magnetic resonance imaging.

Benign bone tumors (figure 2.14)

Benign bone tumors do not spread to other tissues and organs and are not life threatening. They are generally cured by surgery. Types of benign bone tumors include osteoma, osteochondroma, enchondroma, and chondromyxoid fibroma.

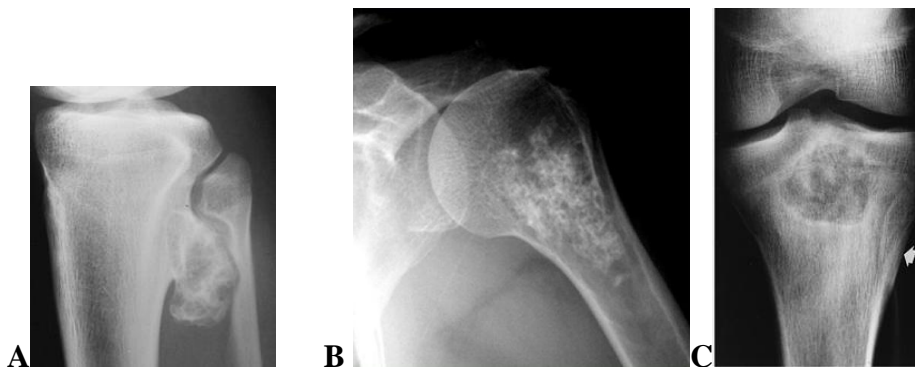


Figure 2.14 — (A) AP radiograph demonstrates a proximal tibia osteochondroma. (B) Central enchondroma. Radiograph of the humerus showing a chondroid lesion with calcifications. (C) Chondroblastoma. AP radiograph demonstrates a proximal tibial lesion

with sclerotic margins and calcifications. There is subtle periosteal reaction (arrow)

Osteoma — a benign dense/sclerotic focal new bone formation (bone island) with well-marginated (clear of border), wide variety in appearance, may be at variant of exostosis. Benign (non-cancerous) tumors of cartilage are more common than malignant ones. These are called enchondromas. Radiographic features: medullary with sharp margins, small round or oval cystic defects, typically with stippled matrix calcification and endosteal scalloping. May be multiple. Another type of benign tumor is the osteochondroma. This is a bony projection capped by cartilage. Both of these benign tumors rarely turn into cancer. Common locations: distal femur, proximal tibia, proximal humerus. Radiographic features: bony projection with contiguous marrow and cortex from bone of origin. Sessile or pedunculated («coat hanger» exostosis or «cauliflower cap») cartilage capped bony outgrowth that is continuous with underlying bone.

Giant cell tumor of bone: this type of primary bone tumor has benign and malignant forms. The benign (non-cancerous) form is most common. These tumors typically affect the leg (usually, near the knees) or arm bones of young and middle-aged adults. Radiographic features: a subarticular, eccentric lytic lesion with a geographic, nonsclerotic margins originating in the metaphysis but extending to subchondral bone, cortical break.

Malignant bone tumors

Osteosarcoma (also called osteogenic sarcoma) is a cancerous tumor of the bone itself, and it is the most common primary bone cancer (figure 2.15). Common locations: distal femur or proximal tibia (48 %), pelvis and proximal femur (14 %), shoulder and proximal humerus (10 %).

Radiographic features: metaphyseal lytic, blastic, or mixed appearance. Lesions poorly defined with aggressive periosteal response (spiculations or Codman triangles). Soft tissue extension common. Differential diagnosis: Ewing sarcoma, fibrosarcoma, chondrosarcoma, giant cell tumor, osteomyelitis.

CT features: similar to radiographic features. MRI features: imaging features are nonspecific. Signal intensity varies with matrix (decreased with blastic, increased with lytic on T2-weighted sequence). Staging of marrow and soft tissue involvement is the primary indication for MRI.

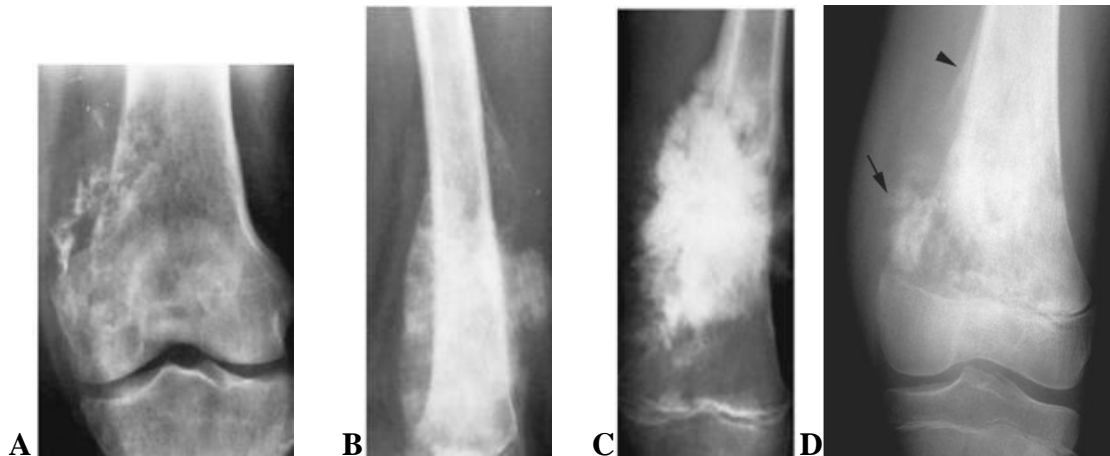

Figure 2.15 — Osteosarcoma. (A to D) Four examples of osteogenic sarcoma of the femur illustrate the broad spectrum of radiographic changes. There are various amounts of exuberant, irregular periosteal response and irregularly dense ragged bone destruction. (D) AP radiograph of the distal femur showing a classical osteosarcoma with mixed lytic and sclerotic areas, tumour bone formation in the extraosseous mass (arrow), and a proximal Codman's triangle (arrowhead)

Magnetic resonance imaging is also used in secondary malignant bone disease, especially where there are neurological complications as surgical intervention may be needed, and the exquisite detail on a magnetic resonance image is invaluable to the surgeon.

Chondrosarcoma is a cancer of cartilage cells and is the second most common primary bone cancer. Most develop in bones such as the pelvis, leg bone or arm bone. Radiographic features: destructive lesions appearing as a central lesion in bone with stippled calcifications, and cortical scalloping, or as a peripheral lesion extending from the bone's surface appearing as an exploded osteochondroma.

Ewing tumor: (also called Ewing sarcoma). Ewing tumors usually develop in bones, and less than 10 % arise in other tissues and organs. They most often arise in the long bones of the legs and arms but may also develop in the pelvis and other bones. Ewing tumor is the third most common primary bone cancer. Unlike osteosarcoma, Ewing tumors of bone form in the cavity of the bone. Cancer usually is uncommon in adults. Radiographic features: long diaphyseal lesion with permeative pattern. May have sclerosis or mixed appearance. Aggressive periosteal (laminated characteristic of Ewing sarcoma) response and soft tissue mass common (figure 2.16).

CT features: similar to radiographic features; periosteum and soft tissue better defined. MRI: signal intensity variable in mixed or sclerotic lesions. High signal intensity on T2-weighted and low signal intensity on T1-weighted with lytic permeative lesions. Differential diagnosis includes: lymphoma, osteosarcoma, osteomyelitis.

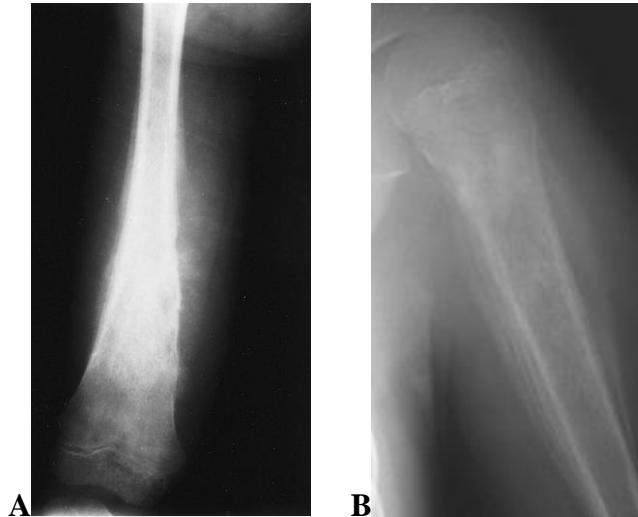


Figure 2.16 — Ewing sarcoma. (A) An anteroposterior plain film of the femur of a child shows a predominantly sclerotic process with large amounts of sunburst periostitis in the diaphysis. (B) Typical appearance in the proximal humeral metadiaphysis with permeative marrow destruction, ‘hair-on-end’ and multilaminated periosteal reaction

Myeloma

Myeloma is the most common primary bone malignancy. Common locations: skull, axial skeleton, ribs. Radiographic features: typically multiple small lytic foci, osteopenia, «punch-out» lesions, «raindrop» skull (figure 2.17). May be a solitary lesion, bone expansion and soft tissue mass common, especially in the ribs. Differential diagnosis: metastasis, lymphoma.

Bone metastases

Most bone scans in metastatic disease look fairly similar and simply tell us that there is widespread disease. They do not usually indicate the primary. Bone metastases are often clinically occult, or they present with bone pain, pathological fracture or hypercalcaemia. X-ray patterns includes:

- Most commonly lytic solitary or multiple lesions. Lesions may be sclerotic, or mixed, depending on primary tumor (figure 2.18).
- Cortical destruction, without periosteal reaction.
- Most common sites are axial skeleton, proximal long bones.

Radionuclide scans: best screening technique for most metastatic lesions. Metastases seen as areas of increased tracer uptake. CT: useful for treatment planning of focal lesions. MRI: signal intensity varies. Differential diagnosis: multiple myeloma, lymphoma.

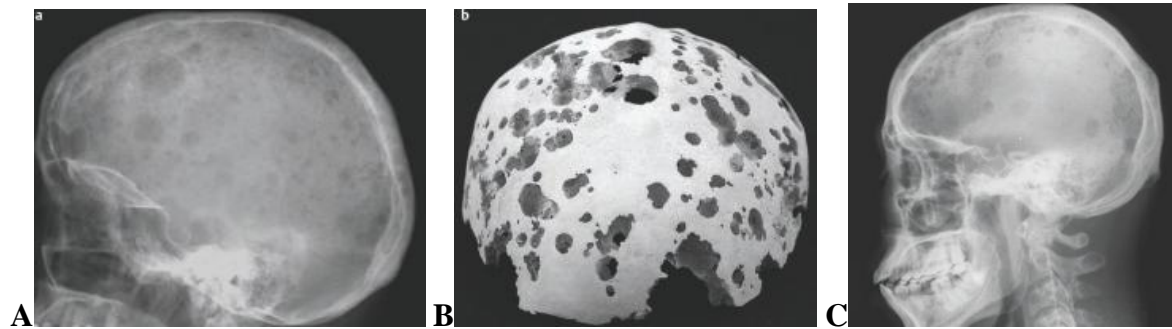


Figure 2.17 — (A) A lateral head radiograph demonstrates innumerable variably sized lytic lesions throughout the skull. (B) 3-D CT-reconstruction of skull. This appearance is typical for advanced multiple myeloma, which was this patient's diagnosis. (C) A lateral head radiograph of different patient, multiple myeloma of skull.

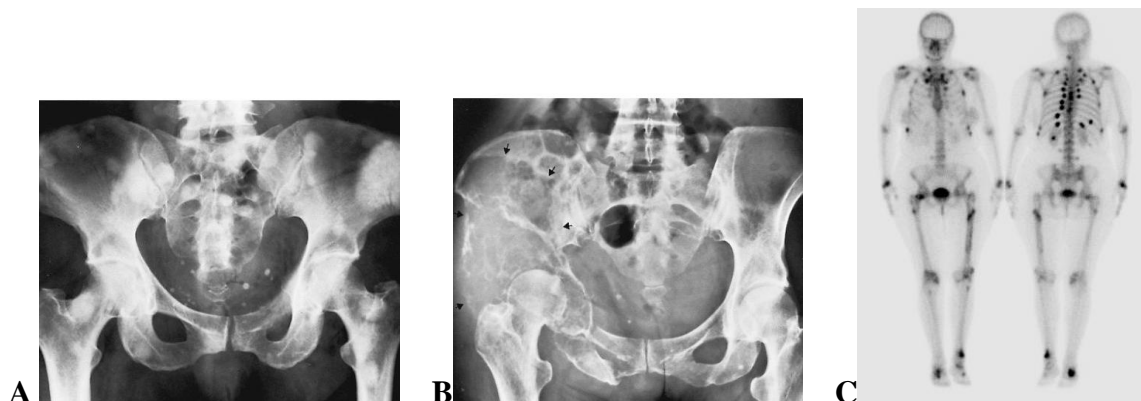


Figure 2.18 — (A) Osteoblastic metastases. Multiple areas of increased density involving the pelvis and proximal femurs representing metastases from carcinoma of the urinary bladder. (B) Metastatic thyroid carcinoma. Large area of entirely lytic, expansile destruction (arrows) involves the left ilium. (C) Two scintigrams (anterior and posterior view) of skeleton same patient. Note multiple areas of increased uptake of radiopharmaceutical in the pelvis, legs, vertebrae and ribs. This indicates multiple sites of increased osteo-blastic activity in a pattern typical of disseminated skeletal metastases. Metastases seen as areas of increased uptake of tracer (areas black color), bladder is normal

3. CHEST IMAGING

Introduction

Pulmonary specialists will almost never provide a consultation without having seen a chest x-ray. In under developed countries chest x-rays are obtained very selectively and physicians rely mostly on physical exam and history for diagnosis. Physical examination of the chest has inherent limitations. Lesions located in the mediastinum, interstitium of lung parenchyma, and in the center of the lung are rarely picked up by physical exam. Ease of availability of chest x-ray has made many physicians avoid time consuming physical exam which in

most cases fails to reveal all of the problems. As a result, physicians have lost the skill of physical exam. Just as physical examination has limitations, chest x-ray also has limitations, and it should be recognized that a normal chest x-ray does not rule out pulmonary problems.

The radiological examination of chest

The imaging examinations of the chest may be considered under the following headings:

1. Simple X-ray (plain film radiography).
2. Chest-screening (roentgenoscopy, fluoroscopy).
3. Tomography.
4. Bronchography.
5. Pulmonary angiography.
6. Scintigraphy (radionuclide scanning).
7. Computed tomography.
8. MRI.

1. Basic of chest radiography

Many chest radiographs are still acquired with conventional film-screen radiography systems that provide, at low cost, good image quality and high spatial resolution. The main structures imaged in the chest are the heart and lungs, although useful information may be obtained about the bones and soft tissues as well. A chest x-ray is the most commonly requested radiological examination, it is readily available and many patients present with some sort of chest symptoms such as cough or shortness of breath, or are being followed up for a malignancy. A lot of information can be got from chest x-rays; they deserve careful study.

Sometimes a problem cannot be resolved by plain x-ray. You can seek further help from:

1. Introduction of contrast material: bronchograms, angiograms, etc.
2. CT chest: three dimensional, computerized evaluation, high resolution.
3. MRI scan (can be used to differentiate between an active alveolar process and fibrotic scars).

The plain film is the most common method of chest examination.

Positioning for a PA chest x-ray

Different views of the chest can be obtained by changing the relative orientation of the body and the direction of the x-ray beams. The most common views are posteroanterior, anteroposterior, and lateral. In an posteroanterior (PA) view, the x-ray source is positioned so that x-rays enter through the posterior (back) aspect of the chest, and exit out of the anterior (front) aspect where they are detected

(figure 3.1). To obtain this view, individuals stand facing a flat surface behind which is an x-ray detector. A radiation source is positioned behind the patient at a standard distance, and x-ray beams are transmitted toward the patient.

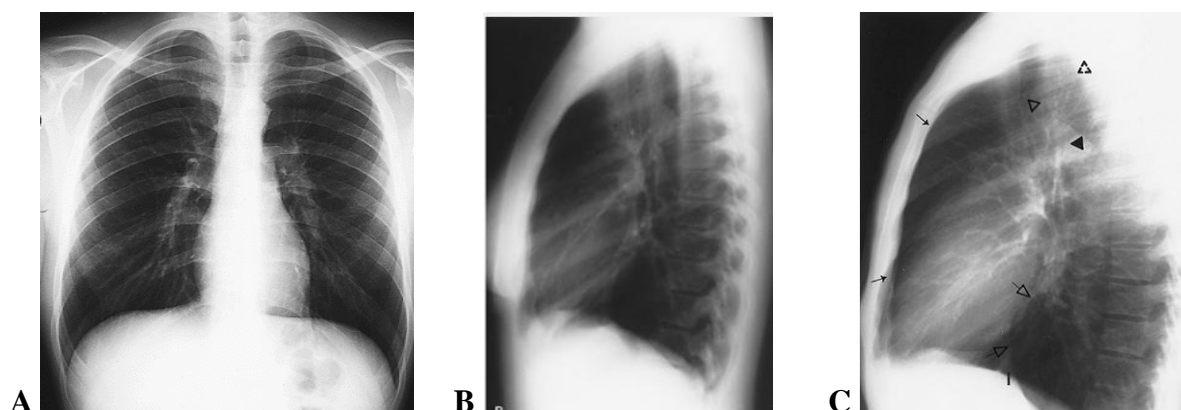


Figure 3.1 — (A) Normal lung PA and (B) lateral radiographs of the chest.

Adequate penetration of the patient by x-rays, good quality PA film.

(C) Radiolucent spaces on lateral chest radiographs. The retrosternal space is demarcated anteriorly by the posterior margin of the sternum (small arrows) and the heart and ascending aorta posteriorly and accounts for the anterior junction line seen on frontal radiographs.

The retrotracheal triangle is margined by the posterior wall of the trachea anteriorly (open triangle), the spine posteriorly (broken triangle), and the aortic arch inferiorly (solid triangle). The retrocardiac space is demarcated anteriorly by the posterior cardiac margin (upper open arrow) and the inferior vena cava (I, lower open arrow)

A lateral radiograph is used to localise lesions in the AP dimension; locate lesions behind the left side of the heart or in the posterior recesses of the lungs. A left lateral (with the left side of the chest against the film and the beam projected from the right) is the standard projection.

Chest X-rays should be taken with a good inspiration, resulting in at least six ribs being visible anteriorly. Expiratory films are used to assess air trapping in bronchial obstruction such as a foreign body. A pneumothorax always appears larger on an expiratory film and occasionally a small pneumothorax may only be visible on expiration.

The next point to define is the position of a patient, who underwent an X-ray — vertical (erect) or horizontal (supine). Whenever possible the chest X-ray film is to be taken in erect or sitting position, because many intrathoracic conditions (e.g., pleural fluid, pneumothorax, mediastinal width) are difficult to assess when the film is taken with the patient lying down.

The control of accuracy of a patient's posing is carried out on a correlation of the internal ends of clavicles and medial line of the body. The difference between these two distances is to be not more than 5 mm.

Then the breath phase is to be determined — inspiration or expiration film is done (figure 3.2). The position of the diaphragm shows the breath phase.

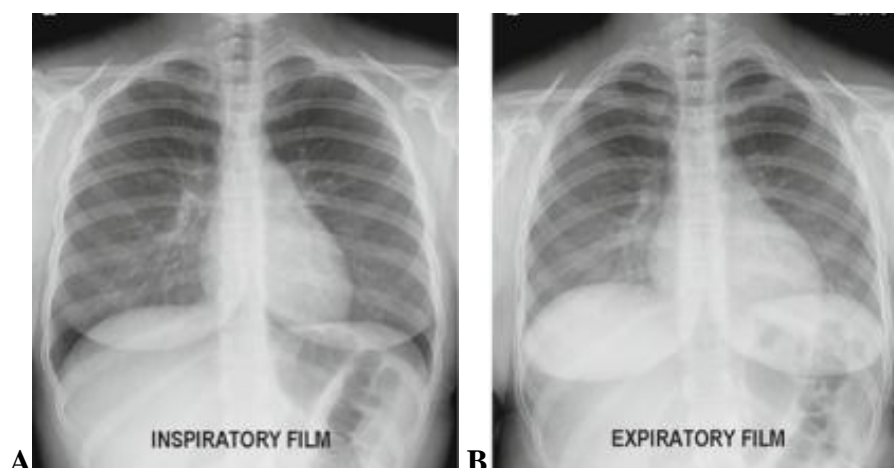


Figure 3.2 — (A) Inspiratory and (B) expiratory the radiographs female here are those of inspiration and expiration. Note the difference in the size of the lungs and their apparent difference in densities

Inspiration — at the inspiration phase the diaphragm is seen: on the right side — at the level of the 6th rib, on the left side — at the level of the 7th rib; at the expiration phase: on the right side — at the level of the 4th rib, on the left side — at the level of the 5th rib (frontal ends of ribs mentioned).

Rotation — the medial aspect of the clavicles should be symmetrically positioned on either side of the spine. The technologists are usually very careful to x-ray the patient flat against the cassette. If there is rotation of the patient, the mediastinum may look very unusual. One can assess patient rotation by observing the clavicular heads and determining whether they are equal distance from the spinous process of the thoracic vertebral bodies. Rotation causes the problem in the evaluation of the mediastinal borders and vascular status of the patient.

Quality of film

The final aspects of image quality that I will discuss are the concepts of exposure and penetration. With modern equipment, it is much less common to encounter problems in these areas.

Penetration is determined by the voltage setting on the x-ray tube. Penetration determines how well x-rays travel through the body. In a well-penetrated chest radiograph the vertebral bodies will be just discernable through the heart on the frontal film, the vertebral bodies should just be visible through the cardiac silhouette. Adequate penetration of the patient by radiation is also required for a good radiograph (figure 3.3). On a good PA film, the thoracic spine disc spaces should be barely visible through the heart but bony details of the spine are not usually seen. On the other hand penetration is sufficient that bronchovascular structures can usually be seen through the heart.

In an under-penetrated film the vertebral bodies will not be visible. In an over-penetrated film the vertebral bodies will be seen too well. Over penetration is a problem because it means that pathology in the lungs will likely be missed.

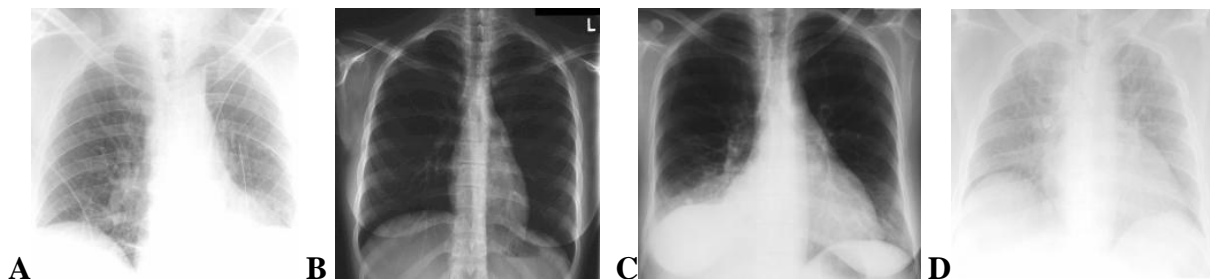


Figure 3.3 — (A) Under-penetrated radiograph. Notice that the overall degree of blackening in the lungs is appropriate (exposure) but there is essentially no detail visible through the heart (indicating poor penetration). (B) Over-penetrated radiograph. Notice how unusually well the vertebral bodies are seen through the heart. The problem with over-penetration is evident in the lung fields, where detail of the parenchymal process is lost because of the poor technique. (C) Over-exposed radiograph. Notice that the lung fields appear far too black and almost all detail is lost, though the penetration is correct (the vertebral bodies are just discernable through the heart). (D) Under-exposed radiograph. Soft tissues in the image appear too white. The problem is clearly one of exposure, though, because the vertebral bodies are discernable through the heart

Exposure is determined by how many x-rays reach the film or detector. In general it is determined by the current and time settings (mAs) on the x-ray tube. Since x-rays cause a film to turn black, a well-exposed film will have dark areas where there is pure air (airways, outside the patient, etc.) but the non-air regions will be lighter shades of gray. In an under-exposed film, the film looks too white and it is difficult to determine whether there is pathology in the lungs. In an over-exposed film the film looks too black and all of the lung markings are lost. It should be noted that most over-penetrated films will also be over-exposed (because setting the voltage too high causes both problems), though most over-exposed films will not necessarily be over-penetrated (because setting the mAs too high does not affect penetration).

An underexpanded chest can create the impression of lung abnormality, for example, mimicking pulmonary oedema.

Lung fields

In the normal chest X-ray, the lungs are predominantly black and a branching pattern of vessels is seen. Lung fields is gray, have different size and shape: the right lung field usually is shorter and wider than the left. The transparency of lung fields is one of the most important signs. So, the transparency is to be analyzed by the comparing the symmetric parts of lung fields. If there is any difference in a transparency of symmetric zones, this appears to be a lesion. Lung fields should be of equal transradiancy and one should not be any whiter or darker than other (figure 3.4).

The transparency of lung fields is one of the most important signs. There is one important rule for analysing the lung transparency. So, the transparency is to be analyzed by the comparing the symmetric parts of lung fields. If there is any difference in a transparency of symmetric zones, this appears to be a lesion. There are two main groups of lung transparency changes: the shadow (opacification) and enlightenment (hyperlucent area).

Lobes and fissures: on the PA chest x-ray, the minor fissure divides the right middle lobe from the right upper lobe and is sometimes not well seen. There is no minor fissure on the left. The major fissures are usually not well seen on the PA view because you are looking through them obliquely. It is not always possible to tell the left from right major fissure because in the normal individual they overlies each other on the lateral radiograph. In some cases the minor fissure will also be visible on the lateral radiograph, running anterior to the major fissure. If there is fluid in the fissure, it is occasionally manifested as a density at the lower lateral margin.

Markings (vessels)

The pulmonary blood vessels are responsible for branching linear markings within the lungs. It is not possible to distinguish arteries from veins in the outer two-thirds of the lungs on plain radiographs. The «lung shadows» are composed of the pulmonary arteries and veins. Apart from the pulmonary vessels, the lungs should appear black (on negative film) because they contain air.

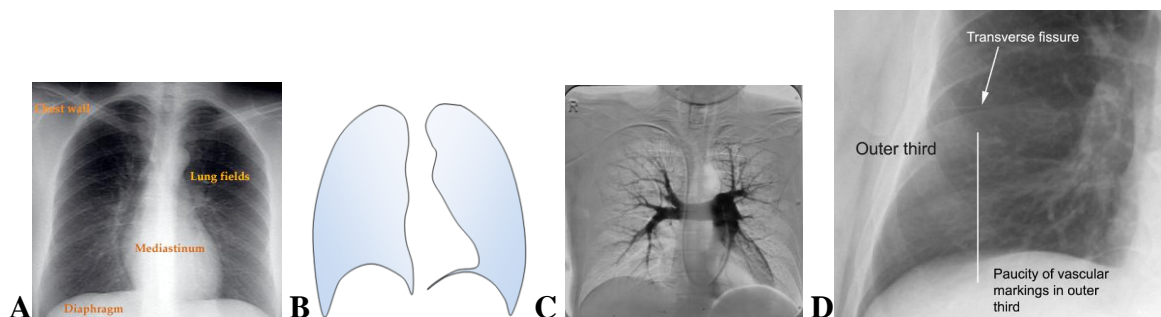


Figure 3.4 — (A) Radiograph chest with marked areas. (B) Diagram lung fields frontal projection. (C) Pulmonary digital angiogram shows appearances in arterial phase. Note the difference in arrangement of the central arteries. (D) Spot frontal radiograph of part chest, radiography without contrasting, features of lung vessel marking

The «lung pattern» (pulmonary vascular patterns) is only a roentgenological concept. The morphological basis of the lung markings pattern is the vessels of a lung blood circle the lung arteries and lung veins. Bronchi do not participate in formation of the lung pattern, as they contain air and are not visible on a back-ground of an airy lung tissue. The lung pattern looks as thin branchy shadows, directed from a hilus to external end of a lung.

The criteria of a normal lung pattern: the shadows of lung vessels have smooth outlines, regularly thin from hilus to external border of a lung and their image disappears at the distance 1.5–2 cm from the lateral end of lung field. (Because of presence of costodiaphragmal pleural sinuses the image of a lung pattern can be visible closely to diaphragm and even on a background of diaphragm). There are many types of changed lung pattern; the main types are increased, decreased, absent.

Some vessels of a lung pattern are settled orthograde (directed from front to back) and their image looks like small focal lesions. There is necessary to differentiate these images. There are five distinctive attributes of orthograde vessels:

- configuration of a shadow is always round or oval;
- outlines of a shadow are smooth;
- structure of a shadow is homogenous;
- shadow is settled down on crossing of longitudinal vessels;
- width of the orthograde vessel does not exceed the width of the adjacent longitudinal vessels.

There are many types of changed lung pattern; the main types are increased, decreased, absent.

The increased lung pattern: there is no regularly thinning of the vessels shadows (the vessels on a long extent keep identical width) and their image disappears at the distance less than 1.5 cm from the lateral end of lung field (the main reasons of increased lung pattern are dilatation of lung vessels so they become visible on a greater distance — for example at venous congestion or hyperemia).

The decreased lung pattern: there is a quick thinning of the vessels shadows and their image disappears at the distance more than 2 cm from the lateral end of lung field (the main reasons of decreased lung pattern are the increase of a lung tissue aeration (emphysema) or reduction of blood supply (for example, lung artery embolism at early stage, some heart diseases)).

The absent lung pattern: if there is no lung pattern then there is no lung tissue at this area. Therefore the absence of lung pattern is always on a background of shadowing (for example — pleural effusion) or enlightenment (for example — pneumothorax).

The central airways

The central airways can be well seen on both the frontal and lateral radiographs. It is always important to look for them and to evaluate both their patency

and course. The trachea, carina and main stem bronchi can be well seen through the mediastinum because they represent air-filled structures surrounded by soft tissue density (figure 3.5).

The trachea is a straight tube that, in children and young adults, passes inferiorly and posteriorly in the midline. The trachea divides into the two mainstem bronchi at the carina.

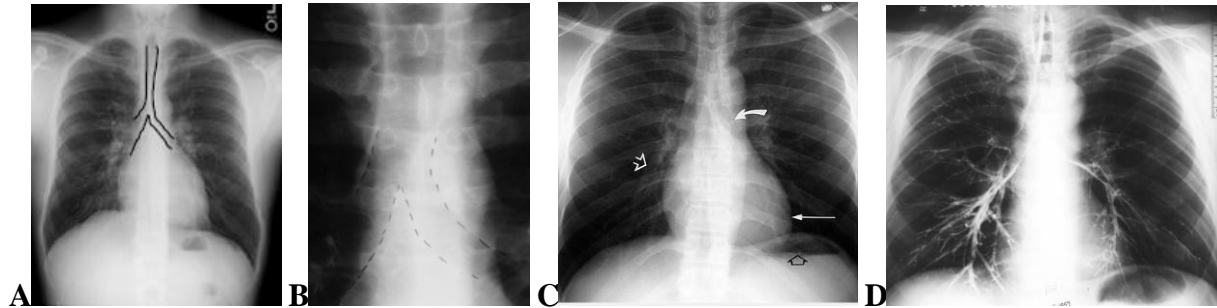


Figure 3.5 — (A-B) Marked trachea, carina and main bronchi. (C) Erect PA chest radiograph. The pulmonary arteries (white open arrow) are seen in the lung because the vessels are outlined by air in alveoli. The left cardiac border (long arrow) is crisply defined by the adjacent air-filled lung. The left main bronchus (curved arrow) is seen because its air-filled lumen is surrounded by soft tissue of the mediastinum. An air-fluid level (open black arrow) in the stomach confirms the erect position of the patient during exposure of the radiograph. (D) Normal bronchogram

Bronchi: you can see that the major bronchi are visible if you look carefully. It may be beneficial to practice drawing the bronchi and labeling them until you are entirely familiar with their names and locations.

The hila

Radiologists name as a hilus only intrapulmonary part, which is visible on X-ray plain film. The shadow of a lung hilus is caused mainly by large vessels, all the other anatomic formations are not visible under normal conditions. At research in a direct AP projection the lung hili are visible as non-homogenous shadows located on each side from mediastinum a little bit oblique to a medial line. The right hilus, as a rule, is seen well, the left hilus can be partially or completely closed by a heart shadow. On the X-ray image there are distinguished three parts of a lung hilus: the top part (head), middle part (body) and lower part (tail). The hilum is the anatomic connection of the lung to mediastinum and therefore consists of a variety of vessels, bronchi, and lymph nodes. The visible portion of each normal hilum is the right or left pulmonary artery. The pulmonary veins are inferior and posterior to the arteries.

Location of a lung hilus. Under normal conditions the image of a right lung hilus is settled between the front ends of the second and fourth ribs. If the hilus is located within these limits, such location is needed to consider as normal. If the hilus is located above or below, it means it is displaced upwards or down-

wards. The left hilus, as a rule, is located little bit above right (figure 3.6). It is necessary to take into account, that the displacement of a hilus downwards can be variant of a normal position at patients with large lungs, for example, at the sportsmen, while the displacement of a hilus upwards always specifies a presence of pathological process.

Width of a lung hilus. The patients are different under their constitution and consequently, the sizes of their lungs and other intrathoracic structures will be various. That's why there is impossible precisely to specify the width of a hilus. It is possible only to determine if the hilus is extended or is not extended. For this purpose it is necessary to measure the width of a lung artery at a level of a hilus body and to compare it to the width of a light space between an internal contour of artery and right contour of mediastinum. Under normal conditions the width of the lung artery does not exceed the width of this light space — hilus is not extended. If the artery width is more than that, this means the hilus is extended.

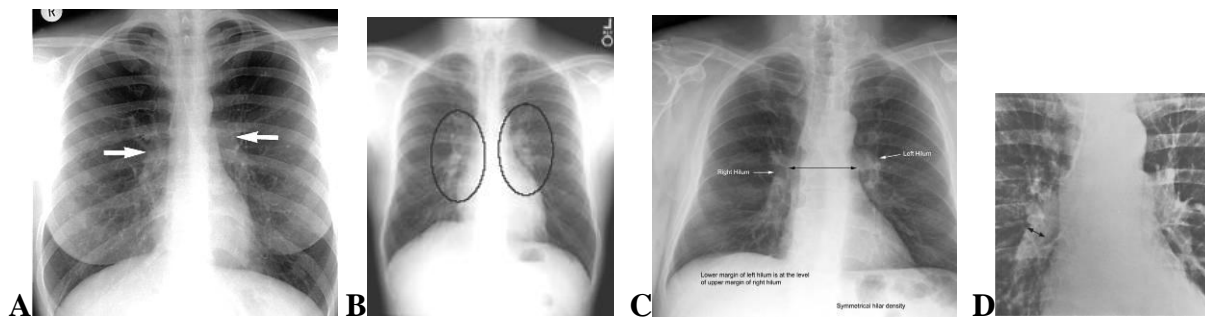


Figure 3.6 — Normal hilar anatomy. (A to C) Normal PA chest radiograph demonstrating position and density of the hilar structures. Arrows indicate the hilus points, where the superior pulmonary vein crosses the descending lower lobe artery, the left normally being level with or slightly higher than the right. (D) Frontal view of hila in plain chest radiograph. The measurement points for the diameter of the right lower lobe artery are indicated

Structure of a lung hilus. If on an X-ray film the components of a hilus: the lung artery and its branches, large veins and the light space of intermediate bronchus are well visible, their contours are clear, such structure of the hilus is normal. At many pathological processes the structure of a hilus is unclear and its image becomes indistinct.

Normal bones of chest

Ribs: the ribs are a common site for fracture or metastatic deposits but the remainder of the skeleton must also be carefully examined. Identify the first rib and carefully trace its contour from the spine to its junction with the manubrium. Each rib must be carefully and individually traced in this manner, initially for one hemithorax and then the contralateral side (figure 3.7). A useful trick is to turn the film on its side, rib fractures may then appear more obvious.

Thoracic spine: look at the thoracic spine alignment — is it straight or is there a scoliosis? Take particular care to exclude pathology from the thoracic

spine in trauma patients when even moderate malalignment can be overlooked when projected through the heart or mediastinal shadows.

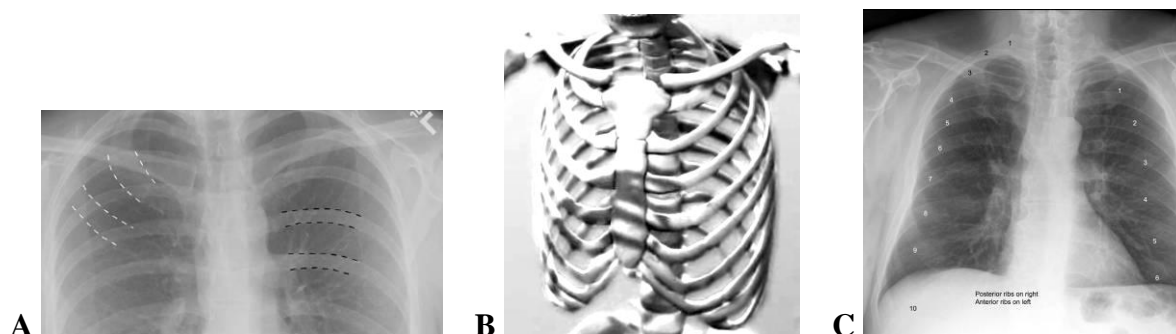


Figure 3.7 — (A) Frontal radiograph upper chest shows that the posterior ribs (outlined in black) have a horizontal course, while the anterior ribs (outlined in white) have a more sloping course as they move medially. The anterior ribs are generally not seen as well as the posterior ribs. (B) Model bones of chest. (C) Frontal radiograph chest indicate marked anterior part of the ribs (left side chest) and posterior part of the ribs (right side)

Clavicles, scapulae and humeri: fractures and dislocation of the humerus are often obvious when looked for. Look for fractures, metastatic, abnormal calcifications or evidence of arthritis around the shoulders.

The mediastinum

On the frontal film, the left and right sides of the mediastinum can be considered separately. Starting with the left side, from superior to inferiorly, the major border forming structures that should be recognized are the aorta (sometimes called the «aortic knob»), the main pulmonary artery and the left ventricle. It should also be noted that the descending aorta, though behind the heart, can usually be seen quite well on a frontal film. The right side of the mediastinum is primarily formed by the superior vena cava and the right atrium of the heart. The position of a mediastinum is defined on a relation of trachea and medial body line. Under normal condition and at exact posing of a patient during X-ray, the medial line of a body should be settled precisely in middle of the image of trachea.

The mediastinum is conventionally divided into superior, anterior, middle and posterior compartments (figure 3.8). The exact anatomical boundaries of these divisions are unimportant to the radiologist (indeed they vary according to different authors), since they do not provide a clear-cut guide to disease and no do their boundaries form any barriers to the spread of the disease.

Diaphragm and soft tissue of the chest

In most individuals, the diaphragm has a smooth domed shape, but a scalloped outline is also common. The angle of contact with the chest wall is acute and sharp, but blunting of this angle can be normal in athletes, because they can depress their diaphragm to a remarkable degree on deep inspiration. The normal

right hemidiaphragm is found at about the level of the anterior portion of the sixth rib, with a range of approximately one interspace above or below this level. In most people, the right hemidiaphragm is 1.5–2.5 cm higher than the left, but the two hemidiaphragms are at the same level in some 9 % of the population. In a few normal individuals the left hemidiaphragm is up to 1 cm higher than the right. The normal excursion of the diaphragm is usually between 1.5 and 2.5 cm.

A visual examination should be routinely performed on the chest wall, the neck and both the breast shadows. Look for emphysema and abnormal calcification. With reference to the breast shadows be sure to check whether there are two breast shadows and whether there is symmetry of size, shape and position. The lung field missing a breast will appear a little darker than the other side.

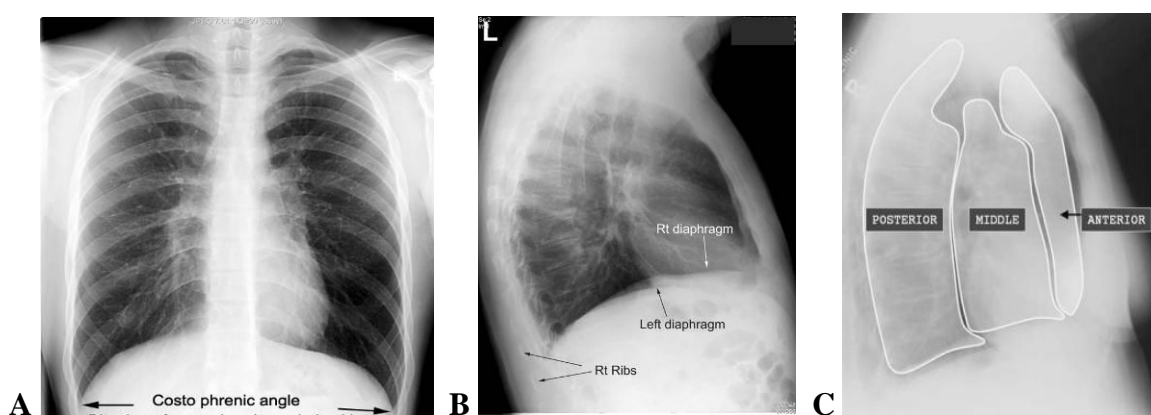


Figure 3.8 — (A) Normal frontal and (B) lateral radiograph of the chest. Check the shape, position and clarity/sharpness of both hemidiaphragms. Both costophrenic angles should be clear and sharp. The cardiophrenic angles should be fairly clear — cardio-phrenic fat pads can cause added density. The right hemidiaphragm is usually slightly higher than the left — up to 1.5 cm. On the lateral film, the right hemidiaphragm is seen in its entirety but the anterior aspect of the left hemidiaphragm merges with the heart, so is not seen. White arrows Rt, black arrows Lt. (C) Diagram of mediastinal compartments as defined on lateral view

The important review area in terms of soft tissue include below the diaphragms, the periphery of the chest wall, the supraclavicular region, and neck as far as included on the chest film.

Order of visual scan. How to read a chest radiograph

Reading a chest X-ray requires a methodical approach that can be applied to all films so that abnormalities are not overlooked. Clinicians and radiologists develop an individual approach but there are certain core areas that should be looked at on all films. These may be inspected in any order – this is largely down to personal preference. Being able to recognize normal appearances and structures as seen on a chest X-ray (CXR) is key to being able to correctly interpret any abnormal findings. In order to do this, you must first understand why we are able to

see structures such as the heart border and the ribs as separate entities to surrounding tissues (figure 3.9).

Systematic analysis

The doctor inspecting a chest film should try to examine it in a systematic manner. The very first thing to be done is the correct placing of the film on a viewing box — the right side of the film is to be placed on the left side of the viewing box, as if a patient is standing face-to-face to the doctor. If there is a side film then it is to be placed on a correct side according to a notice on a film itself. Verify the patient's identity. In examination situations look at the name, if present, as this can give a clue to sex and ethnic background. The date and hospital where the film was taken give further clues. If a film has been taken at a centre for oncology or chest medicine, for instance, this may help with interpretation.

Radiographic report

1. Quality of radiograph (x-ray film) of the chest.
 - A. Penetration (the vertebral bodies should just be visible through the cardiac silhouette).
 - B. Rotation (the medial aspect of the clavicles should be symmetrically positioned on either side of the spine).
 - C. Inspiration (the diaphragm should lie at the level of the sixth or seventh rib anteriorly).
2. Review soft tissues (including breast) and chest wall.
3. Review bones spine and rib cage: lesions or fractures, lytic or blastic regions, disc space narrowing, etc.
4. Review lungs and pleura:
 - A. Compare lung field sizes, lung parenchyma, do not forget that the lungs extend below the diaphragms.
 - B. Evaluate pulmonary vascular pattern: compare upper to lower lobe, right to left, normal tapering to periphery, artery or vein enlargement.
Pleural surfaces: fissures — major and minor (if seen), compare hemidiaphragms.
- C. Review hila: size, assess position and density.
5. Review mediastinum:
 - A. Overall size and shape, mediastinal contour (width? mass?).
 - B. Trachea: position, midline or deviated, caliber.
 - C. Margins: aortic arch, aorta, main pulmonary arteries, left ventricle.
 - D. Retrosternal clear space (if lateral view).
6. Conclusion (diagnosis).

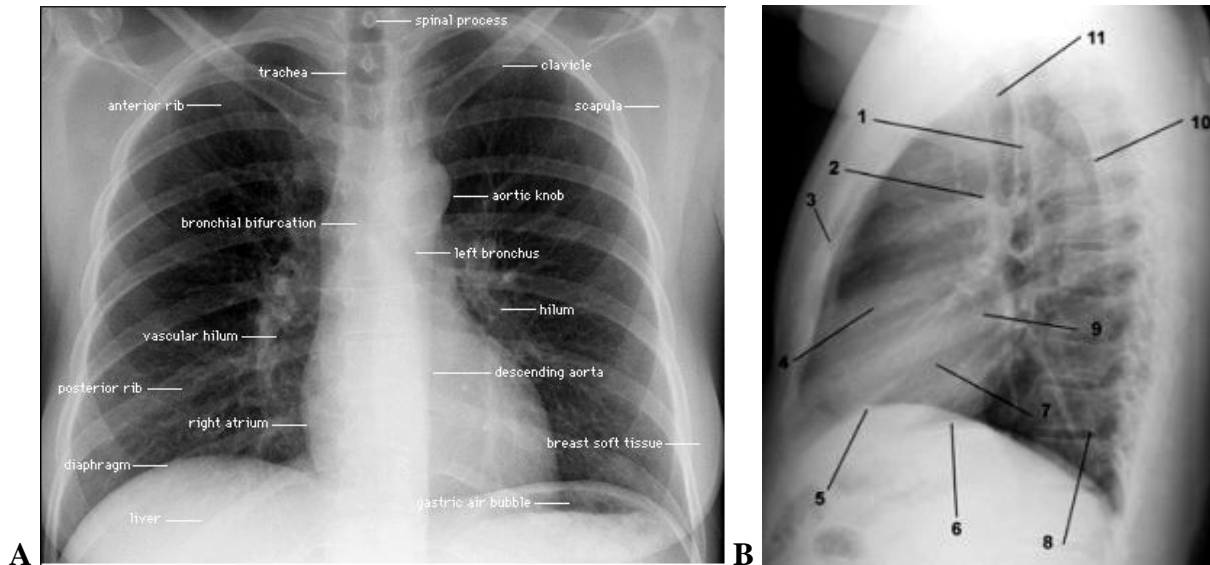


Figure 3.9 — (A) Frontal and (B) lateral radiograph chest indicate marketed of roentgen anatomic structures. (B) 1 — Trachea. 2 — Aortopulmonary window. 3 — Sternum. 4 — Right ventricle. 5 — Right hemidiaphragm. 6 — Left hemidiaphragm. 7 — Left ventricle. 8 — Posterior recess of vertebra. 9 — Left atrium. 10 — Scapula. 11 — Lung field apex

Sample of the protocol — the description of normal radiograph chest (short form)

On the plain film of a chest, performed in a AP view there is determined: the chest skeleton doesn't show pathological changes. Lung fields have the usual shape and sizes. The lung fields transparency is not changed, there are no focal and infiltrative shadows. Lung pattern is not changed, is clearly traced in all parts of lungs. The lung hila are normally located, not extended, structure of them is normal. The mediastinum is not displaced. The diaphragm is located normally, the sinuses are free. The conclusion: pathological changes of the chest organs are not revealed.

You can summarise your findings in a few sentences: «This is a frontal chest radiograph of a young male patient. The patient has taken a good inspiration and is not rotated; the film is well penetrated. The trachea is central, the mediastinum is not displaced. The mediastinal contours and hila seem normal. The lungs seem clear, with no pneumothorax. There is no free air under the diaphragm. The bones and soft tissues seem normal».

Any cases you can summarise all the above information in a simple opening phrase: «The lungs, bones and soft tissues of the chest — variant of norm».

Radiographic findings in lung disease (pathologic considerations)

Each tissue reacts to injury in a predictable fashion. Multiple etiology can evoke a similar pathological reaction. Let us just examine the pathological process that can occur in the lung. Lung injury or pathological states can be either a gene-

ralized or localized process. In order for us to recognize these pathological process in chest x-ray first we need to have good understanding of pathology.

Most of the disease states replace air with a pathological process which usually is a liquid density and appears white. Having a proper understanding of each of the pathological process or lung injury patterns is essential. Then we can develop roentgen signs that help us identify the nature of the pathological process.

Six *basic pathologic patterns* may alter the normal appearance of the lungs. The six abnormalities are as follows:

- Air space disease — consolidation.
- Interstitial changes — fibrosis and/or edema.
- Atelectasis — collapse.
- Pleural fluid accumulation — effusion.
- Emphysema — overinflation.
- Masses — tumors and tumor-like abnormalities.

Consolidative radiological findings

Consolidation is a commonly found abnormality on a chest X-ray and its correct interpretation is of relevance to the patient. Consolidation is also sometimes referred to as alveolar opacification or air space opacity.

Consolidation is the presence of a substance within the alveoli that displaces normal air. This results in a relative increase in radio-density of the affected area. These are fluid, cellular material (inflammatory or malignant cells), aspirated material, proteinaceous material, and blood. Consolidation is a non-specific finding. Radiological characteristics include:

- Opacification (shadowing).
- Lobar/segmental distribution.
- No significant loss of lung volume.

Consolidation is defined as alveolar space that contains the fluid instead of air, it is a filling of the alveolar spaces with a fluid. Consolidation it is air space opacities that often indicate pneumonia.

In pneumonia, consolidation results when an infected lung passes from an aerated collapsible condition to one of airless solid consistency through the accumulation of exudates in the alveoli and adjoining ducts. The fluid can be pulmonary edema, inflammatory exudates, pus, inhaled water, or blood.

Consolidative radiological signs include:

- Fluffy, cloud-like, coalescent opacities.
- Complete air bronchograms seen through the opacity.
- Obliterates pulmonary vasculature.
- There can be sharp edges when limited by fissures or pleura.

Consolidation may be mimicked by alveolar collapse, as in an airway obstruction.

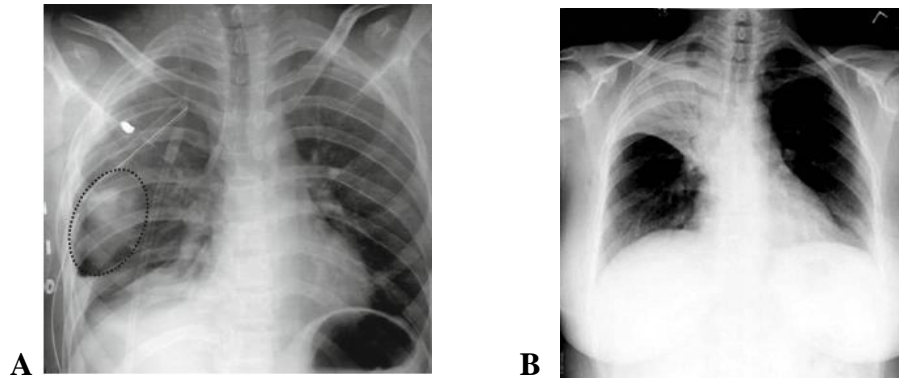


Figure 3.10 — (A) Consolidation representing hemorrhage (density highlighted by dotted oval). Additionally noted is chest tubes and blast metal fragment. (B) Right upper lobe consolidation. There is opacification of the RUL zone. A key feature is that there is no loss of volume. There is no mediastinal shift and no fluid level

As you may have gathered consolidation (air space opacity) is a rather non-specific finding and can represent the effect of a large number of pathological processes (figure 3.10). Having identified air space opacity, it is important to review the remaining film to see if there are any ancillary features that would help in establishing the underlying cause.

Pneumonia

Parenchymal lung disease can be divided into those processes that produce an abnormal increase in the density of all or a portion of the lung on chest radiographs (pulmonary opacity, shadow) and those that produce an abnormal decrease in lung density (pulmonary lucency) (figure 3.11). The normal density of the lungs is a result of the relative proportion of air to soft tissue (blood or parenchyma) in a ratio of 11 to 1.

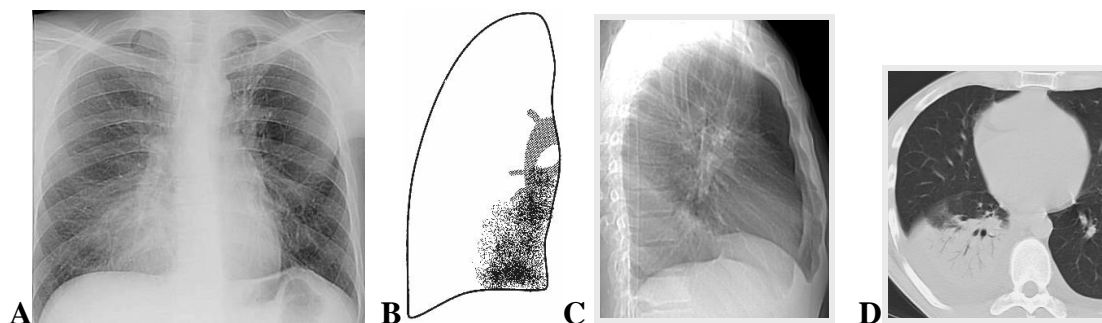


Figure 3.11 — (A) Frontal CRX, (B) scheme to (A), (C) lateral CXR and (D) axial CT tomogram shows a focal shadow in the right lower lobe. There is opacification within the lower zone of the right lung field. In the given example there is loss of definition of the right heart border. From this you can work out where the consolidation is located. The right middle lobe (which is normally air filled) is adjacent to the right atrium. This is why you normally see the margin of the right atrium. The consolidation within the right middle lobe causes loss of the air/soft tissue interface and hence loss of definition of the border

Infection via the tracheobronchial tree is generally secondary to inhalation or aspiration of infectious microorganisms and can be divided into three subtypes based on gross pathologic appearance and radiographic patterns: lobar pneumonia, lobular or bronchopneumonia, and interstitial pneumonia.

Lobar pneumonia is typical of pneumococcal pulmonary infection. In this pattern of disease, the inflammatory exudate begins within the distal airspaces. The inflammatory process spreads to produce nonsegmental consolidation. If untreated, the inflammation may eventually involve an entire lobe (figure 3.12–3.14). Because the airways are usually spared, air bronchograms are common and significant volume loss is unusual.

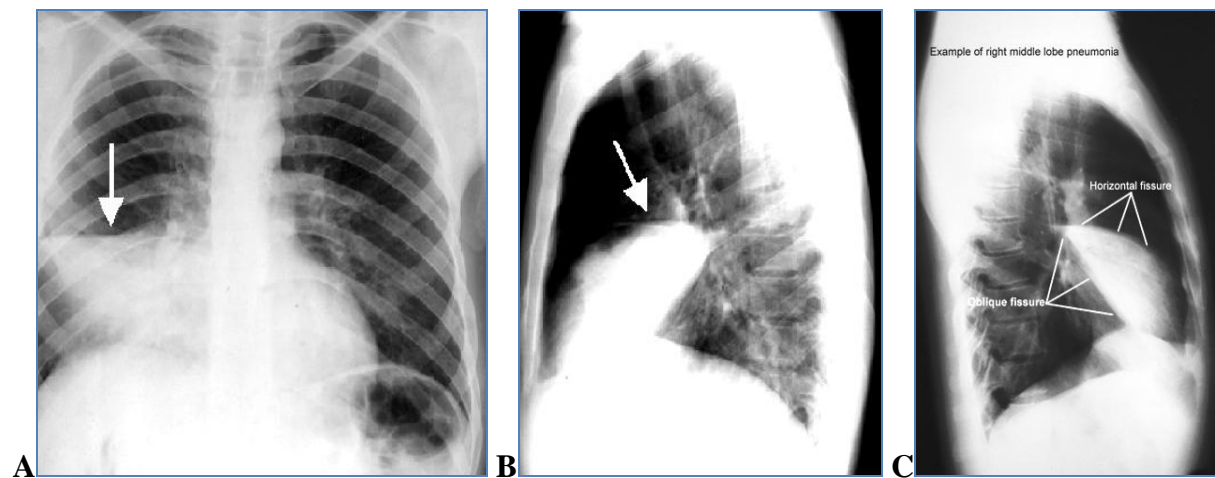


Figure 3.12 — Pneumonia. (A) PA and (B to C) lateral projections of right middle lobe consolidation. Frontal chest radiograph demonstrates obliteration of the right borders of the heart. Patchy, diffuse air-space acute lobar consolidation, infiltrate with a focal area of consolidation in the right middle lobe (arrow)

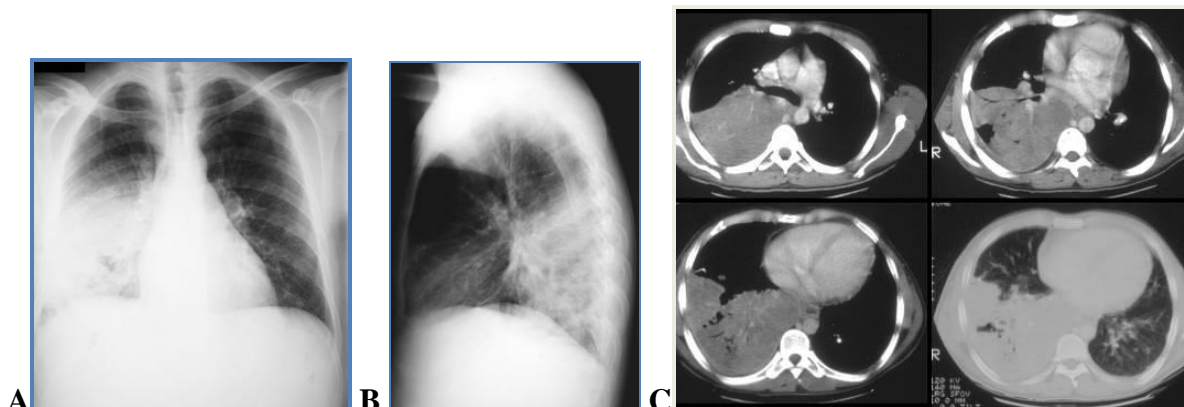


Figure 3.13 — Pneumonia. (A) Frontal chest radiograph, (B) lateral film and (C) CT scans demonstrates a middle lobe airspace opacification with areas of cavitation

Bronchopneumonia is the most common pattern of disease and is most typical of staphylococcal pneumonia. In the early stages of bronchopneumonia, the inflammation is centered primarily in and around lobular bronchi. As the inflammation progresses, exudative fluid extends peripherally along the bronchus

to involve the entire pulmonary lobule. While bronchopneumonia is the most common cause of multifocal patchy airspace opacities, there is a broad list of differential diagnostic considerations. Exudate within the bronchi accounts for the absence of air bronchograms in bronchopneumonia. With coalescence of affected areas, the pattern may resemble lobar pneumonia.

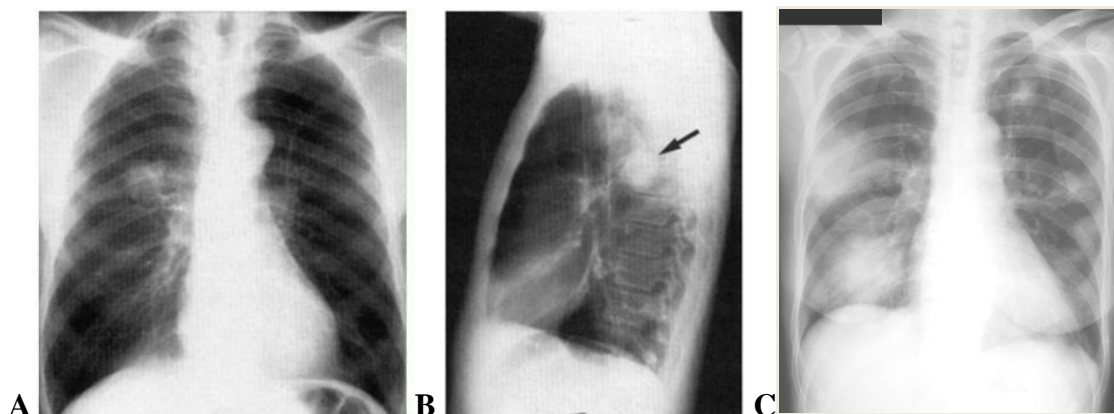


Figure 3.14 — Round pneumonia. Well-defined round mass (arrow) in the right mid-lung in (A) posteroanterior and (B) lateral chest radiographs. (C) Legionnaire's disease. «Spherical» pneumonia with a nodular and focus areas of infiltrate. Frontal view of the radiograph chest shows a rounded soft-tissue density of both lung fields with mild bilateral hilar prominence

Interstitial pattern

In interstitial pneumonia, seen in viral and mycoplasma infection, there is inflammatory thickening of bronchial and bronchiolar walls and the pulmonary interstitium (figure 3.15). This results in a radiographic pattern of airways thickening and reticulonodular opacities. Air bronchograms are absent because the alveolar spaces remain aerated. Segmental and subsegmental atelectasis from small airways obstruction is common.

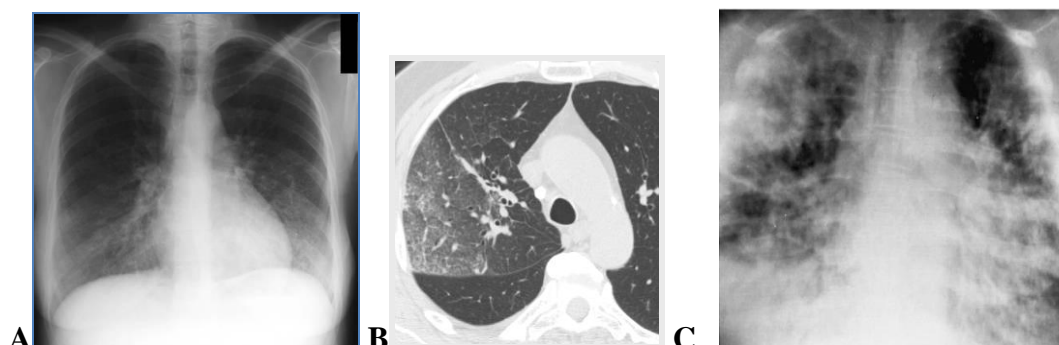


Figure 3.15 — (A to B) Frontal chest radiograph and CT-tomogram an axial a plane same patient. Loss normal lung architecture with interstitial markings and increased pulmonary vascular patterns. (C) Viral pneumonia. Diffuse peribronchial infiltrate with associated air-space consolidation obscures the heart border (shaggy heart sign). A patchy alveolar infiltrate is present in the right upper lung field

The hallmark of the interstitial pattern is the presence of linear and irregular shadows. Unlike the patterns of alveolar flooding and atelectasis, the interstitial pattern is often subtle and may be difficult to distinguish from normal in some patients because the lines are mistaken for vessels. Look at the pattern of the lines and decide if you are simply looking at vessels or if there are too many lines and the pattern is too irregular to represent normal vessels only. Figure 3.16 shows a patient with a viral pneumonia presenting with an interstitial pattern.

The interstitial pattern includes many categories of diseases and there are several subsets of the interstitial pattern. A typical pattern, such as the one shown in the above case, is commonly seen in patients with «interstitial» pneumonias (classically viral pneumonias and mycoplasma pneumonia).

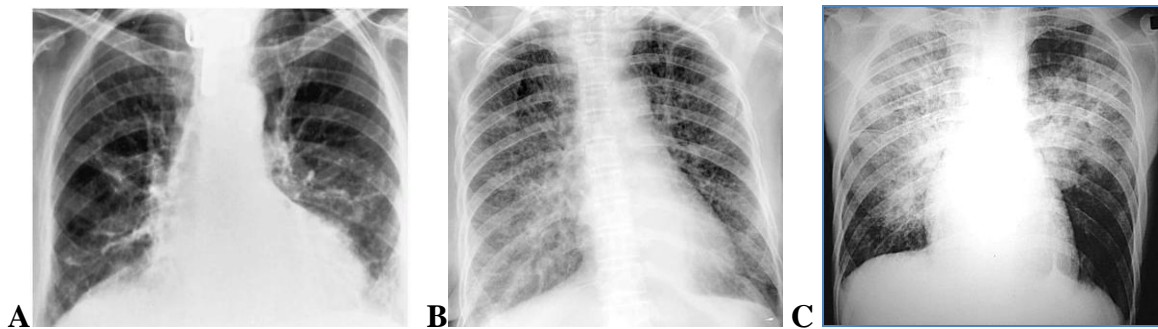


Figure 3.16 — (A to B) Interstitial pneumonia. Notice the excessive number of linear and irregular shadows throughout the film. In subtle cases it may difficult to distinguish the increased linear prominence from normal vessels. (C) Pulmonary edema in congestive heart failure. Diffuse, coarse reticulonodular pattern. Chest radiograph demonstrates a paucity of vascular markings along with increased interstitial markings elsewhere. With the onset of congestive heart failure, there is patchy interstitial and alveolar edema that does not affect the segments in which the vascularity had been severely diminished. Diffuse bilateral symmetric infiltration of the central portion of the lungs along with relative sparing of the periphery produces the butterfly, or bat's wing, pattern

Atelectasis (collapse)

The term atelectasis (collapse of small peripheral airways and alveoli) means incomplete expansion of the lungs. To make the diagnosis of atelectasis requires evidence of volume loss. Lobar consolidation may have similar appearances. A common cause of atelectasis is pneumonia. Radiological characteristics includes:

1. Opacity (shadow, airless lung).
2. Signs of loss of lung volume:
 - mediastinal shift;
 - elevated hemidiaphragm;
 - movement of fissures;
 - shift of hilum;
 - change of proportion of lungs;
 - smaller hemithorax.

3. Compensatory hyperinflation.
4. Vessel asymmetry.
5. Fissure appears as an edge (figure 3.17–3.18).

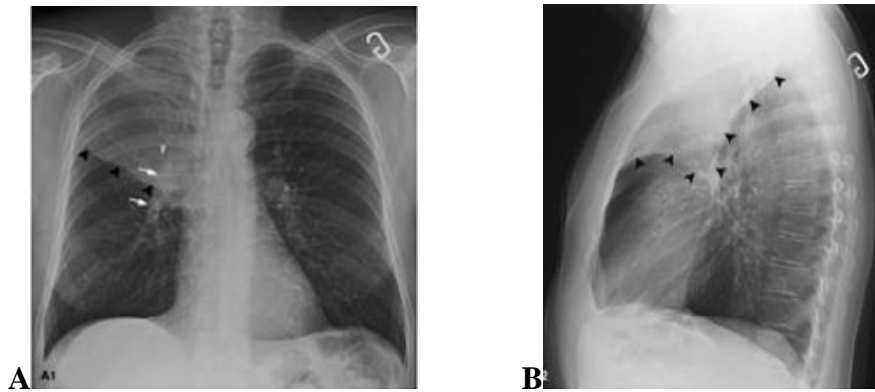


Figure 3.17 — Atelectasis of the right upper lobe (A to B) from bronchopneumonia. Increased shadowing (opacity) in the right upper zone with a clear linear border (black heads) of the horizontal fissure. The volume RUL loss is evident because of the increased opacity as well as (B) elevation of the minor fissure and elevation of right hilum (white arrows)

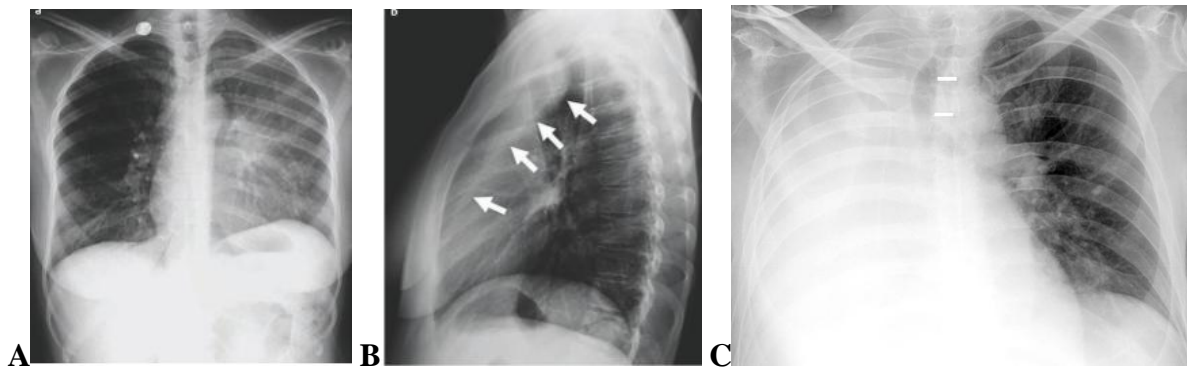


Figure 3.18 — (A) The opacity seen on the CXR obliterates the interface between the left heart and the left lung — which means that it is located in the upper lobe. It demonstrates a homogeneous internal structure indicating that it is airless and it shows associated volume loss in the affected lung (the left hemidiaphragm is elevated, decreased volume of left lung). (B) The lateral view confirms a dense stripe retrosternally (arrows) due to oblique fissure. Increased shadowing in the left upper and mid zone lung field due to left upper lobe which has collapsed upwards and anteriorly. This is compatible with left upper lobe collapse (complete lobar atelectasis). (C) Total atelectasis of the right lung. Notice the shift (white lines) of the trachea toward the affected side, loss of right lung volume

Lung collapse or atelectasis can affect the whole lung, a single lobe or a segmental component. The lobar collapses are important not to miss on imaging. Atelectasis literally means incomplete expansion or loss of volume.

Abscess

Abscesses can often be well defined on chest X-rays as they have relatively thick walls (figure 3.19-3.20). Note the presence of an air fluid level. The abscess

itself may be a result of a malignant process and so it is important to ensure that follow-up occurs. Abscess characteristics includes:

- Cavitating infective consolidation.
- Single or multiple lesions.
- Bacterial or fungal pathogens are the most common causative organisms.
- Associated with aspiration and/or impaired local or systemic immune response (epileptics, diabetics, etc.).

Radiological features includes:

- Most commonly occur in the apicoposterior aspect of the upper lobes.
- A cavitating spherical area of consolidation an air-fluid level present.

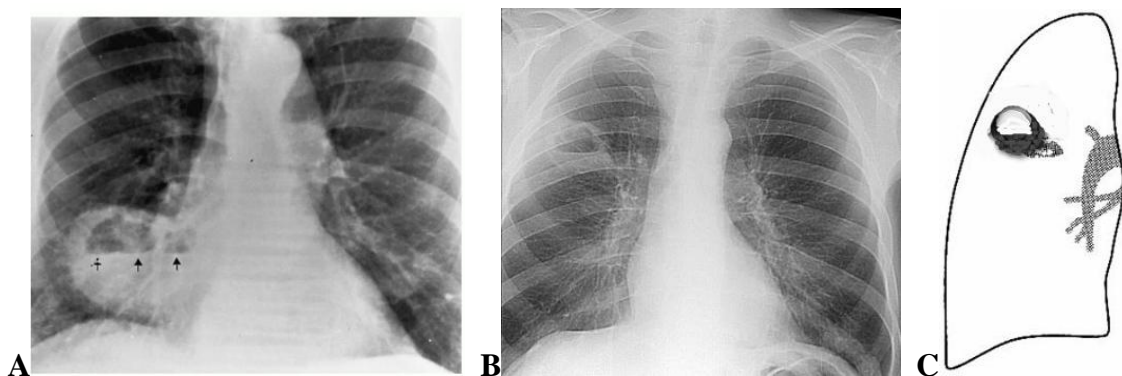


Figure 3.19 — (A) Acute lung abscess. Large right middle lobe abscess containing an air-fluid level (arrows) in an intravenous drug abuser. (B) Abscess right lung. (C) Scheme to B.

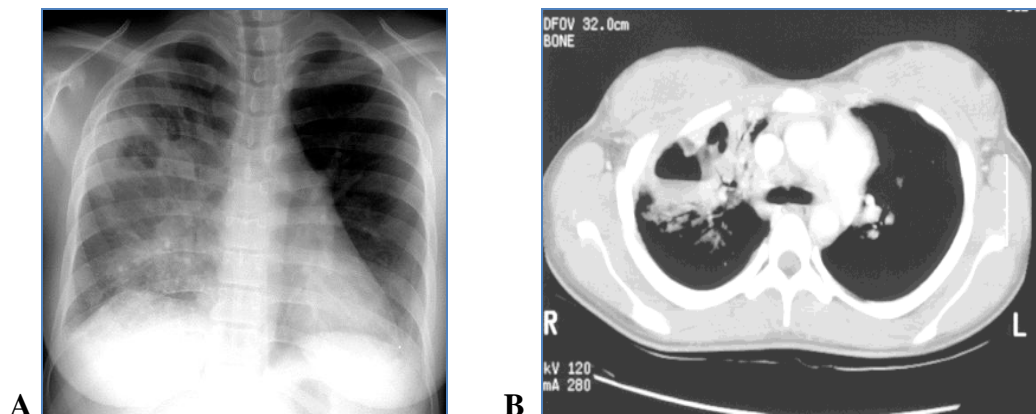


Figure 3.20 — Klebsiella pneumonia complicated by an abscesses. (A) Frontal chest radiograph with air-space consolidation involving much of the right upper lobe. (B) Progression of the necrotizing infection produces a large abscess cavities with an air-fluid level within the upper zone of the right lung field

Cavities form when a pulmonary mass undergoes necrosis and communicates with an airway, leading to gas within its center. The wall of a cavity is usually irregular or lobulated and, by definition, is greater than 1 mm thick. Lung abscess and necrotic neoplasm are the most common cavitary pulmonary lesions.

Pleural abnormalities

Pleural abnormalities are a common finding on chest X-ray, the significance of which varies from trivial to marked. Typical areas to identify pleural abnormalities are at the costophrenic and cardiophrenic angles, the apices, and the peripheral outline of both lungs. Abnormalities involving the pleura include pathologic processes (masses, calcifications, infections, thickening) of the pleura, in addition to fluid and air collections within the pleural space. Three main categories of pleural abnormalities are seen: effusions, pleural thickening or calcification, and pneumothoraces.

Fluid in space between the lung and the chest wall is termed a pleural effusion. There needs to be at least 75 ml of pleural fluid in order to blunt the costophrenic angle on the lateral chest radiograph, and 200 ml on the posteroanterior chest radiograph. On a lateral decubitus, amounts as small as 5 ml of fluid are possible.

Pleural effusion definition: fluid in the potential space between the parietal and visceral pleura. The radiographic appearance of pleural effusions depends upon the amount of fluid present, the patient's position during the radiographic examination, and the presence or absence of adhesions between the visceral and parietal pleura. Small amounts of pleural fluid initially collect between the lower lobe and diaphragm in a subpulmonic location. As more fluid accumulates, it spills into the posterior and lateral costophrenic sulci. A moderate amount of pleural fluid (> 175 mL) in the erect patient will have a characteristic appearance on the frontal radiograph, with a homogeneous lower zone opacity seen in the lateral costophrenic sulcus with a concave interface toward the lung. This concave margin, known as a pleural meniscus, appears higher laterally than medially on frontal radiographs because the lateral aspect of the effusion, which surrounds the costal surface of the lung, is tangent to the frontal x-ray beam. Similarly, the meniscus of pleural fluid as seen on lateral radiographs peaks anteriorly and posteriorly. This usually results in obliteration part or all of the hemidiaphragms (silhouette sign), blunting of the costophrenic angles both peripherally on the frontal projection and posteriorly on the lateral. Radiological characteristics includes:

- loss of costophrenic angle.
- loss of diaphragmatic shadow.
- homogenous opacification.
- shift of mediastinum to opposite side with large effusions.
- ellips line (meniscus high in axilla).

Pleural effusions typically have a meniscus visible on an erect chest radiograph, but loculated effusions (as occur with an empyema) may have a lenticular shape (the fluid making an obtuse angle with the chest wall) (figure 3.21–3.22).

Pleural thickening may cause blunting of the costophrenic angle, but is distinguished from pleural fluid by the fact that it occurs as a linear shadow ascending vertically and clinging to the ribs.

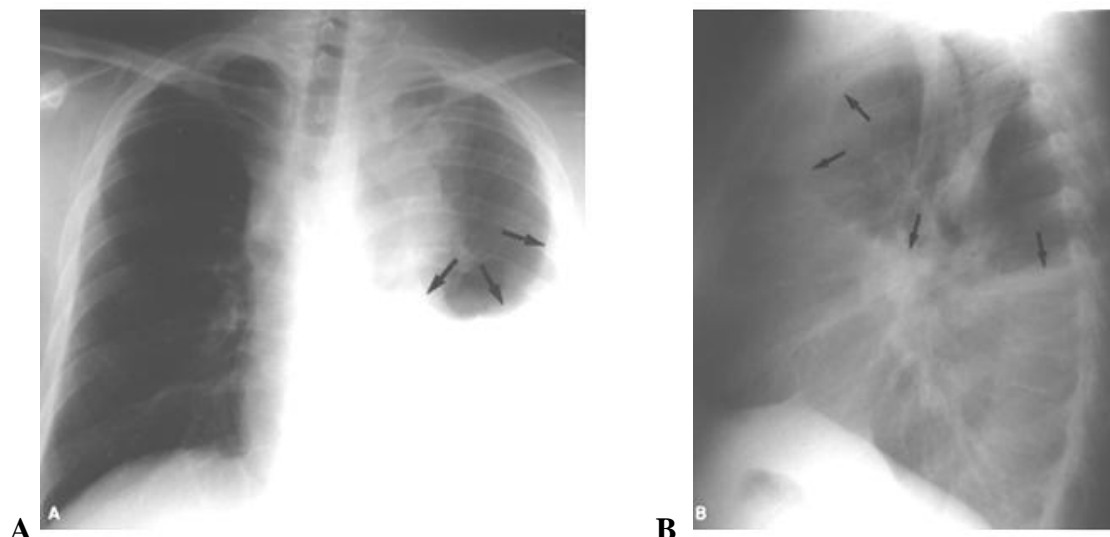


Figure 3.21 — Right pleural effusion on frontal chest radiographs. (A) Posteroanterior and lateral (B) chest radiographs demonstrate the typical homogenous shadow, non-visualization of left hemidiaphragm and costophrenic angle, and meniscoid appearance (arrows) in a patient with a left moderate pleural effusion. There is opacification of the lower right hemithorax with a fluid level, and the mediastinum is pushed to the left side. Note the a laterally placed meniscus, and loss of clarity of the lung and outline of the hemi-diaphragm

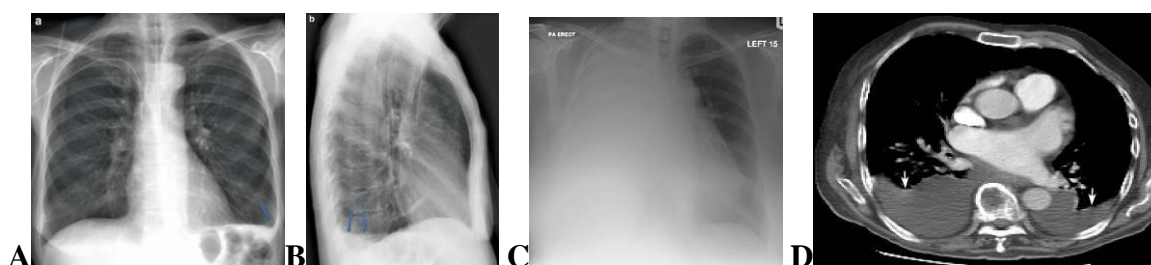


Figure 3.22 — PA (A) and lateral (B) erect projections of the chest demonstrate blunting of left costophrenic angle with a meniscus peripherally on the PA and posteriorly on the lateral (arrows) at limited exudative pleurisy. (C) Radiograph of chest frontal projection, large right pleural effusion. Note the mediastinal shift away from the effusion. (D) Pleural effusion on CT. CT is done in the supine position. Fluid settles in the dependent portion in the back of chest. The white arrows point to bilateral pleural effusions

Pneumothorax

Pneumothorax results from air entering the pleural space and may be traumatic or spontaneous. Spontaneous pneumothorax is further subdivided into a primary form, which has no identifiable etiology, and a secondary form, which is associated with underlying parenchymal lung disease. Radiological characteristics includes a) dark field with no vascular markings in the pleural space; b) visible collapsed lung, c) may be larger hemithorax (figure 3.23–3.24).

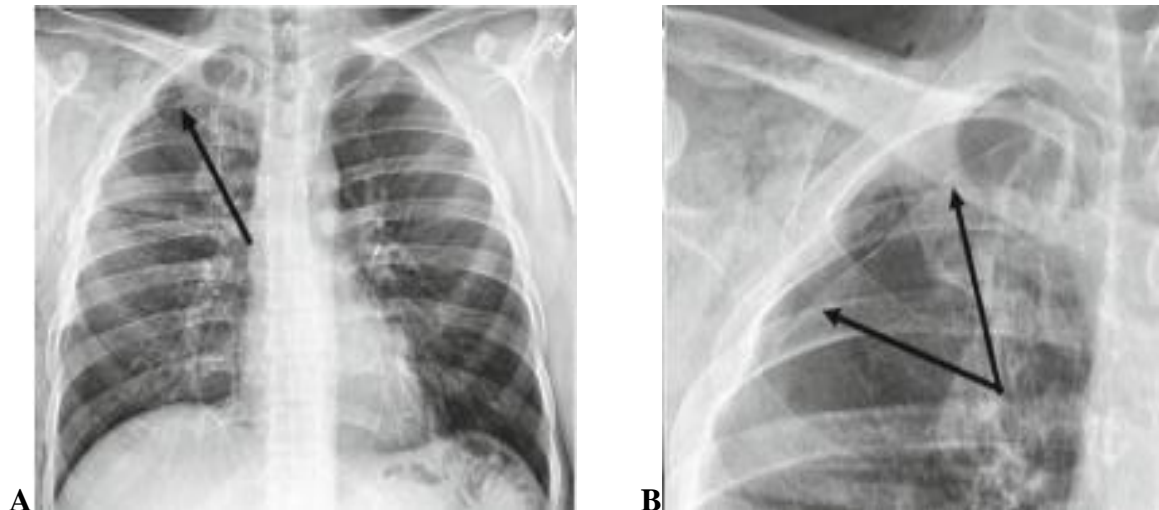


Figure 3.23 — Pneumothorax. (A) Frontal chest radiograph. (B) Spot film of right side chest. Note how the edge of the collapsed right lung is delineated by a sharply demarcated thin white line (arrows), the visceral pleura, beyond which no pulmonary markings are identified (best seen on close up image on right)

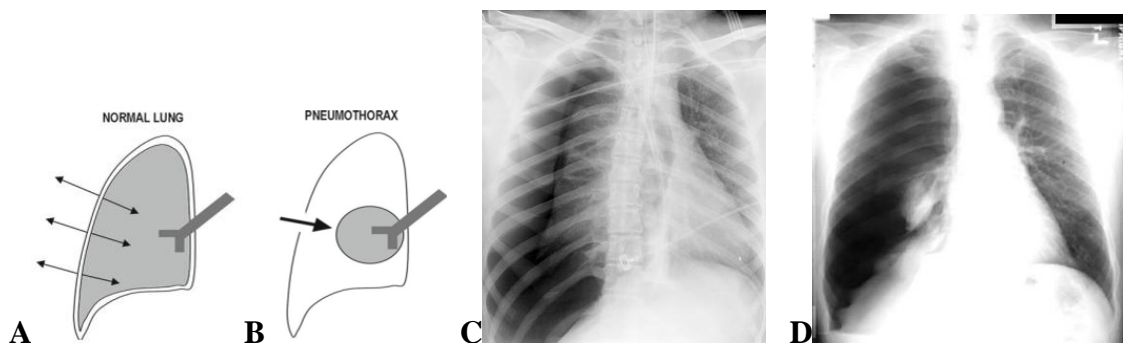


Figure 3.24 — Diagrams (A) the normal elastic forces between the chest wall and the lung oppose each other, (B) resulting in a certain equilibrium as noted in the picture on the pneumothorax. With a pneumothorax, when the chest wall is compromised, air enters the thorax, allowing the lung to collapse. (C) Very large pneumothorax on the right side. The right lung relaxes to its resting state. Increased lucency of the right hemithorax with leftward mediastinal shift, widening of the right intercostal spaces and inferior displacement of the right hemidiaphragm, consistent with a right pneumothorax. The right side of the lung is blacker, and the lung edge is seen. Right pneumothorax pushing mediastinum to the left. (D) This frontal chest radiograph reveals complete collapse of the right lung due to a massive right pneumothorax. The right lung is almost completely compressed by the pneumothorax

Hydropneumothorax

Hydropneumothorax (or hemopneumothorax) is a combination of pleural fluid and pneumothorax. A straight air-fluid level, differentiates this entity from pleural effusion without pneumothorax (figure 3.25). Effusions without pneumothorax have a meniscus as we have seen.

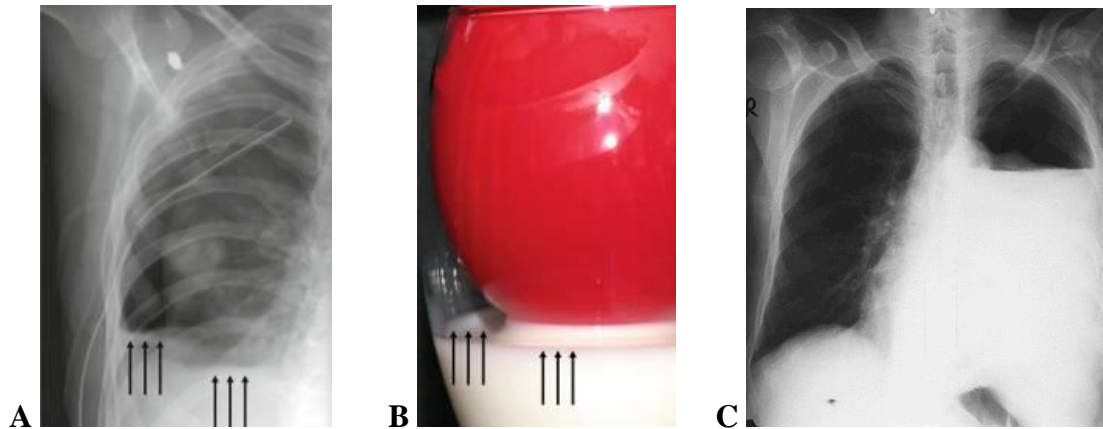


Figure 3.25 — (A) Note similarity with actual hydro-pneumothorax. The arrows demonstrate how fluid level can be perceived in several layers. (B) Balloon analog showing milk layer and partially filled balloon (lung) (representing an erect projection). (C) Frontal chest radiograph, left side large hydro-pneumothorax pushing mediastinum to the right

Emphysema

Chronic obstructive pulmonary disease is not truly a disease but a group of diseases — chronic bronchitis, small airways disease (obstructive bronchiolitis), and destruction of the lung parenchyma (emphysema). Pulmonary emphysema is defined as abnormal, permanent enlargement of airspaces distal to terminal bronchioles, accompanied by the destruction of airspace walls without obvious fibrosis. The most prominent radiographic findings result from lung overinflation (dark lungs), manifesting as:

- avascularity of lung fields;
- increased pulmonary radiolucency and a bilaterally flat;
- increased AP diameter of chest and lung field;
- depressed hemidiaphragm (below the anterior portion of the seventh rib or the posterior portion of the tenth rib), low flat diaphragms,
- increased retrosternal space (> 4.5 cm on the lateral film measured from a point 3 cm below the sternal angle);
- increased infracardial space;
- vertical heart;
- accentuated kyphosis;
- increased intercostal spaces.

The number of vessels is decreased in emphysemic tissue. The central pulmonary arteries are more prominent and appear truncated peripherally. Increased prominence of the interstitial markings is often present. Bullae may appear as radiolucent air sacs in the periphery of the apex or base of the lungs. Only moderate to severe forms of emphysema are detectable on plain film radiography (figure 3.26).

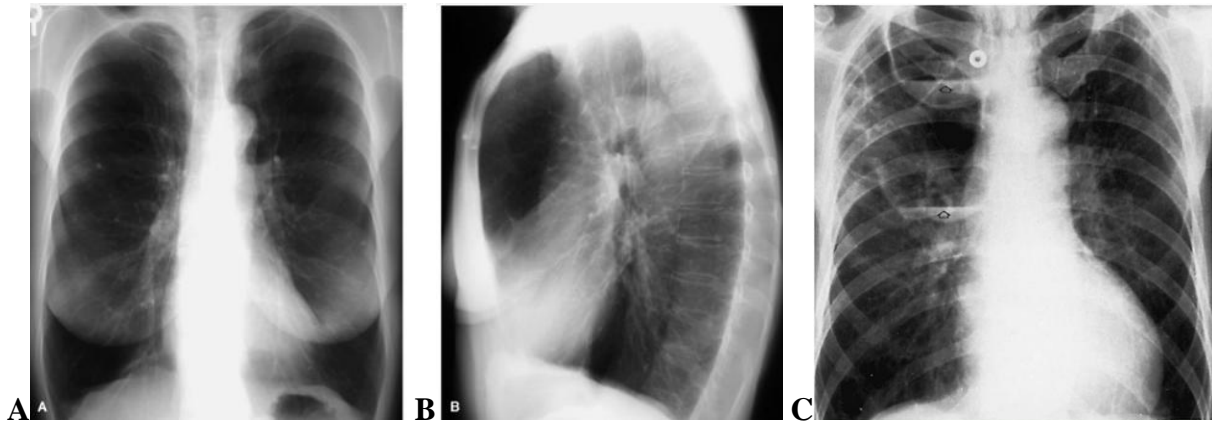


Figure 3.26 — (A) Posteroanterior and (B) lateral chest radiographs with emphysema shows hyperinflation with hyperlucency, overexpanded lungs, narrow mediastinum, upper lobe vascular attenuation, flattening of the diaphragms, and an increased retrosternal airspace, reflecting severe bilateral lungs emphysema. (C) Pulmonary emphysema.

Large bullae in the right upper lung. The presence of air-fluid levels (arrows) in the cystic spaces indicates superimposed infection

A bulla is a gas collection within the pulmonary parenchyma that is >1 cm in diameter and has a thin wall < 1 mm thick. It represents a focal area of parenchymal destruction (emphysema) and may contain fibrous strands, residual blood vessels, or alveolar septa. An air cyst is any well-circumscribed intrapulmonary gas collection with a smooth thin wall > 1 mm thick. While some of these lesions will have a true epithelial lining (bronchogenic cyst that communicates with a bronchus), most do not and likely represent postinflammatory or posttraumatic lesions. A bleb is a collection of gas < 1 cm in size within the layers of the visceral pleura. It is usually found in the apical portion of the lung. These small gas collections are not seen on plain radiographs but may be visualized on chest CT, where they are indistinguishable from paraseptal emphysema. Rupture of an apical bleb can lead to spontaneous pneumothorax. Pneumatocoles are thin-walled, gas-containing structures that represent distended airspaces distal to a check-valve obstruction of a bronchus or bronchiole, most commonly secondary to staphylococcal pneumonia. A traumatic air cyst results from pulmonary laceration following blunt trauma. These lesions generally resolve within 4 to 6 months. Bronchiectatic cysts are usually multiple, rounded, thin-walled lucencies found in clusters in the lower lobes, and represent saccular dilatations of airways in varicose or cystic bronchiectasis.

Abnormal lucency of the lung may be localized or diffuse. Focal radiolucent lesions of the lung include cavities, cysts, bullae, blebs, and pneumatocoles. These lesions are usually recognized by identification of the wall that marginates the lucent lesion.

Tuberculosis (TB)

Tuberculosis has various manifestations in the lung. In primary tuberculosis there is a peripheral lung mass (Ghon focus) with enlarged hilar lymph nodes.

Consolidation can also occur. In secondary tuberculosis there is patchy consolidation especially in the upper lobes. This can cavitate. Other manifestations include pleural effusions and miliary tuberculosis. Mediastinal lymphadenopathy does not occur in secondary TB. Other infections can cavitate, including pneumonias due to *Staphylococcus*, *Klebsiella*, and *Cryptococcus*. *Pneumocystis carinii*, as the name suggests, can form cysts which are air-filled and have a similar appearance on an x-ray film to cavities.

Tuberculosis (characteristics):

- *Mycobacterium tuberculosis* (TB) is an aerobic bacillus.
- High cause of morbidity and mortality worldwide.
- Susceptible groups include immunocompromised, elderly, alcoholics and immigrants from third world countries.
- TB predominately affects the lungs but spread via lymphatics and blood vessels allows dissemination to other organs (pericardium, gastrointestinal and genitourinary tracts, bone and the CNS).

— Three main types of pulmonary tuberculosis infection:

- Primary.
- Post primary or reactivation.
- Miliary.
- A tuberculoma represents a focal mass lesion of uncertain tuberculous infective activity.

Radiological features (chest x-ray) includes:

- Primary.
- May be active or inactive infection.
- Scarring and calcification (lung and lymph nodes) suggest inactive disease.
- Consolidation, small focal nodularity, lymphadenopathy and effusions suggest active infection.

- A Ghon focus is a peripheral area of lung consolidation.

— Post primary.

- Again may be active or inactive.
- Focal scarring and lung distortion \pm cavitation. Usually in upper lobes.
- Adenopathy and effusions are much less common.

— Miliary infection.

- Multiple small discrete widespread pulmonary nodules.

— Reactivation of TB can be difficult to diagnose. Comparison with old films for changes in appearance is helpful. Increased soft tissue and cavitation suggest active infection (figure 3.27–3.29).

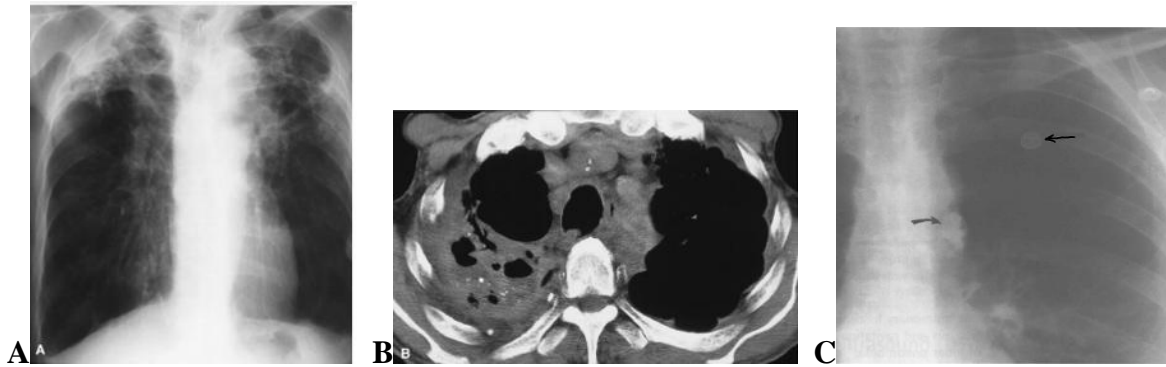


Figure 3.27 — Postprimary (reactivation) tuberculosis. (A) Frontal chest film reveals hyperinflation with marked fibrotic and cavitary disease in the upper lobes with severe volume loss. In general, thin-walled cavities (<5 mm) tend to be infective and, when thick-walled (<10 mm), squamous cell carcinoma of the lung enters into the differential diagnosis. (B) A CT scan through the lung apices demonstrates consolidative and cavitary changes with air and fluid levels and pleural and parenchymal calcifications. (C) Primary tuberculosis of the lungs: Ghon complex. There is a calcified granuloma in the parenchyma left upper lobe (straight arrow), with a calcified lymph node in the hilar region (curved arrow).

The combination of a focal parenchymal lesion (arrows) and enlarged right hilar lymph nodes produces the classic primary complex

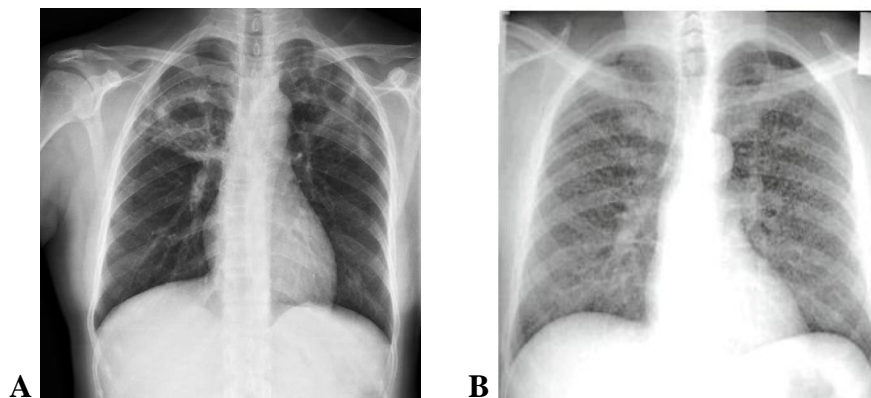


Figure 3.28 — (A) This frontal chest radiograph demonstrates multiple cavitary lesions with relatively thick walls in the upper lobes. The patient suffered from reactivation tuberculosis. (B) This frontal chest radiograph has innumerable tiny opacities throughout both lungs, secondary to miliary tuberculosis

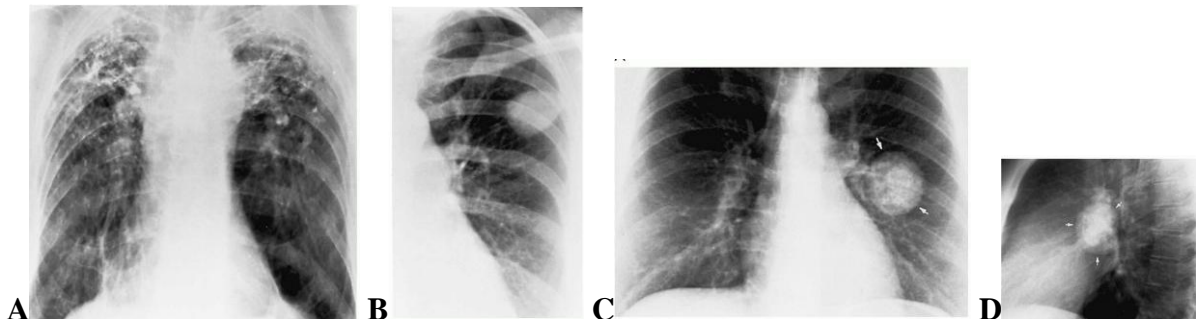


Figure 3.29 — (A) Tuberculosis. Bilateral fibrocalcific changes at the apices. There is upward retraction of the hila. (B) Tuberculoma. Single smooth, well-defined pulmonary nodule in the left upper lobe. In the absence of a central nidus of calcification, this appearance is indistinguishable from that of a malignancy. (C) Frontal and (D) lateral views of the chest show a large left lung soft-tissue mass (arrows) containing dense central calcification

Lung masses (figure 3.30, A to B for comparison at C to D)

Hamartoma (solitary pulmonary nodule, benign tumors)

Hamartomas grow at the same rate as their parent organ and therefore do not exhibit neoplastic pressure erosion of adjacent tissues. Hamartomas are typically peripheral, presenting as well-defined pulmonary nodules. Peripheral lesions are distributed equally among the lobes. Hamartomas may appear large but are typically less than 4 cm in diameter; an average diameter of 2 cm has been reported. Calcification is demonstrated in 30 % of patients, with rates as high as 75 % reported. When present, the pattern of calcification often has a pathognomonic «popcorn» or «comma-shaped» appearance. Approximately 8 % of hamartomas are in an endobronchial location, possibly leading to airway obstruction.

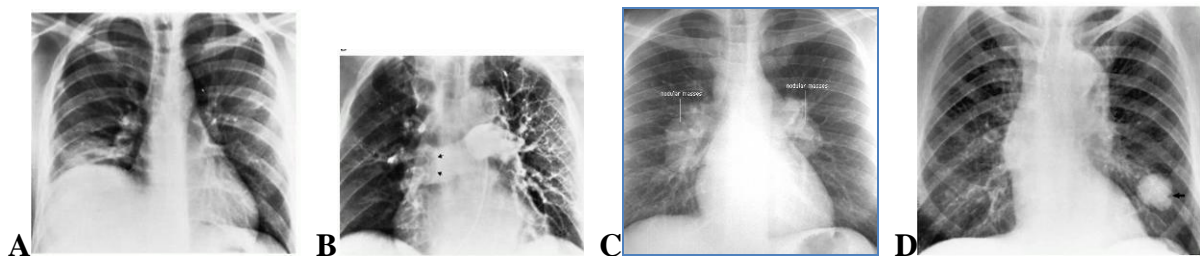


Figure 3.30 — Pulmonary embolism. (A) Plain chest radiograph demonstrates right basilar atelectasis associated with elevation of the right hemidiaphragm, representing a large subpulmonic pleural effusion. (B) Pulmonary arteriogram same patient shows virtually complete obstruction of the right pulmonary artery (arrows). (C) Frontal view of the chest demonstrate marked bilateral hilar adenopathy. (D) Bronchial adenoma. Nonspecific solitary pulmonary nodule at the left base. Note the notched indentation of the lateral wall (arrow) of the mass. Although this «Rigler notch» sign was initially described as being pathognomonic of malignancy, an identical appearance is commonly seen in benign processes

Bronchogenic carcinoma

Bronchogenic carcinoma is one of several neoplasms that may arise within the lung. It is now the leading cause of death from malignancy in the United States and most industrialized countries for both men and women.

Radiographic findings in bronchogenic carcinoma depend on the subtype of cancer and the stage of disease at the time of diagnosis. The two most common findings are an a solitary pulmonary nodule or mass (peripheral location) and a hilar mass (central location) (figure 3.31) with or without bronchial obstruction.

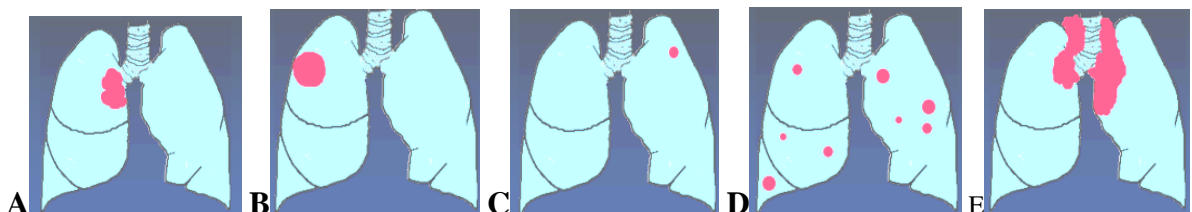

Figure 3.31 — (A to E) Diagrams main variants of bronchogenic carcinoma. (A) Central mass, (B) peripheral mass, (C) peripheral nodule, (D) multiple nodules, (E) adenopathy

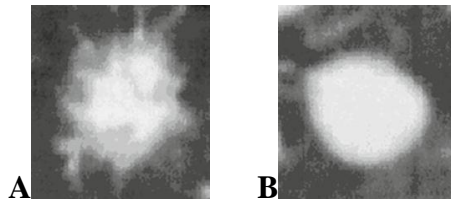


Figure 3.32 — (A) Primary lung carcinoma. The malignant mass is speculated and (B) the benign mass has smooth margins

All cell types can present with a pulmonary nodule (figure 3.32–3.34). Because squamous and small cell carcinoma arise from the central bronchi, the majority of these types of bronchogenic carcinoma produce a hilar mass. The hilar mass represents either the extraluminal portion of the bronchial tumor or hilar lymph node enlargement from metastatic disease. Extension of the hilar lesion into the mediastinum or the presence of mediastinal nodal metastases can produce a smooth or lobulated mediastinal mass. Marked mediastinal nodal enlargement producing a lobulated mediastinal contour is characteristic of small cell carcinoma. Extensive replacement of the mediastinal fat by either primary tumor or extracapsular nodal extension may produce diffuse mediastinal widening, with loss of the mediastinal fat planes and compression or invasion of the trachea or central bronchi, esophagus, and mediastinal vascular structures, as seen on contrast-enhanced CT or MR.

Obstruction of the bronchial lumen by the endobronchial component of a tumor can result in several different radiographic findings. The most common finding is resorptive atelectasis or obstructive pneumonitis of lung distal to the obstructing lesion. Resorptive atelectasis is recognized by the classic findings of lobar or whole lung collapse, whereas obstructive pneumonitis results in minimal or no atelectasis or occasionally an increase in the volume of the affected portion of lung. An abnormal increase in lobar or whole lung volume is recognized radiographically by a bulging interlobar fissure marginating the obstructed lobe or by mediastinal shift, respectively, and is termed drowned lung. Occasionally, the mass producing the lobar atelectasis creates a central convexity in the normally concave contour of the collapsed lobe, producing the S-sign of Golden. Most commonly, the opacity of the obstructed lung obscures the underlying central lesion.

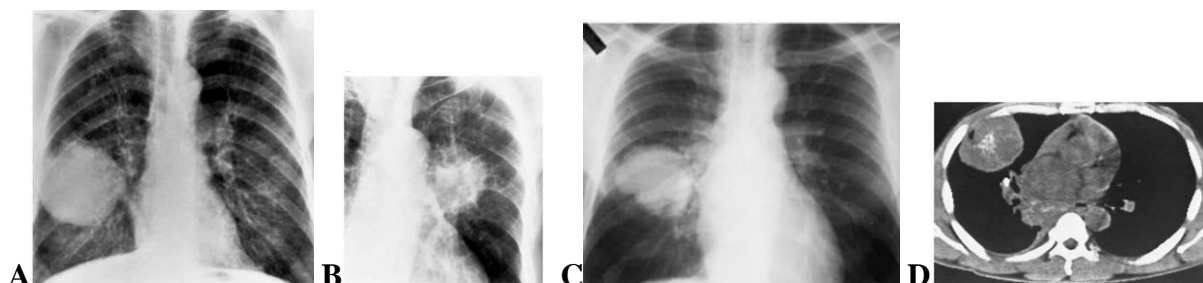


Figure 3.33 — Bronchogenic carcinoma. (A) Relatively well-defined mass peripheral localization. (B) Ill-defined solitary nodule central localization. (C) Chest radiograph shows a large mass in the middle lobe. A second large lesion is evident in the azygosophageal recess. (D) CT scan demonstrates dystrophic central calcification within the lesion and scattered calcifications in the mediastinal mass

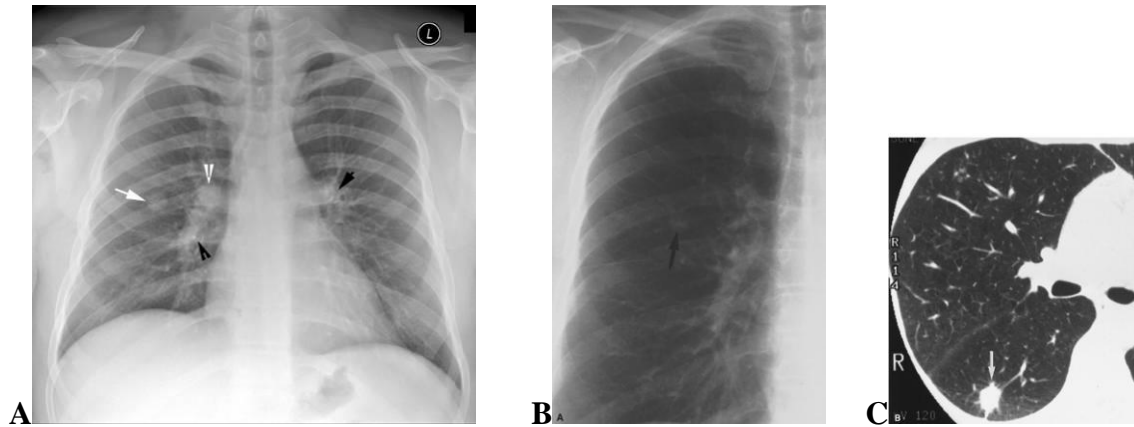


Figure 3.34 — Adenocarcinoma right lung. (A) Frontal chest radiograph. Note the solitary pulmonary nodule. White arrow points to the solitary pulmonary nodule. White arrowhead points to the right hilum which is full and dense. Black arrowheads point to calcification, evident in both hilum. Adenocarcinoma presenting as solitary pulmonary nodule. (B) Cone-down view of posteroanterior radiograph shows nodule in the right mid-lung (arrow). (C) Thin-section CT shows 12-mm nodule with spiculated margins (arrow) in the superior segment of the right lower lobe

The central mass is readily distinguished from vascular structures, with narrowing or occlusion of the bronchial lumen best seen on images viewed at lung windows. The central tumor is usually distinguished from atelectatic lung by the contrast between the perfused but nonventilated enhancing lung and the low-attenuation, nonenhancing central mass.

Tumors that arise from the bronchiolar or alveolar epithelium namely, adenocarcinoma and large cell carcinoma commonly produce an a solitary pulmonary nodule or mass on chest radiography. The radiographic evaluation of the solitary pulmonary nodule, in particular the size, growth rate, shape, margins, and internal density, has been reviewed in detail earlier in this chapter. A notched, lobulated, or spiculated margin to the nodule is common in bronchogenic carcinoma. The edge characteristics of an solitary pulmonary nodule are best appreciated on thin-section HRCT images through lesion.

The size and growth pattern of an a solitary pulmonary nodule are important characteristics. Masses > 3 cm in diameter seen in adults over 35 years of age are overwhelmingly malignant. The volume-doubling time (equivalent to a 25 % increase in diameter) for a malignant nodule usually ranges from 1 month (some squamous cell and large cell carcinomas) to 4 years (certain bronchioalveolar cell carcinomas).

Lung carcinomas can also cavitate, squamous cell carcinomas are the typical histological subtype to do so (figure 3.35). Apart from cavitation, other features of lung carcinomas can occur in the periphery of the lung or centrally (in or near the mediastinum). The outline of the tumour may be spiculated. Look for associated pleural effusion or hilar lymphadenopathy.

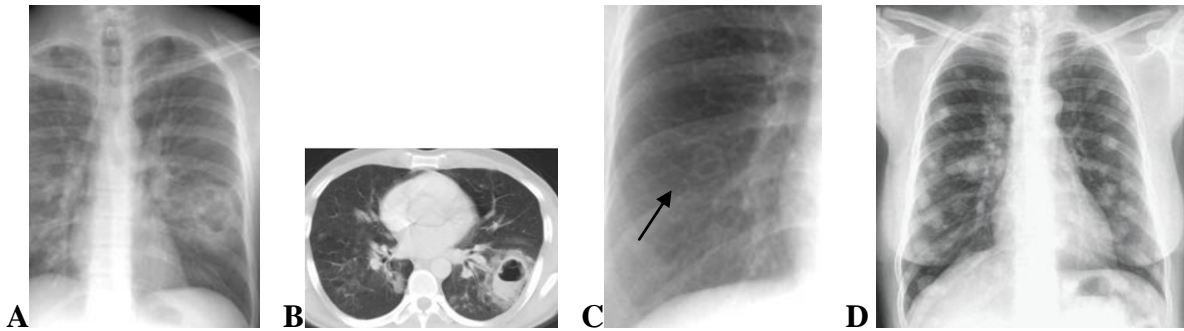


Figure 3.35 — (A to C) Examples of lung cavity, differential diagnosis:

- carcinoma;
- abscess-fungal/bacterial/TB;
- vascular-septic emboli;
- inflammatory-rheumatoid nodule.

(D) Metastases. This frontal chest radiograph in a woman with cervical carcinoma demonstrates multiple bilateral pulmonary well-circumscribed nodules scattered diffusely throughout both lungs, indicating metastases lungs

Proximal tumours can cause distal consolidation or collapse. Local rib destruction or multiple bony metastases can also occur so look for these.

Pancoast tumour (characteristics):

- This is a primary lung tumour located in the lung apex.
- The majority are squamous cell carcinomas.
- They represent 3 % of all primary lung tumours.
- Strong association with cigarette smoking.
- Usual age at presentation > 40 years.

Radiological features: (chest x-ray) unilateral apical pleural thickening/mass. The mass lesion may cavitate. Hilar enlargement secondary to lymphadenopathy. May be rib destruction and extrathoracic soft tissue mass lesion.

Metastatic lung disease (table 3.1).

Bloodborne metastasis presents as multiple well-defined nodules ranging from 1 to 5 cm in size located in the peripheral lung fields. Nodules tend to involve the basal portions of lungs, possibly related to preferential blood flow (figure 3.35, D). Larger lesions are termed cannonball metastasis. Lymphangitic spread of metastasis presents with Kerley lines, discrete nodules, and linear shadows, denoting a reticulonodular interstitial pattern of pulmonary disease.

The pattern typically is bilateral. A unilateral solitary presentation suggests a primary lesion, such as bronchogenic carcinoma. Cavitation is present in 6 % to 7 % and is more common with squamous cell carcinoma than adenocarcinoma. The uterus, cervix, colon, head, and neck are common sites of origin.

Table 3.1 — Symptoms of chest x-ray to differential diagnosis

«Mass» + ipsilateral adenopathy 1. Bronchogenic ca. 2. Lymphoma. 3. TB	Lung mass (radiological characteristics) 1. Homogenous liquid density. 2. > 5 cm in diameter (less than 5 cm is called solitary pulmonary nodule). 3. Sharp margins (no respect for segments or fissures)
Solitary pulmonary nodule 1. Bronchogenic ca. 2. Benign tumor. 3. Round pneumonia. 5. Rounded atelectasis. 6. TB granuloma. 7. Solitary met	Solitary pulmonary nodule Radiological criteria. 1. Liquid density. 2. Distinct margin. 3. Between 2–5 cms in diameter. 4. Oval or round
Lung disease & rib destruction 1. Bronchogenic ca, i.e. Pancoast tumor. 2. Multiple myeloma	Multiple lung nodules 1. Mets. 2. Rheumatoid nodules. 3. Septic emboli
Cavitary lung lesions 1. Carcinoma of the lung. 2. TB. 3. Abscess	Metastases 1. Usually well defined. 2. Nodules of varying size. 3. More common peripherally and in the lower lobes
Hilar adenopathy 1. TB. 2. Lymphoma. 3. Bronchogenic cancer	Micronodular lung disease 1. Mets. 2. Pneumoconiosis. 3. Miliary TB

Mediastinal mass

Radiological criteria includes (table 3.2):

Mass because:

- Homogeneous liquid density.
- Distinct margin (figure 3.36–3.37).

Mediastinal because:

- Has extrapleural sign (peripheral, absence of one of the margins both in PA and lateral view)
- Location is suggested by silhouette sign and lateral chest x-rays.

Table 3.2 — Common etiology of the mediastinal mass

Anterior mediastinum	Middle mediastinum	Posterior mediastinum
1. Thymoma. 2. Teratoma. 3. Thyroid. 4. Testicular metastasis. 5. Lymphoma	1. Lymph node disease. 2. Bronchial cysts	1. Neural lesions. 2. Esophageal disease. 3. Vertebral lesions

It should be noted here that the only difference between a lung «nodule» and a lung «mass» is that of size. Traditionally, nodules are soft tissue lesions in the lung that are smaller than 3cm, while masses are lesions that are 3 cm or greater. Size does matter. The larger the nodule, the more the suspicion for malignancy. Is it smooth? This generally favours a benign cause, but it is not a fail safe. A spiculated appearance is highly suspicious for carcinoma.

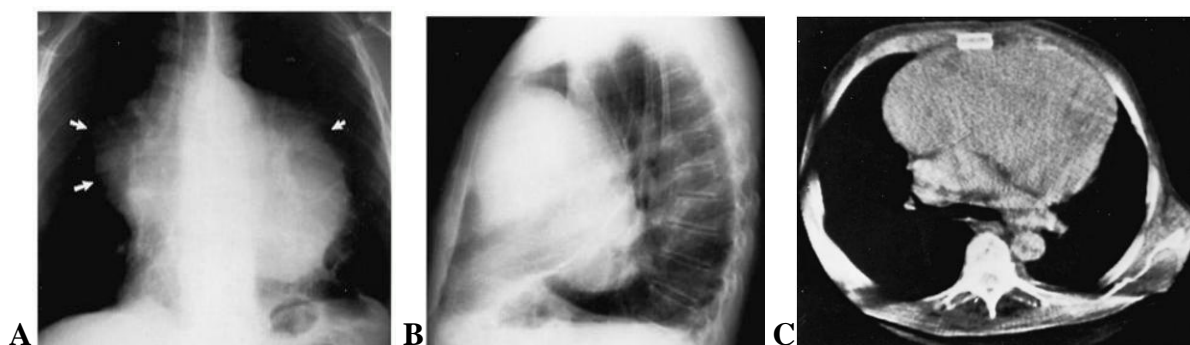


Figure 3.36 — Thymoma. (A) Frontal view shows a large bilateral lobulated mass (arrows) extending to both sides of the mediastinum. (B) Lateral view shows filling of the anterior precardiac space by a mass and posterior displacement of the left side of the heart. (C) On CT axial tomogram enormous soft-tissue mass in the anterior mediastinum with posterior displacement of other mediastinal structures. No difference in density can be seen between the mass and the heart behind it

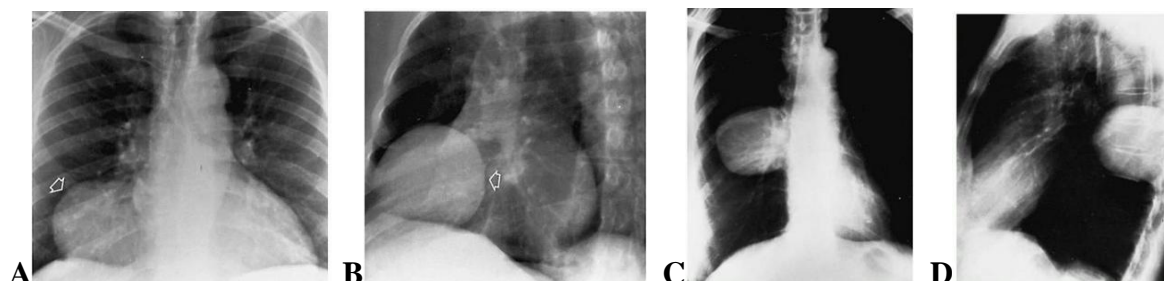


Figure 3.37 — Pericardial cyst. (A) Frontal and (B) oblique views demonstrate a smooth mass (arrows) in the right cardiophrenic angle. Neurogenic tumor. (C) Frontal and (D) lateral views of the chest demonstrate a large right posterior mediastinal mass

Leiomyoma, fibroma, neurofibroma (solitary pulmonary nodule, benign tumors).

Arising from the smooth muscle of the airways or pulmonary vessels, leiomyomas are rare neoplasms that present as endobronchial or intrapulmonary lesions with equal frequency. Radiographically, the parenchymal lesions are sharply margined, smooth or lobulated nodules or masses. The histologic distinction of benign from malignant lesions is difficult. Similarly, fibromas and neurofibromas appearing as SPNs lack distinguishing radiographic features.

2. Chest-screening (roentgenoscopy, fluoroscopy)

Roentgenoscopy is the second main method of chest examination of the chest. Chest screening involves an increased dose of irradiation to the patient compared with a simple chest X-ray. In practice it is now carried out only for the elucidation of specific problems. Thus it may be used to determine whether the diaphragm is moving normally or is paralysed; to assess the relationship of an opacity to other structures more accurately by observing it with different degrees of rotation on the screen; or to confirm valve or other intracardiac calcification since this is much better visualised by screening with an image intensifier than on a simple film. Sometimes it can be used for performing some surgical manipulations such as catheterization. While the analysis of an X-ray film could be done by any doctor, the roentgenoscopy is to be performed only by a radiologist.

3. X-ray linear tomography

This is used for the clearer demonstration of doubtful opacities in the lung field; for the better visualisation of masses or apparent masses at the lung hilus; for the study of the margins of opacities in the lung — whether they are clear-cut or infiltrating surrounding lung; and for the better demonstration of cavities or suspected cavities within a lung lesion, or of calcification in an opacity.

4. Fluorography

Fluorography it is one of additional methods of examination of chest. Most frequently it is applied to preventive researches instead of for diagnostics of diseases. It is because to a lower opportunity of this method to reveal small details on the image. In some cases fluorography can be applied to an estimation of dynamic changes of pathological process, but not for primary research.

5. Bronchography

This procedure is now little used and mainly for the demonstration of bronchiectasis. It is also sometimes used for the demonstration of an obstructed or stenosed bronchus in suspected carcinoma. Bronchography is performed in the X-ray department by the surgeon and radiologist. The contrast medium, propyl iodine or iodolipolum, is usually injected, through a catheter, involved to a main bronchus. Once the contrast medium has been injected the patient is tilted into the various positions necessary for filling the appropriate lobes of the lung with contrast.

6. Pulmonary angiography

Pulmonary angiography is performed by passing a catheter from a peripheral vein through the right atrium and right ventricle into the main pulmonary artery and then if necessary into the right or left pulmonary artery. Contrast medium is injected so as to opacity the blood supply of the area under examination. The main use of the method is to confirm a suspected diagnosis of pulmonary embolus. Pulmonary angiography is also occasionally used for the elucidation of opacities in the lung fields; for example to confirm a diagnosis of arteriovenous fistula or angiomatous malformation in the lung.

7. Radionuclide scanning

Scintigraphy of the lungs is widely practised to confirm or refute a clinical diagnosis or suspicion of pulmonary embolus. Lung scans can be performed following intravenous injection of technetium (^{99m}Tc) labelled macroaggregates or microspheres. This is known as the perfusion scan. It can also be performed by inhalation of radioactive xenon (^{133}Xe) or krypton (^{81m}Kr) or albumin aerosol labelled with technetium (^{99m}Tc). This is known as the ventilation scans. The ventilation scans are usually performed for the evaluation of low aerated areas of lung.

8. Ultrasound

The scope of application of chest sonography has been significantly widened in the last few years. Portable ultrasound systems are being used to an increasing extent in preclinical sonography, at the site of trauma, in the ambulance of the emergency physician or in ambulance helicopters. In the emergency room, at the intensive care unit and in clinical routine, chest sonography has proved its worth as a strategic instrument to be used directly after the clinical investigation. Ultrasound has proven to be more sensitive than flat anteroposterior chest radiography in the diagnosis of trauma-induced pneumothorax. Ultrasound provides added benefit by allowing sonologists to differentiate between small, medium, and large pneumothoraces, with good agreement with CT results. Sonography provides very significant information about the cause of sudden chest pain in the presence of a tension pneumothorax, in cases of pulmonary embolism. Pulmonary consolidations are detected if they reach the visceral pleura, or if they are situated behind an acoustic window. Sonography not only shows which structures are affected, but is also a reliable method for targeted diagnostic isolation of fluid and tissue. Sonography control investigations are particularly valuable in the course of pleural and pericardial effusions.

The high resolution of the sonographic image and the real-time examination make a major contribution to the diagnosis of diseases of the chest. Structures of the chest wall and pleural lesions are visualized by ultrasound.

9. CT

The main use of CT in the chest is in assessing mediastinal disease and in staging of lung cancer and other malignant lesions. It is also more sensitive than simple X-ray in identifying small pulmonary metastases and in detecting pulmonary fibrosis and bronchiectasis. High resolution thin section CT is invaluable in elucidating interstitial pulmonary disease.

10. MRI

MRI of the chest has proved most valuable in the assessment and characterization of mediastinal masses. Its ability to show sections in the sagittal and coronal as well as the axial plane and its ability to show vascular structures without contrast injections give it an advantage over CT. It is also useful in the diagnosis of hilar and mediastinal lymphadenopathy and in the staging of malignant tumours.

4. CARDIOVASCULAR SYSTEM IMAGING

Cardiovascular imaging is different from that for all other organs because the dimension of time has to be included in the subsecond acquisition and analysis of images. The chest film remains the entry-level examination for most cardiac problems. Although daunting economic and scheduling constraints remain, the cross-sectional methods — echocardiography, computed tomography, and magnetic resonance imaging are becoming the primary imaging choices to diagnose cardiac diseases because the millisecond temporal resolution and the millimeter spatial resolution can follow the beating heart and the moving blood.

The anatomic and physiologic effects of heart disease have many common imaging features. Chamber dilatation, valve calcification, and anomalous connections are morphologic signs of cardiac abnormalities. Increased or decreased blood flow and segmental wall motion disorders are physiologic signs of heart disease. The analysis for cardiovascular disease on the chest film, echocardiogram, CT scan, and MRI begins with a search for these common elements. Diagnostic imaging has a great role in the examination of patients with various cardiac and vessels diseases. Among all the methods of medical visualisation the first which are applied to patients are X-ray plain films and ultrasound examination which are available nowadays in the majority of clinics and hospitals. For more precise and deeper functional examinations are used CT, MRI, nuclear medical examinations and angiography. The task of the general practitioner is to be able to differentiate normal and pathologic image and to distinguish the most common diseases of the cardiovascular system.

The chest radiography

The chest film is often the first imaging procedure performed when heart disease is suspected, and more commonly, it is used to assess and follow the severity of cardiac disease. Because the chest film forms images by projection, this technique detects only those cardiopulmonary abnormalities that change the shape of the heart, mediastinum, and lungs and those that alter the structure of the pulmonary vasculature. Clinically silent heart disease may also be detected on a chest film taken for other reasons. Extracardial structures, particularly in the abdomen and the thoracic cage, may produce additional clues indicating heart disease. Calcification in the aortic valve, for example, identifies the abnormal structure and directs the differential diagnosis toward a particular pathologic lesion.

The complete X-ray examination at cardiac diseases imply the performance of four X-ray films — in anteroposterior (AP) view, left lateral view, right and left oblique views. The main among them would be the direct AP view.

Plan of X-ray film examination

1. Position of heart (oblique, vertical, horizontal).

2. Arcs of a cardiovascular shadow.

Cardiac chambers and borders of great vessels prominent on a cardiac borders create the shape of convexities or so-called cardiac arcs. In all the views only certain arcs can be seen.

3. X-ray cardiometria.

To reveal the sizes of heart and enlargement of it's chambers and dilatation of the great vessels (aorta and pulmonary artery) there are to be measured special sizes (figure 4.1).

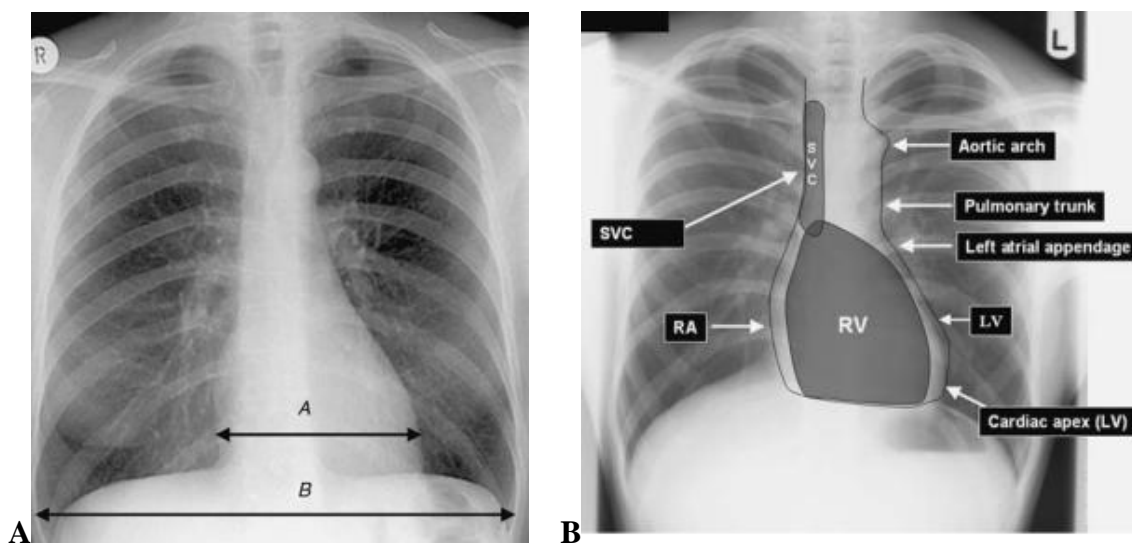


Figure 4.1 — Heart and mediastinum. (A) Assessment of heart size: the cardiothoracic ratio should be less than 0.5, i.e. $A/B < 0.5$; a cardiothoracic ratio of greater than 0.5 (in a good quality film) suggests cardiomegaly. (B) Assessment of cardiomediastinal contour: right side: SVC, RA; anterior aspect: RV; cardiac apex: LV; left side: LV, left atrial appendage, pulmonary trunk, aortic arch

4. The shape of heart is defined by constitutional features and sizes of heart chambers. The X-ray sign of the heart shape has diagnostic value only by comparison to other signs, in particular, with the exact sizes of heart chambers.

The *normal shape* of heart is detected most frequently at the persons of a normosthenic body build. It is characterized by smooth and clear contours of the arcs; the second and third arc on the left contour are often merge among themselves and the border between them can be poorly differentiated.

The *mitral shape* of heart is characterized by smoothing or protrusion and elongation of arcs of a pulmonary artery and left atrium. The degree of a protrusion can be various. This shape is detected at diseases with a hypertension in a small blood circle (mitral valve disease, pulmonary heart, unclosed arterial duct, defects of septums etc.). Can be accompanied by enlargement of ventricles, changes of a heart position and sizes, changes of a lung pattern and lung hili.

The *aortal shape* of heart is characterized by projectional shortening of the second and third arcs on the left contour of heart with formation of their concavity («the underlined waist of the heart»). Enlargement of aortic arches and left ventricle is detected. Heart widely adjoins to a diaphragm and its apex is uplifted. This shape is detected at a high position of a diaphragm (at an ascites or pregnancy), at aortal valve failures and some other diseases.

The *round shape* of heart is characterized by greater rounding of the right and left lower arcs, absence of clear angles between arcs on the left contour of heart with a total magnification of all the heart sizes. This shape is detected at some congenital heart failures (defects of chambers septums, stenosis of a pulmonary artery), and at the pericardial effusion.

Triangular (trapezoidal) shape of heart is characterized by smoothing and lining of all the arcs with absence of visual borders between them; the heart widely adjoins to a diaphragm, the cardio-diaphragmal angles are oftenly blunt. Most frequently is detected at a myocarditis.

5. The structure of a heart shadow is examined at all the views and implies the detection of homogeneity or if there are depositions of a calcium, foreign bodies.

6. Condition of all the chambers of heart is examined the next. On the basis of cardiometry the doctor makes the conclusion if the ventricles and atriums are enlarged or normal.

7. Condition of an aorta. Aorta might be not changed, elongated, dilated, sometimes it can contain calcifications.

8. Condition of lung hiluses. This X-ray sign is very important at various cardiac diseases with the hypertension or congestion of blood in a pulmonary circle. The Hiluses can be dilated or not dilated)

9. Condition of a lung pattern. This sign also is important at changes of blood flow in a lung circus. The lung pattern can be normal, increased, decreased. Sometimes on a background of a changed lung pattern the presence of a hemosiderosis can be detected.

After all these X-ray signs and measurements are taken into account the general conclusion is done by the doctor.

X-ray diagnostics of the most common diseases

X-ray diagnostics of a mitral stenosis

There are two variants of stenosis of the left atrioventricular valve:

1. Stenosis due to rheumatic endocarditis.
2. Stenosis caused by atherosclerotic process (seldom).

The mitral stenosis constitutes 54 % from all valve failures of a rheumatic origin (figure 4.2). Isolated stenosis — 48–68 % from all mitral lesions.

Pathologic mechanism of the disease: at narrowing of the left atrioventricular hole the inflow of a blood from the left atrium to left ventricle is labored; this leads to the left atrium becomes hypertrophied and dilated. In a left atrium the

blood can accumulate sometimes ten times more than normal. The left ventricle receives less amount of bloods, than under normal conditions and remains unchanged. The blood, collected in the left atrium, leads to the extent congestive process in all the small circle of a blood circulation, increases the strain of a right ventricle, which has to overcome the resistance which has arisen in a small circle. A right ventricle is hypertrophied and later dilated. In far late stages appears the functional failure of the three-cuspidate valve with a dilatation of the right atrium and associated congestion in the major circle of a circulation.

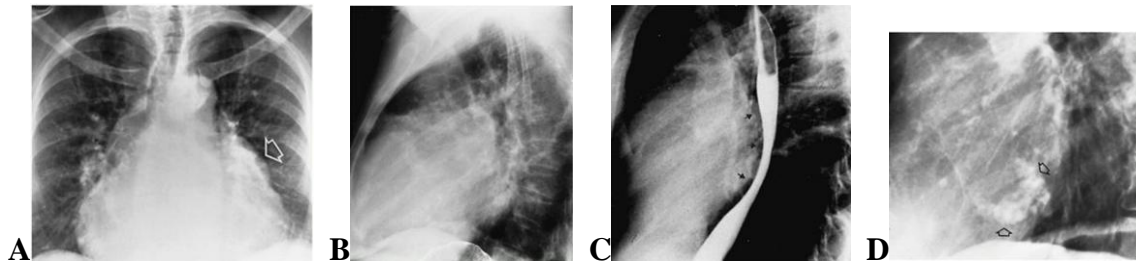


Figure 4.2 — Mitral stenosis. (A) Frontal and (B) lateral views of the chest demonstrate cardiomegaly with enlargement of the right ventricle and left atrium. The right ventricular enlargement causes obliteration of the retrosternal air space, whereas left atrial enlargement produces a convexity of the upper left border of the heart (arrow, A).

Mitral stenosis. (C) On a lateral view, the enlarged chamber produces a discrete pos-terior indentation (arrows) on the barium-filled esophagus. (D) In another patient, there is associated calcification of the mitral valve annulus (arrows)

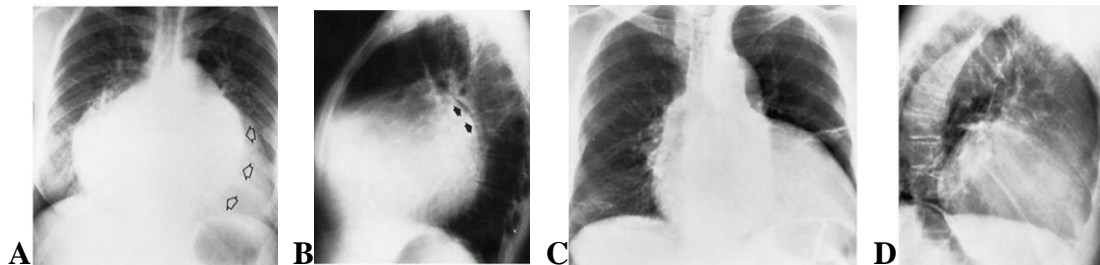


Figure 4.3 — Mitral insufficiency. (A) Frontal and (B) lateral views of the chest demonstrate gross cardiomegaly with enlargement of the left atrium and left ventricle. Note the striking double-contour configuration (open arrows, A) and elevation of the left main bronchus (closed arrows, B), characteristic signs of left atrial enlargement. The aortic knob is normal in size, and there is no evidence of pulmonary venous congestion.

Arteriosclerotic heart disease. (C) Frontal and (D) lateral views of the chest show marked enlargement of the left ventricle. There is also tortuosity of the aorta and bilateral streaks of fibrosis

X-ray diagnostic:

1st stage — X-ray signs of a mitral configuration of heart with enlargement of a pulmonary artery arc, hypertrophy of the left atrium and enlargement of its arc; the waist of the heart is smoothed and flattened or slightly convex. The left ventricle is not changed or it looks diminished. Rising of pressure in pulmonary veins leads to their visibility on roentgenograms as horizontally located vessels; lung congestion and dilatation of hili.

2nd stage — On the right contour of heart there is detected a high position of an atriovasal corner. Because of a hypertrophy of a right ventricle there is a rotation of heart and shift of its apex to the left and backwards; the left atrium comes to a contour on the right in the area of the atriovasal corner so on the right contour three arcs are formed.

Because of enlargement of the left atrium there's detected the shift of contrasted esophagus on an arc of small or medial radius (4–6 cm) and widening of a bifurcation angle of a trachea. Due to congestion of blood appears the transuding of a blood through the veins walls and formation of the hemosiderosis (nodules 1–2 mm size) in the lower and medial parts of lungs. The edema of an interstitial tissue results in an unclearness of a lung pattern. Reaction of a pleura as the under line interlobar pleura or even exudate because of congestion. Sometimes there is possible the reflective spasm of veins, then they are poorly visible on a roentgenogram, and arteries begin to extend, especially in the upper parts of lungs.

3rd stage — Dilatation of a right ventricle, over-dilatation of the right atrioventricular hole with functional tricuspidal failure, the right atrium is enlarged, enlargement of heart borders to the right. The sclerosis of walls of vessels results in deformation of a lung pattern and decrease in peripheric parts of lungs because of an obliteration of small vessels. The lungs hili look «chopped off» because of weakened lung pattern.

X-ray diagnostics of the mitral valve incompetence (figure 4.3)

There are two forms of a mitral incompetence:

1. Organic failure — at a lesion of the valve leaflets, chords or papillary muscles.
2. The functional failure — appears secondary at dilation of the left atrioventricular hole.

Pathologic mechanism of a failure: at incomplete closing of the mitral valve a blood at a systole of a left ventricles is not thrown out to an aorta completely, and partially reverted from a left ventricle in the left atrium. Thus an atrium at a phase of its diastole accumulates more blood, than under normal conditions and this additional amount of a blood gets to a left ventricle. The excessive amount of a blood in a left ventricle results in its dilatation and hypertrophy of its walls. In far late stages of the disease, the excessive amount of a blood in the left atrium results in rising of a pressure in pulmonary veins and congestion in a pulmonary circle of blood circulation. The pressure in a right ventricle raises, there comes its hypertrophy and dilatation, with the subsequent development of functional failure of a tricuspidal valve, rising of a strain for the right atrium and congestion in a major circle of a circulation.

X-ray diagnostics:

1st stage — mitral configuration of heart with enlargement of an arc of the left atrium and left ventricle, the waist of the heart is flattened. The transverse size of the heart is enlarged. The right parts of the heart are not changed. No changes of lung pattern and of lung hili. At a roentgenoscopy there's detected the sign of a «pendulum».

2nd stage — a hypertrophy of a left ventricle, dilatation of the left atrium and hypertrophy of a right ventricle. The enlargement of the third and fourth arcs on the left heart contour; the heart is located horizontally. Because of enlargement of the left atrium there's detected the shift of a contrasted esophagus by the arc of major radius (more than 6 cm) and enlargement of an angle of a tracheal bifurcation sometimes up to blunt. The left atrium can come on the right contour of heart, forming an additional arc.

3rd stage — severe expansion of the left atrium (sometimes atriomegaly) and left ventricle, enlargement of the right parts of a heart. Increased lung pattern due to veins. Enlargement and loss of structure of lung hili. On a background of heart there might be seen the additional shadow caused by enlargement of the left atrium. Contrasted esophagus is displaced to the right («slipping» of an esophagus from an enlarged left atrium).

X-ray diagnostics of the aortal valve incompetence

Etiology: a rheumatic lesion of leaflets of the aortal valve, atherosclerosis, lues. Pathologic mechanism of a lesion: Owing to incomplete closing of leaflets of the aortal valve, the blood during a diastole of a left ventricle returns back from the aorta. As the result of this the left ventricle dilates. For ejecting a greater amount of a blood there's necessary the greater effort and there develops a hypertrophy of a myocardium of a left ventricle, but the dilatation prevails above a hypertrophy. The excessive amount of a ejected blood in a phase of a systole results in a uniform aortectasia. At the severe dilatation of a left ventricle there arises the dilation of the left atrioventricular hole up to development of the functional failure of the mitral valve.

X-ray image

In a period of compensation and at minor valval lesion the heart is not enlarged or the left ventricle a little bit enlarged. In a direct AP projection the minor enlargement of the fourth arc on the left contour of heart is detected. (On the chart — the signs of enlargement of a left ventricle).

In patients with the severe aortal failure the cardiac shadow acquires a typical aortal configuration, the heart is considerably enlarged, mainly due to a left ventricle, the waist of the heart is sharply marked and become concave; an apex of the heart is displaced to the left and rounded, and is usually lo-

cated above a dome of a diaphragm. The heart widely lays on a diaphragm («laying heart»). An enlarged left ventricle in the second oblique view promi- nents backward. The shadow of an aorta is usually uniformly dilated. At a fluoroscopy in the area of an apex of heart and aortic arch the very intensive and high amplitude pulsation is detected. In a direct AP view the considerable enlargement and protuberance of an arc of a left ventricle on the left contour (1), elongation and protuberance of an arc of a uprising aorta on the right con- tour (2) is detected. In oblique projections — the enlargement of an arc of a left ventricle and the aortic arc.

At the addition of the functional failure of the mitral valve, there would be the signs of a pulmonary venous hypertension, the contrasted esophagus is shifted on an arc of major radius owing to enlargement of the left atrium. Later there is possible the enlargement of a right ventricle.

X-ray diagnostics of stenosis of an aortal ostium

Etiology: the main reasons are the atherosclerosis, rheumatic disease, lues. The isolated aortic stenosis is seldom, more often it is combined with incompetence.

Pathologic mechanism of a lesion: owing to an aortic stenosis the ejection of a blood from left ventricle is impeded. The excessive amount of a blood in a left ventricle results in its dilatation and hypertrophy of its myocardium, with prevailing of a hypertrophy. The high flow rate of a blood which is coming out through a narrow hole results in major rising of pressure in an aorta and its dila- tation. At a decompensation of a stenosis the functional failure of the mitral valve appears because of dilation of its lumen.

X-ray image

In a period of compensation the heart is of normal size, in some cases the minor enlargement of a left ventricle is detected. In a direct AP projection the small enlargement of the fourth arc on the left contour of heart is detected. (On the chart there are the signs of enlargement of a left ventricle).

In patients with the severe stenosis the shape of heart is aortal: the arc of a left ventricle is enlarged and rounded, in a direct AP view the waist of the heart is well expressed and concave, the apex of the heart is rounded, shifted down- wards and visualized as if under a diaphragm, sometimes on a background of a gas bubble of a stomach. In the second oblique view the enlargement of an arc of a left ventricle (1) backward is detected. The pulsation of a left ventricle (at a roentgenoscopy) is slow, deep and strong, weakened at a decompensation. The dilation of an initial part of aorta (2) and intensifying of its pulsation in this arc. Revealing of aortal valves calcification is possible.

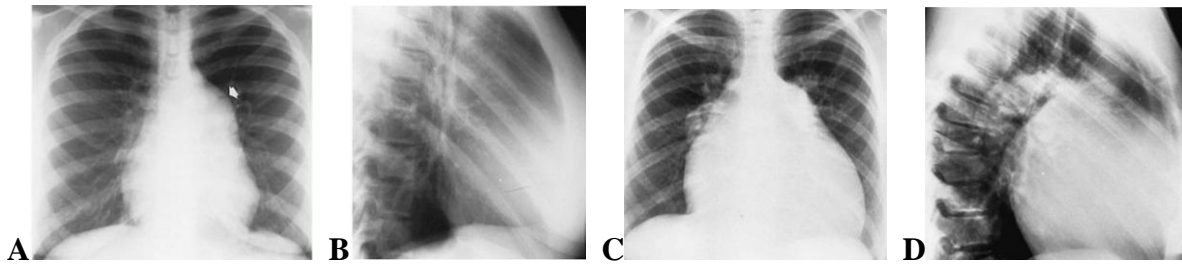


Figure 4.4 — Pulmonary stenosis. (A) Frontal and (B) lateral views show striking poststenotic dilatation of the pulmonary artery (arrow) in addition to filling of the retrosternal air space, indicating right ventricular enlargement. Cor pulmonale (primary pulmonary hypertension). (C) Frontal and (D) lateral views of the chest in a patient with primary pulmonary hypertension show marked globular cardiomegaly with prominence of the pulmonary trunk and central pulmonary arteries. The peripheral pulmonary vascularity is strikingly reduced. Right ventricular enlargement has obliterated the retrosternal air space on the lateral view

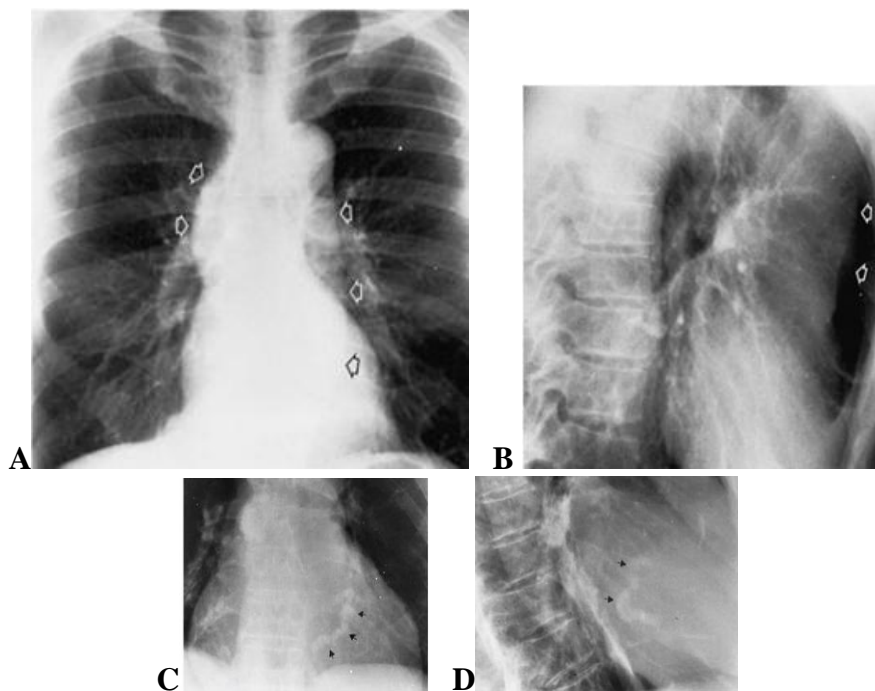


Figure 4.5 — Essential (idiopathic) hypertension. (A) Frontal and (B) lateral views of the chest demonstrate characteristic tortuosity of the aorta (arrows), especially the ascending portion. Because the elevated blood pressure has caused left ventricular hypertrophy without dilatation, of the cardiac silhouette remains normal.

Coronary artery calcification (arrows) in ischemic heart disease.

(C) Frontal and (D) lateral views of the chest

At a reduced function of a left ventricle and decompensation of a valve lesion the functional failure of the mitral valve is possible, there would be the signs of a pulmonary venous hypertension; the contrasted esophagus is shifted on an arc of major radius owing to enlargement of the left atrium. Later the enlargement of a right ventricle is possible.

Clinical examples of radiography at diseases heart and great vessels

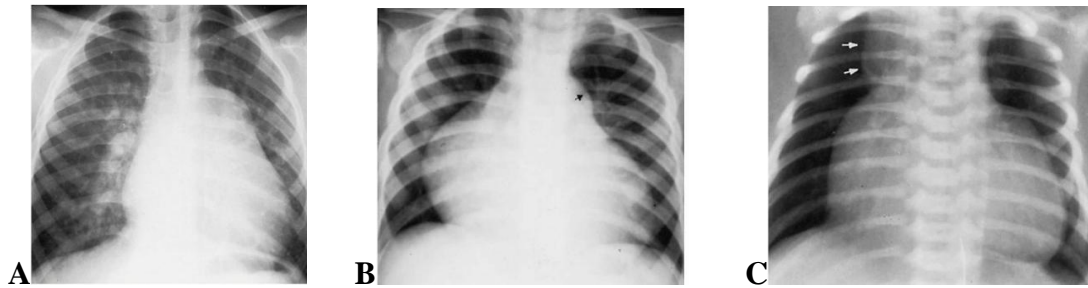


Figure 4.6 — (A) Ventricular septal defect. The heart is enlarged and somewhat triangular, and there is an increase in pulmonary vascular volume. The pulmonary trunk is very large and over-shadows the normal-sized aorta, which seems small by comparison.

(B) Trilogy of Fallot. Decreased pulmonary vascularity with prominent poststenotic dilatation (arrow) of the pulmonary artery. There is enormous right atrial and moderate right ventricular enlargement. (C) Ebstein's anomaly. In addition to decreased pulmonary vascularity, there is enlargement of the right atrium, causing upward and outward bulging of the right border of the heart (squared appearance). Widening of the right side of the superior portion of the mediastinum (arrows) reflects marked dilatation of the superior vena cava due to right ventricular failure

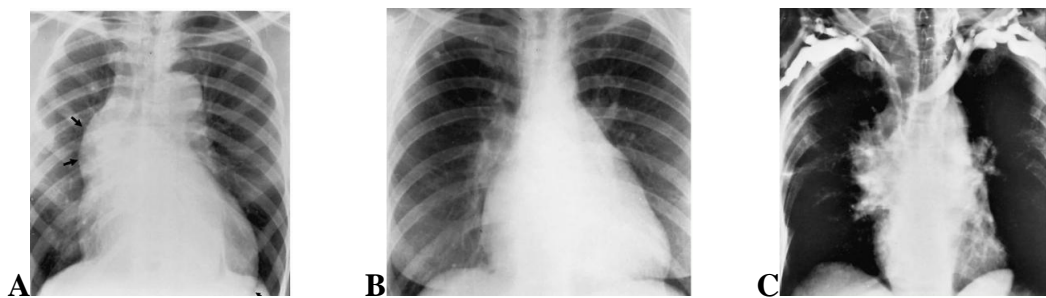


Figure 4.7 — (A) Aortic insufficiency. Marked dilatation of the ascending aorta (arrows), suggesting some underlying aortic stenosis. The left ventricle is enlarged with downward and lateral displacement of the cardiac apex. Note that the cardiac shadow extends below the dome of the left hemidiaphragm (small arrow). (B) Congenital aortic stenosis. Small aortic arch with moderate enlargement of the left ventricle. (C) Bronchogenic carcinoma.

Bilateral upper extremity venogram shows virtual occlusion of the superior vena cava by a large oat cell tumor in the right hilar and perihilar region

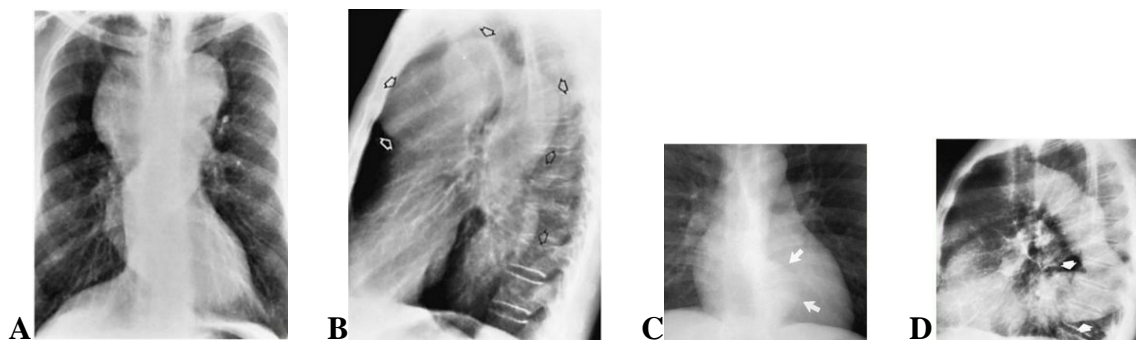


Figure 4.8 — Aneurysm of the thoracic aorta. (A) Frontal and (B) lateral views of the chest demonstrate marked dilatation of both the ascending and descending portions of the thoracic aorta (arrows, B), producing anterior and posterior mediastinal masses, respectively. Aneurysm of the descending aorta. (C) Frontal view of the chest demonstrates a localized bulging of the descending aorta (arrows). (D) Lateral view in another patient shows aneurysmal dilatation of the lower thoracic aorta (arrows). Note the marked tortuosity of the remainder of the descending aorta

Ultrasound examination of heart

Allows to estimate the sizes of the heart chambers, the thickness of myocardium, to estimate morphology and motions of valves, character of a blood motion in heart and large vessels (dopplerography); to determine a minor amount of a fluid in a pericardial cavity (figure 4.9-C with comparison to A-B). Gives a possibility to visualize the heart chambers in various planes.

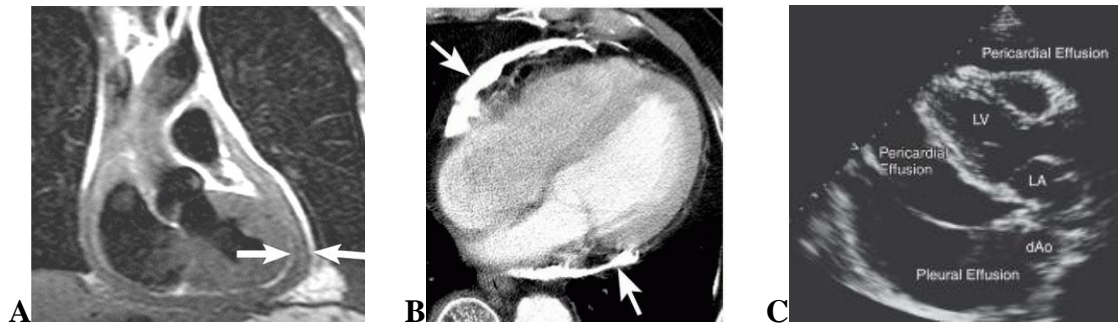


Figure 4.9 — Constrictive pericarditis. (A) Coronal T1-weighted MR image shows abnormally thickened pericardium (arrows) outlined by epicardial and mediastinal fat. (B) Contrast CT shows dense pericardial calcification (arrows) in a patient with a history of hemopericardium. (C) Two-dimensional echocardiographic view in a patient with both a pleural and pericardial effusion. The echo-free space anterior and immediately posterior to the heart is pericardial fluid. The parietal pericardial layer divides the posterior pericardial fluid from the pleural fluid. The location of the descending thoracic aorta in relation to the fluid is often helpful in distinguishing pleural from pericardial fluid. The descending aorta is seen in cross section behind the heart. Pericardial fluid lies between the heart and the aorta while pleural fluid is seen posterior to both the heart and the aorta. Ao, aorta; dAo, descending aorta; LA, left atrium; LV, left ventricle

REFERENCES

1. *Adam, A.* Diagnostic radiology / A. Adam, A. K. Dixon. — 5th ed. — Elsevier, 2008. — 1140 p.
2. *Brant, W. E.* Fundamentals of diagnostic radiology / W. E. Brant, C. A. Helms. — 3rd ed. — Lippincott Williams & Wilkins, 2007. — 1529 p.
3. *Donnelly, E. F.* The medical student's guide to the plain chest film / E. F. Donnelly. — Carchedon, 2006. — 104 p.
4. *Gunderman, R. B.* Essential radiology: clinical presentation, pathophysiology, imaging / R. B. Gunderman. — 2nd ed. — Thieme, 2006. — 370 p.
5. *Pretorius, S.* Radiology secrets plus / S. Pretorius. — 3rd ed. — Mosby: Elsevier, 2011. — 575 p.
6. *Zimmermann, R.* Nuclear medicine. Radioactivity for diagnosis and therapy / R. Zimmermann. — Sciences, 2006. — 173 p.
7. *Primer of diagnostic imaging* / R. Weissleder [et al.]. — 5ed. — Mosby: Elsevier, 2011. — 792 p.
8. *Daffner, R. H.* Clinical radiology. The essentials / R. H. Daffner, M. S. Hartman. — 4th ed. — Lippincott Williams & Wilkins, 2014. — 546 p.
9. *Planner, A.* A-Z of Chest radiology / A. Planner, M. C. Uthappa, R. R. Misra. — Cambridge, 2007. — 211 p.
10. *Joarder, R.* Chest x-ray in clinical practice / R. Joarder, N. Crundwell. — Springer: London, 2009. — 195 p.
11. *Sutton, D.* Textbook of radiology and imaging: in 2 v. / D. Sutton. — 7th ed. — Elsevier Science, 2003. — Vol. 1. — 930 p.
12. *Sutton, D.* Textbook of radiology and imaging: in 2 v. / D. Sutton. — 7th ed. — Elsevier Science, 2003. — Vol. 2. — 1020 p.
13. *Lisle, D. A.* Imaging for students / D. A. Lisle. — 2nd ed. — London: Arnold, 2001. — 262 p.
14. *Elgazzar, A. H.* The pathophysiologic basis of nuclear medicine / A. H. Elgazzar. — 2nd ed. — Springer, 2006. — 566 p.
15. *Королюк, И. П.* Лучевая диагностика / И. П. Королюк, Л. Д. Линденбрaten. — 3-е изд. — М.: Бином, 2013. — 496 с.
16. *Ryan, W. D.* Blueprints in radiology / W. D. Ryan, M. S. Komaiko, B. D. Pressman. — Blachvell, 2003. — 124 p.
17. *Singh, H.* Radiology fundamentals. Introduction to imaging & technology / H. Singh, J. A. Neutze. — 4th ed. — Springer, 2012. — 381 p.

Учебное издание

Ермолицкий Николай Михайлович

ЛУЧЕВАЯ ДИАГНОСТИКА
(на английском языке)

Учебно-методическое пособие
для студентов 3 курса факультета по подготовке специалистов
для зарубежных стран медицинских вузов

В двух частях

Часть 1

Редактор ***Т. М. Кожмякина***
Компьютерная верстка ***С. Н. Козлов***

Подписано в печать 04.07.2016.
Формат 60×84¹/₁₆. Бумага офсетная 80 г/м². Гарнитура «Таймс».
Усл. печ. л. 6,28. Уч.-изд. л. 6,86. Тираж 65 экз. Заказ № 260.

Издатель и полиграфическое исполнение:
учреждение образования «Гомельский государственный медицинский университет».
Свидетельство о государственной регистрации издателя,
изготовителя, распространителя печатных изданий № 1/46 от 03.10.2013.
Ул. Ланге, 5, 246000, Гомель.