

МИНИСТЕРСТВО ЗДРАВООХРАНЕНИЯ РЕСПУБЛИКИ БЕЛАРУСЬ
УЧРЕЖДЕНИЕ ОБРАЗОВАНИЯ
«ГОМЕЛЬСКИЙ ГОСУДАРСТВЕННЫЙ МЕДИЦИНСКИЙ УНИВЕРСИТЕТ»

Кафедра онкологии

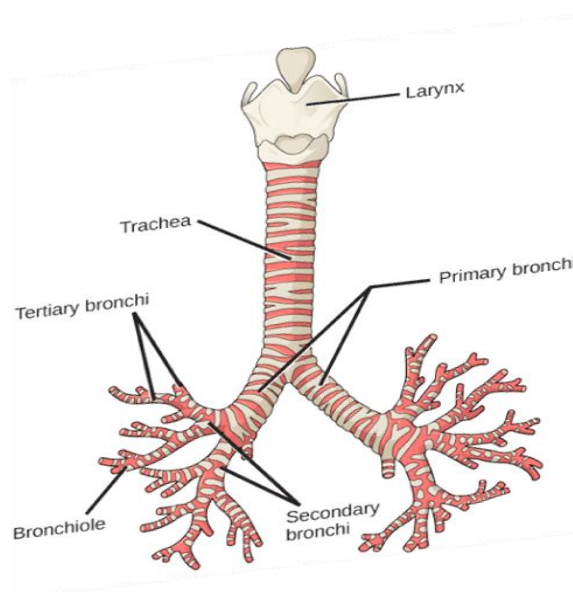
Т. Н. НЕСТЕРОВИЧ, И. В. МИХАЙЛОВ

РАК ЛЕГКОГО. РАК ГОРТАНИ

Учебно-методическое пособие
для студентов 5 и 6 курсов факультета по подготовке специалистов
для зарубежных стран медицинских вузов

LUNG CANCER. LARYNGEAL CANCER

Teaching workbook for 5th and 6th year students
of the Faculty on preparation of experts for foreign countries
of medical higher educational institutions



Гомель
ГомГМУ
2017

УДК 616.24-006.6+616.22-006.6(072)=111

ББК 55.694.12(2Англ)я7

М 56

Рецензенты:

кандидат медицинских наук,

заведующий радиологическим отделением

Гомельского областного клинического онкологического диспансера

Д. В. Окунцев;

кандидат медицинских наук,

заведующий патологоанатомическим отделением

Гомельского областного клинического онкологического диспансера

С. Л. Ачинович

Нстерович, Т. Н.

М 56 Рак легкого. Рак гортани: учеб.-метод. пособие для студентов 5 и 6 курсов факультета по подготовке специалистов для зарубежных стран медицинских вузов = Lung cancer. Laryngeal cancer: teaching workbook for 5th and 6th year students of the Faculty on preparation of experts for foreign countries of medical higher educational institutions / Т. Н. Нестерович, И. В. Михайлов. — Гомель: ГомГМУ, 2017. — 24 с.

ISBN 978-985-506-946-2

В пособии изложены основные сведения об этиологии, клинике, диагностике, лечении, профилактике и прогнозе рака легкого и гортани. Приведена TNM-классификация. Пособие соответствует учебной программе по онкологии.

Предназначено для студентов 5 и 6 курсов факультета по подготовке специалистов для зарубежных стран медицинских вузов.

Утверждено и рекомендовано к изданию научно-методическим советом учреждения образования «Гомельский государственный медицинский университет» 13 июня 2017 г., протокол № 5.

УДК 616.24-006.6+616.22-006.6(072)=111

ББК 55.694.12(2Англ)я7

ISBN 978-985-506-946-2

© Учреждение образования
«Гомельский государственный
медицинский университет», 2017

CONTENTS

LUNG CANCER	4
Introduction	4
Etiology	4
Histological types	5
Signs and symptoms	6
TNM-classification in lung cancer	8
Diagnosis	10
Treatment	13
Prevention	14
Prognosis	14
LARYNGEAL CANCER	14
Introduction	14
Etiology	15
Histological types	15
Signs and symptoms	15
Diagnosis	16
TNM-classification in Laryngeal cancer	17
Treatment	20
Prognosis	21
Prevention	22
Questions	23
References	24

LUNG CANCER

Introduction

Lung cancer is approximately three times more common in men than females. Lung cancer leads as cause of cancer deaths among women and men. In general, the incidence of lung cancer in industrialized western countries is increased compared to third world countries. Lung cancer is rare among people less than 40 years of age. The vast majority of lung cancers are diagnosed in people over the age of 50. The average age of newly diagnosed lung cancer patients is around 60 years of age. In 2012, there were 1,82 million new cases globally, and 1,56 million deaths due to lung cancer, representing 19,4 % of all deaths from cancer. The highest rates are in North America, Europe and East Asia, with over a third of new cases in 2012 in China. Rates in Africa and South Asia are much lower.

Etiology

1. Smoking.

Today, the epidemiology of lung cancer is the epidemiology of smoking. Other factors are relatively of minor importance. Cigarette smoke contains a number of proven carcinogens in both the particulate and gaseous phase including: polycyclic

aromatic hydrocarbons, N-nitrosamines, benzene, vinyl chloride , chromium , arsenic. It is important:

- unfiltered cigarettes
- age at onset of smoking
- number of cigarettes smoked per day.

2. Asbestos.

Asbestos is a fibrous mineral that has been widely used in manufacturing, construction, and industry over many years. People exposed to high amounts of asbestos are at increased risk for lung cancer and malignant pleural mesothelioma, a rare form of cancer that involves the covering of the lungs. Although everyone has some low-level exposure to asbestos, it is usually only people who have had work-related exposure to asbestos that are at increased risk for cancer.

3. Radon.

Radon is a naturally occurring, radioactive gas. It is odorless and tasteless. It is formed from the radioactive decay of uranium that normally takes place in the soil and deep in the earth. Exposure to high levels of radon is associated with an increased risk of lung cancer.

The amount on radon in the soil varies from one location to another. Underground miners may be exposed to high levels of radon if the mine is located in a uranium-rich area. Similarly, if a home is in an area with high soil levels of uranium and radon, cracks in the basement or foundation may cause high levels of indoor radon.

4. *Environment and occupational carcinogens.*

5. *Familial risk factors.*

The role of hereditary factors is less for lung cancer than it is for other cancer.

Histological types

The majority (90–95 %) of tumors in the lung are bronchogenic carcinomas (arising from the bronchial epithelium). Classification is important because the histological subtype determines the treatment and prognosis (Figure 1).

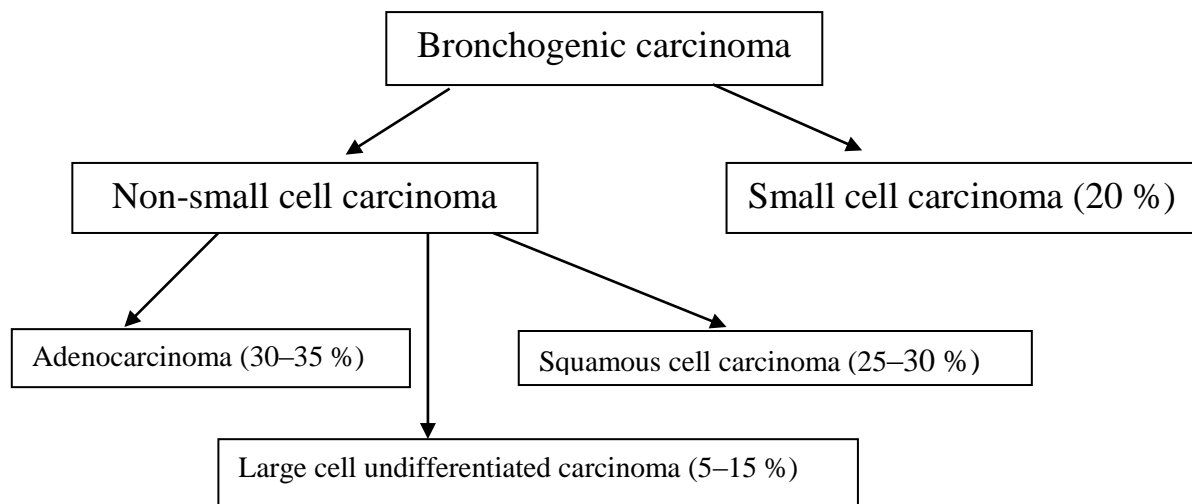


Figure 1 — Classification of histological types

Squamous Cell Carcinoma (SCC): these tumors tend to be located in the central area of the lung.

SCC occurs most frequently in men and in people over age 65 of both sexes. SCC most strongly associated with smoking. SCC tumors often invade neighboring structures. SCC metastasise later than other forms. Variants of SCC include *papillary SCC*, *clear cell SCC*, *small cell SCC*, and *basaloid SCC*.

Adenocarcinoma is the most common lung cancer which usually arises from peripheral small bronchi and is often associated with a scar. Adenocarcinoma is the most common form of lung cancer in women and people who have never smoked. This form of lung cancer is also the most common type seen in people less than age 50. Variants of adenocarcinoma include *acinar adenocarcinoma*, *papillary adenocarcinoma*, *bronchioloalveolar adenocarcinoma (BAC)*, and *other mixed subtypes*. A distinctive type of adenocarcinoma is BAC. BAC is pathologically different, showing growth along alveolar septa and little if any desmoplastic or glandular change. These tumors are interesting in that they present in three different fashions: a solitary peripheral nodule, multifocal disease, or a rapidly progressive pneumonic form, which appears to spread from lobe to lobe, ultimately encompassing both lungs. Among the adenocarcinomas, the BAC has a better prognosis than the other subtypes with special biologic features, and for both SCC and adenocarcinoma the outcome for the well-differentiated tumors is better than for the poorly differentiated tumors.

Large cell carcinoma (LCC) can occur in any part of the lung, poorly differentiated, strongly associated with smoking. There are several variants of large cell carcinoma including *clear cell LCC*, *basaloid LCC*, *lymphoepithelioma-like carcinoma*, and *large cell neuroendocrine carcinoma*.

The prognosis for large cell carcinoma is generally less favorable than for other forms of non-small cell carcinoma.

Small cell carcinoma is strongly related to smoking. It is a very aggressive neoplasm, grows more quickly than non-small cell carcinoma. It tends to spread to lymph nodes and metastasize to other organs early in the disease process. Most people with small cell carcinoma have metastases at the time of diagnosis. Small cell carcinoma tends to be initially responsive to chemotherapy and radiation therapy.

There are other types of *non-epithelial neoplasms* that arise in the lungs. Examples of these cancers include carcinoid tumors, malignant pleural mesotheliomas, fibrosarcomas, and leiomyosarcomas. The lungs are also a frequent location for metastatic tumors from other locations in the body.

Signs and symptoms

For simplicity, the symptoms are grouped as local (primary tumor) symptoms, locally advanced symptoms, metastatic symptoms, and paraneoplastic syndromes. However, there is quite a bit of overlap between these groups. For example, it is entirely possible for someone with metastatic lung cancer to have symptoms from all three categories or to have only local symptoms. About 10 % of patients are asymptomatic and diagnosed incidentally from a routine chest X-ray.

1. Primary tumor.

Endobronchial location of the tumor explains many of the symptoms related to primary tumor. If the primary is peripheral and the lesion is in the lung, often the symptoms related to primary tumor are absent.

Cough

Cough is the most common presenting symptom of lung cancer. Over 50 % of people with lung cancer have a cough at the time of diagnosis. In non-smokers and long-term former smokers, the cough is usually new and persistent. In people who already have lung disease such as chronic obstructive pulmonary disease (COPD) or emphysema, it is often a change in their usual cough that heralds a diagnosis of lung cancer. Therefore, a change in a pre-existing cough should never be ignored.

Dyspnea (breathlessness)

Dyspnea is a frequent symptom, which may be caused by tumor obstruction of the bronchus, pleural effusion, diaphragmatic paralysis resulting from phrenic nerve involvement, obstructive pneumonitis or lymphangitic metastases. In addition, lung cancer patients often have coexistent COPD that contributes to their dyspnea.

Hemoptysis is due to microvascular rupture. As the tumor grows, areas of necrosis may develop, resulting in bleeding. However massive hemoptysis is a rare event.

Chest pain

Chest pain may be present in patients with tumors invading the pleura or chest wall.

Fever

With continued tumor growth, airways may become obstructed, resulting in atelectasis, pneumonia and, occasionally, abscess formation. These obstructive complications often result in fevers and the signs and symptoms of pulmonary infection.

Generally, typical symptoms from **centrally located lung cancer** include haemoptysis, cough, dyspnea and fever due to frequent lung infections. **Peripheral lesion** may be manifested by chest pain, rarely cough and dyspnea.

2. Locally advanced symptoms

The symptoms associated with locally advanced disease are due to invasion of structures in or near the lungs, or from cancerous spread to regional lymph nodes. New onset hoarseness that does not improve or go away can be caused by a cancerous lung tumor that involves recurrent laryngeal nerve controlling the vocal cords. Difficulty swallowing or dysphagia can be caused by regional lymph node enlargement or a lung tumor pressing against the esophagus.

Horner's syndrome: tumor extension leading to sympathetic nerve paralysis and the classic presentation of ptosis (droopy eyelid), miosis (constricted pupils), enophthalmos (recession of the eyeball) and anhidrosis (not sweating).

Pancoast's syndrome is caused by a tumor in the apex of the lung, which may also involve the first and second ribs, vertebral column, spinal cord, and brachial plexus. Causes shoulder pain which often radiates in an ulna distribution to arm. This often coexists with Horner's syndrome.

Superior Vena Cava (SVC) syndrome: tumor compresses the SVC leading to backup of venous drainage and resultant edema of the face and upper extremities, along with dilated superficial veins in the neck, arms, and thorax, and dyspnea. Although these symptoms are not present in most people with regionally advanced lung cancer, their presence should lead to a suspicion of lung cancer.

3. Distant metastasis

The most common sites of metastasis are the brain, liver, bones, and adrenal glands.

Symptoms of brain metastases

The symptoms of lung cancer that has spread to the brain vary depending on the size, location, and number of tumors present. Severe headaches, uncontrollable vomiting, and seizures are symptoms associated with increased pressure in the brain that can be caused by a growing tumor and/or brain swelling. Weakness or paralysis that is limited to a specific area of the body may indicate a tumor in the area of the brain that controls the affected part of the body. Changes in vision, difficulty speaking or swallowing, loss of balance or coordination, and confusion are all possible symptoms associated with metastatic brain disease.

Symptoms of bone metastases

Pain is the most common symptom associated with bone metastases from lung cancer. The pain can range from mild to severe. Any bone in the body can be involved in lung cancer spread. Bone pain that is not associated with a recent injury or fall is particularly suggestive of possible metastatic disease. Some patients are diagnosed with lung cancer after experiencing a pathological bone fracture. A pathological fracture is a bone break that occurs because a tumor has eroded away the involved bone. These fractures typically occur without any history of a fall or an impact, or are associated with a minor impact that would not normally cause a bone to break.

Symptoms of liver metastases

The liver is enclosed in a capsule that has little capacity to expand. Therefore, tumors in the liver that stretch this capsule cause pain. The pain is typically located on the right side of the body in the area below the ribs. If the tumors interfere with the function of the liver, there can be many other symptoms associated with liver metastases from primary lung cancer.

Symptoms of adrenal metastases

Adrenal metastases from primary lung cancer are often silent, meaning they do not produce symptoms. The most common symptom associated with adrenal metastases is pain caused by tumor growth or sudden bleeding into the gland. The pain is typically located in the back, around waist-level, to the right or left of the spine depending upon the location of the tumor.

4. Paraneoplastic syndromes.

These are signs and symptoms of the disease that are not caused by the tumors themselves, but by substances produced by the tumors. These syndromes can affect several organs of the body, and cause a wide variety of signs and symptoms. It may present:

1. Unknown etiology (cachexia, weight loss).
2. endocrine abnormalities which may be due to tumor production of hormones (such as cushing's, addison's syndromes).
3. immunologic syndromes (nephrotic syndrome).
4. skeletalconnective tissue syndromes such as Lambert-Eaton myasthenic syndrome.

TNM-classification in lung cancer (Tables 1, 2)

Table 1 — TNM classification in lung cancer

T: Primary tumor		
TX	Any of:	Primary tumor cannot be assessed
		Tumor cells present in sputum or bronchial washing, but tumor not seen with imaging or bronchoscopy
T0	No evidence of primary tumor	
Tis	Carcinoma in situ	
T1	Tumor size less than or equal to 3 cm across, surrounded by lung or visceral pleura, without invasion proximal to the lobar bronchus	

T1a	Tumor size less than or equal to 2 cm across	
T1b	Tumor size more than 2 cm but less than or equal to 3 cm across	
T2	Any of:	Tumor size more than 3 cm but less than or equal to 7 cm across
		Involvement of the main bronchus at least 2 cm distal to the carina
		Invasion of visceral pleura
		Atelectasis/obstructive pneumonitis extending to the hilum but not involving the whole lung
T2a	Tumor size more than 3 cm but less than or equal to 5 cm across	
T2b	Tumor size more than 5 cm but less than or equal to 7 cm across	
T3	Any of:	Tumor size more than 7 cm across
		Invasion into the chest wall, diaphragm, phrenic nerve, mediastinal pleura or parietal pericardium
		Tumor less than 2 cm distal to the carina, but not involving the carina
		Atelectasis/obstructive pneumonitis of the whole lung
		Separate tumor nodule in the same lobe
T4	Any of:	Invasion of the mediastinum, heart, great vessels, trachea, carina, recurrent laryngeal nerve, esophagus, or vertebra
		Separate tumor nodule in a different lobe of the same lung
N: Lymph nodes		
NX	Regional lymph nodes cannot be assessed	
N0	No regional lymph node metastasis	
N1	Metastasis to ipsilateral peribronchial and/or hilar lymph nodes	
N2	Metastasis to ipsilateral mediastinal and/or subcarinal lymph nodes	
N3	Any of:	Metastasis to scalene or supraclavicular lymph nodes
		Metastasis to contralateral hilar or mediastinal lymph nodes
M: Metastasis		
MX	Distant metastasis cannot be assessed	
M0	No distant metastasis	
M1a	Any of:	Separate tumor nodule in the other lung
		Tumor with pleural nodules
		Malignant pleural or pericardial effusion
M1b	Distant metastasis	

The regional lymph nodes of the chest are divided into three major areas, the hilar lymph nodes, the mediastinal lymph nodes, and the supraclavicular lymph nodes. The trachea splits into the right and left main bronchus in the mediastinum. The main bronchus enters the lung at the hilum. The lymph nodes in this area are called the hilar lymph nodes; these lymph nodes are located within the lung. The mediastinal lymph nodes are located in the middle of the chest, in and around the trachea and the esophagus. The mediastinal lymph nodes are located outside of the lungs. The supraclavicular lymph nodes are those just above the collarbones. Cancer in lymph nodes beyond the hilar, mediastinal, and supraclavicular lymph nodes is considered evidence of distant metastasis.

Table 2 — Stage group according to TNM classification in lung cancer

TNM	Stage group
T1a–T1b N0 M0	IA
T2a N0 M0	IB
T1a–T2a N1 M0	IIA
T2b N0 M0	

TNM	Stage group
T2b N1 M0	IIB
T3 N0 M0	
T1a–T3 N2 M0	IIIA
T3 N1 M0	
T4 N0–N1 M0	
N3 M0	IIIB
T4 N2 M0	
M1	IV

Diagnosis

1. Medical history

- personal smoking history;
- any problems with lungs in the past;
- when current symptoms started, and how they have changed over time;
- job history and/or exposure to potential lung carcinogens, and;
- a family history of lung cancer or other epithelial cell cancers.

2. Physical examination

Important physical findings include:

- fever;
- abnormal breath sounds in the lungs;
- swollen lymph nodes;
- tenderness and/or enlargement of the liver;
- tenderness in the flank area (over the kidney);
- swelling in the hands, feet, face, or ankles;
- tenderness over any bones;
- generalized or regional muscle weakness;
- skin changes such as rashes, dark areas, or a blue tint of the lips and nails;
- any findings that might indicate a primary tumor in a body organ other than the lungs.

3. Sputum cytology

A sputum cytology test may be performed when lung cancer is suspected. A sample of sputum is collected first thing in the morning. Sputum is the thick, slippery fluid secreted by the airways. The sample must come from deep in the lungs, so it must be produced by a deep cough. The sputum is placed on slides and stained in the laboratory. The slides are then examined under a microscope. The technologist examining the slides looks for cancer cells that may be contained in the sputum. Bacteria and other abnormal cells may also be seen. When cancer cells are seen in a sputum cytology specimen, it is almost certain there is cancer in the lungs. However, if cancer cells are not detected, this does not rule out the possibility of lung cancer because sputum cytology is positive in only 5–20 % of people with lung cancer.

4. Tumor markers

Carcinoembryonic antigen (CEA) is a tumor marker that is sometimes measured when lung cancer is suspected. However, CEA is elevated in several cancers, not just lung cancer. Therefore, an elevated CEA does not necessarily mean lung cancer is present. The interpretation of an elevated CEA level is further complicated by the fact that smokers often have abnormally high CEA levels.

5. Chest X-rays

Tumors must be at least 1 cm in greatest diameter to be detectable by chest X-rays. A chest X-ray is best at detecting peripherally located cancers. Chest X-rays also allow evaluation of the anatomical extent of the tumor, including mediastinal metastases, chest wall involvement, metastases to the ribs, tracheal compression, pleural effusion, and atelectasis.

6. CT scans

CT scans (computerized tomographic scans) are x-ray imaging tests that may be used in the diagnostic work-up of suspected lung cancer. CT scans are able to detect smaller tumors than chest x-rays. They are also better able to determine the size, shape, and exact location of a tumor because they collect information in three dimensions instead of two. For the same reasons, CT scans are better able to detect enlarged regional lymph nodes.

7. MRI scans

MRI scans (magnetic resonance imaging scans) use a large magnet instead of x-rays to produce three-dimensional images. MRI is not often used in the routine work-up of suspected lung cancer. In special circumstances, MRI may be used to study a particular area that may be difficult to interpret on a CT scan such as the diaphragm or the uppermost part of the lung. However, in most instances, CT is superior to MRI for imaging the structures in the chest.

8. PET scans

PET (positron emission tomography) scanning is a relatively new technology. Sugar molecules that have a radioactive component are injected into the body and then a scan is taken. The amount of radiation used for these scans is very low. Cancer cells take up more sugar than normal cells because they are growing and dividing rapidly. Therefore, areas of the body with cancer cells show up brighter on the scan than normal tissues. Primary tumors, lymph nodes containing cancer cells, and metastatic tumors all appear as bright spots on a PET scan.

PET scans are not generally used as first-line diagnostic tests for lung cancer. They are sometimes used after chest X-rays or CT scans to differentiate between benign and cancerous tumors. PET scans are particularly useful for finding cancerous spread to regional lymph nodes and detecting distant metastatic tumors. However, there are conditions other than cancer that cause positive findings on PET scans. PET scan findings should be interpreted cautiously and correlated with other test results.

9. Bronchoscopy

The introduction of the flexible fiber optic bronchoscope has enabled the diagnosis of lung cancer to be made by a procedure that albeit invasive, is fast, safe, and performed under local anesthesia. Using the flexible scope the endobronchial distance that may be visualized has been extended to include third and fourth order bronchi. If lung lesions are visible, the rate of positive diagnoses from bronchial brushings and biopsy is up to 90 %, the success rate depending on the size of the tumor. Small cell carcinoma has a tendency to cause submucosal invasion, so a deep biopsy should be performed, and this is also necessary in areas with swollen mucosa without visible tumor. To obtain material from intrapulmonary lesions and mediastinal lymph nodes, transbronchial biopsy aspiration, sometimes ultrasound guided, should be carried out using special needles.

Autofluorescence bronchoscopy is a modified bronchoscopy procedure that uses fluorescent light to detect potentially cancerous areas of the airways. Tumors and other abnormal cells naturally glow when exposed to specific types of fluorescent light. This technique helps the doctor identify suspicious areas in the airways to sample. Autofluorescence bronchoscopy is particularly useful for patients whose sputum cytology test showed cancer cells, but imaging studies failed to show a lung tumor. Autofluorescence bronchoscopy is also better than standard bronchoscopy for detecting lesions that may be progressing to lung cancer.

10. Mediastinoscopy

Mediastinoscopy is a surgical procedure in which a rigid instrument called an endoscope is inserted through a small incision at the base of the neck or near the breastbone into the mediastinum. The mediastinum contains the heart, the large blood vessels entering and leaving the heart, the trachea, the esophagus, and several lymph nodes that drain lymph fluid from the lungs. Mediastinoscopy is often used for both diagnosis and staging because sampling the lymph nodes of the mediastinum is an important part of determining lung cancer stage. Mediastinoscopy is usually performed as a diagnostic test in people who have centrally located lung tumors that can be reached from the mediastinum. Biopsies of the primary tumor and mediastinal lymph nodes are taken during the procedure. Mediastinoscopy is performed under general anesthesia.

11. Transthoracic needle biopsy

Transthoracic needle biopsies are usually reserved for people who have tumors near the surface of the lung that would be difficult to reach by bronchoscopy. Transthoracic needle biopsy is sometimes called fine needle aspiration (FNA) biopsy. In this procedure, a needle is inserted through the chest wall into the lung tumor. Small tissue samples are collected through the needle. This procedure is performed using either computerized tomography (CT) or fluoroscopy (another x-ray technique) to help the doctor direct the needle into the precise location of the tumor. Local anesthesia is used to numb the skin where the needle is inserted, and a mild sedative is used to relax the patient.

12. Thoracoscopy

Thoracoscopy is another surgical procedure in which an endoscope is inserted into the chest space. Thoracoscopy has limited use in lung cancer diagnosis, but is sometimes used to biopsy a suspicious tumor and regional lymph nodes. Thoracoscopy has the advantages of allowing the surface of the lung to be examined and permitting sampling of any pleural effusion that may be present.

Video-assisted thoracoscopy (VATS) is technique in which a tiny video camera is inserted into the chest by a small incision separate from the incision used for the thoracoscope. Pictures of the chest cavity are projected onto a screen during the procedure to give the surgeon a better view of the area. VATS and routine thoracoscopy procedures are performed under general anesthesia.

13. Thoracotomy

In rare instances, doctors are unable to biopsy a suspicious lung tumor using the already mentioned techniques. In these situations, a thoracotomy may be performed. A thoracotomy is major surgery performed under general anesthesia. The chest is opened and the rib cage is separated to expose the lungs. A biopsy of the tumor is performed and the tissue is examined under the microscope while the patient is still in the operating room. If cancer is found, the surgeon will sample regional lymph nodes to determine if a surgical cure is possible. Again, the lymph nodes are examined while the patient is still in the operating room. If surgical cure is possible, a potentially curative operation will be performed.

14. Bone marrow biopsy

The bone marrow can be evaluated by aspiration and biopsy from the iliac crest — routine procedures in small cell carcinoma.

15. Bone scans is procedure to detect secondary bone lesions.

16. Central nervous system metastases can be revealed by a thorough clinical neurological examination, lumbar puncture with cytological evaluation of the cerebrospinal fluid and supplemented by myelography, CT, and MRI, depending on the clinical signs and symptoms.

17. The presence of liver and adrenal metastasis are evaluated by ultrasonography.

Treatment

Only about 15 % of lung cancers are diagnosed in the early stages when lung cancer is likely to be cured with surgical treatment.

1. Non-Small Cell cancer: standard care is surgery for stage I–IIIA. In some cases chemotherapy and radiotherapy are also given, before and/or after surgery.

Types of lung surgery:

— Lobectomy: right lung has three lobes, and left lung has two lobes. A lobectomy removes an entire lobe of lung containing the tumor and regional lymph nodes.

— Pneumonectomy: a pneumonectomy removes an entire lung containing the lung mass and regional lymph nodes. This is only done when absolutely necessary, as it will likely reduce lung function.

2. *Small Cell cancer*: tends to be very aggressive. Surgery is not typically performed. The mainstay of treatment is chemotherapy. Small cell lung cancers generally respond very well to chemotherapy, but recur at very high rates. Radiation is also given concurrently with chemotherapy for limited-spread disease to help shrink the rapidly growing tumor and reduce symptoms.

The concept of palliation is especially important in lung cancer. This is a major goal of chemotherapy (and sometimes radiation) for advanced stages of lung cancer, beyond just the usual hard endpoints of survival and response rates. Outcomes of interest in palliation include quality of life, effective treatment of pain and symptoms, such as dyspnea, hemoptysis, cough or paraneoplastic syndromes.

Prevention

Eliminating tobacco smoking is a primary goal in the prevention of lung cancer, and smoking cessation is an important preventive tool in this process.

Prognosis

The 5-year survival rate of patients with non-small cell cancer varies by stage, from 60 to 70 % for patients with stage I disease to < 1 % for patients with stage IV disease. On average, untreated patients with metastatic non-small cell cancer survive 6 month, whereas the median survival for treated patients is about 9 month. The overall prognosis for small cell cancer is poor. The median survival time for limited-stage small cell cancer is 20 month, with a 5-year survival rate of 20 %. Patients with extensive-stage small cell cancer do especially poorly, with a 5-year survival rate of < 1 %.

LARYNGEAL CANCER

Introduction

Laryngeal cancer is the second most common respiratory cancer, after lung cancer. It accounts for 1,6–2 % of all malignant tumors in men, and 0,2–0,4 % in women. Its incidence is increasing in much of the world, being slightly higher in urban than in rural areas. It is also higher among blacks than whites. Laryngeal cancer occurs most frequently in the sixth and seventh decades of life. It rarely occurs in children and adolescents. It is more common in men, with a male: female ratio of about 5:1 worldwide, although more women are developing it today due to an increase in smoking in the female population.

The larynx is anatomically divided into three compartments: supraglottis (epiglottis, aryepiglottic folds, false vocal cords, and the ventricles), glottis (true vocal cords) and subglottis (between the glottis and the trachea).

There are geographic differences in the topographic distribution of the laryngeal cancer. In France, Spain, Italy, Finland and the Netherlands, supraglottis cancer predominates, while in the USA, Canada, UK and Sweden glottis cancer is more common. In Japan, laryngeal cancer is approximately equally distributed between the two sites. The rarest location of laryngeal cancer is the subglottis (1–5%).

Etiology

1. Smoking: the risk of laryngeal cancer increases up to 30 times for smokers. The heavier the person smokes, the higher the risk.

2. Alcohol: heavy drinkers more than double their risk for this type of cancer, and combining smoking with alcohol can increase the risks even more than either drinking or smoking alone.

3. Gastroesophageal reflux disease (GERD): in GERD, the stomach acid backs up into the esophagus, causing a burning pain. Although not definitively proven, researchers have found that irritation from longstanding GERD is related to higher chances of laryngeal cancer.

4. Poor nutrition: many people who abuse alcohol also have poor nutritional habits, but some research also suggests that not getting enough vitamins might be a risk factor.

5. Human papillomavirus (HPV).

6. Gender: more men than women are diagnosed with cancer of the larynx.

7. Age: this type of cancer is usually detected in people between 50 and 75 years old.

8. Weakened immune system: people with weak immune systems (due to diseases such as AIDS or medications that lower immunity to viruses) are more susceptible to laryngeal cancer.

9. Toxic exposure: these risk factors include being exposed to wood dust, asbestos, or many types of chemicals that can increase the chances of cancer.

10. Voice overuse: people, who use their voices a lot, such as singers, may develop polyps (lumps of tissue) that can become cancerous if not removed.

Histological types

The most common histological types of the laryngeal cancers is squamous cells carcinoma.

Neuroendocrine carcinoma, adenocarcinoma, sarcomas, lymphoma are uncommon histological types of the tumor of the larynx.

Signs and symptoms

The symptoms of laryngeal cancer depend on where in the larynx the tumor is located.

The most common location of **supraglottis carcinoma** is the epiglottis (45–55 % of supraglottis cancer), followed by the false vocal cords (12–33 %)

and the aryepiglottic folds (8–21 %). The remaining cases arise from the ventricles and the arytenoids. Supraglottis carcinoma tends to spread to oropharynx and pyriform sinus, but it rarely invades the glottis and thyroid cartilage.

The most common symptoms in supraglottis carcinoma are:

- a sensation of a foreign body in the throat,
- change in the quality of the voice,
- referred otalgia.

Dysphagia and dyspnoea occur later.

Lymph node metastases are present in 30–40 % of patients.

Glottis carcinoma arises mostly from the anterior half of the vocal cord or from the anterior commissure; a posterior origin is rare. Because of poor lymphatic supply, glottis carcinoma tends to remain located for a long period. As cancer progresses, it invades the vocal muscle resulting in the fixed vocal cord, which is an ominous clinical sign. In the late stages of the disease, it may extend to the opposite true vocal cord, to the supraglottis and subglottis; it may also extend through the thyroid cartilage and invade the soft tissue of the neck.

The most common early symptom in glottis carcinoma is *hoarseness*. Other symptoms include dysphagia, change in the quality of the voice, a sensation of a foreign body in the throat, haemoptysis and odynophagia. The incidence of lymph node metastases in the early stages is low (0–11 % for T1 and T2) and increases to 14–40 % in the advanced stages.

Subglottis carcinoma is rare. The most common presenting symptoms are *dyspnea and stridor*, often requiring an emergency tracheotomy. The subglottis carcinoma may spread to the thyroid gland, cervical oesophagus, hypopharynx and trachea. About 20–25 % of patients have cervical lymph node metastases at presentation, but about 50 % of patients have clinically undetectable metastases in the paratracheal lymph nodes. It has therefore been suggested that paratracheal and superior mediastinal nodes should be removed in patients with subglottis cancer.

Diagnosis

Diagnosis includes determining the stage of the cancer in order to identify how advanced it is.

Physical exam of the throat and neck: inspection of head and neck region for tenderness or swelling, palpation of the submandibular, neck, and supraclavicular

regions for lymph nodes, mirror examination of the larynx.

Laryngoscopy (direct endoscopy) each lesion is characterized size, color, texture, and outline, and take biopsy.

Both computed tomography (CT) and magnetic resonance imaging (MRI) are highly sensitive for the detection of neoplastic invasion of the larynx.

The appropriate nodal (N) drainage areas are examined by careful palpation and imaging (ultrasonography (US), CT scan). US combined with fine-needle

aspiration cytology for the evaluation of lymph node metastasis in patients with laryngeal cancer.

The presence of distant metastasis (M) is evaluated by chest radiography and/or CT scan of the thorax, US of the liver, and bone scintigraphy; PET can also show distant metastatic disease.

TNM-Classification in Laryngeal cancer

1. Rules for Classification

The classification applies only to carcinomas. There should be histological confirmation of the disease.

The following are the procedures for assessing T, N, and M categories:

T categories. Physical examination, laryngoscopy, and imaging.

N categories. Physical examination and imaging.

M categories. Physical examination and imaging.

2. Anatomical Sites and Subsites

- **Supraglottis**
- **Glottis**
 - I. Vocal cords
 - II. Anterior commissure
 - III. Posterior commissure
- **Subglottis**

3. Regional Lymph Nodes

The regional lymph nodes are the cervical nodes.

4. TNM Clinical Classification

4.1. T-Primary Tumor

TX. Primary tumor cannot be assessed

T0. No evidence of primary tumor

Tis. Carcinoma in situ

4.1.1. Supraglottis

T1. Tumor limited to one subsite of supraglottis with normal vocal cord mobility

T2. Tumor invades mucosa of more than one adjacent subsite of supraglottis or glottis or region outside the supraglottis (e. g., mucosa of base of tongue, vallecula, medial wall of piriform sinus) without fixation of the larynx

T3. Tumor limited to larynx with vocal cord fixation and/or invades any of the following: postcricoid area, pre-epiglottic tissues, paraglottic space, and/or with minor thyroid cartilage erosion (e. g., inner cortex)

T4a. Tumor invades through the thyroid cartilage and/or invades tissues beyond the larynx, e. g., trachea, soft tissues of neck including deep/extrinsic muscle of tongue (genioglossus, hyoglossus, palatoglossus, and styloglossus), strap muscles, thyroid, oesophagus

T4b. Tumor invades prevertebral space, mediastinal structures, or encases carotid artery

4.1.2. Glottis

T1. Tumor limited to vocal cord(s) (may involve anterior or posterior commissure) with normal mobility

T1a. Tumor limited to one vocal cord

T1b. Tumor involves both vocal cords

T2. Tumor extends to supraglottis and/or subglottis, and/or with impaired vocal cord mobility

T3. Tumor limited to larynx with vocal cord fixation and/or invades paraglottic space, and/or with minor thyroid cartilage erosion (e. g. inner cortex)

T4a. Tumor invades through the thyroid cartilage, or invades tissues beyond the larynx, e. g., trachea, soft tissues of neck including deep/extrinsic muscle of tongue (genioglossus, hyoglossus, palatoglossus, and styloglossus), strap muscles, thyroid, oesophagus

T4b. Tumor invades prevertebral space, mediastinal structures, or encases carotid artery

4.1.3. Subglottis

T1. Tumor limited to subglottis

T2. Tumor extends to vocal cord(s) with normal or impaired mobility

T3. Tumor limited to larynx with vocal cord fixation

T4a. Tumor invades through cricoid or thyroid cartilage and/or invades tissues beyond the larynx, e.g., trachea, soft tissues of neck including deep/extrinsic muscle of tongue (genioglossus, hyoglossus, palatoglossus, and styloglossus), strap muscles, thyroid, oesophagus

T4b. Tumor invades prevertebral space, mediastinal structures, or encases carotid artery

4.2. N-Regional Lymph Nodes

NX. Regional lymph nodes cannot be assessed

N0. No regional lymph node metastasis

N1. Metastasis in a single ipsilateral lymph node, 3 cm or less in greatest dimension

N2. Metastasis in a single ipsilateral lymph node, more than 3 cm but not more than 6 cm in greatest dimension; or in multiple ipsilateral lymph nodes, none more than 6 cm in greatest dimension; or in bilateral or contralateral lymph nodes, none more than 6 cm in greatest dimension

N2a. Metastasis in a single ipsilateral lymph node, more than 3 cm but not more than 6 cm in greatest dimension

N2b. Metastasis in multiple ipsilateral lymph nodes, none more than 6 cm in greatest dimension

N2c. Metastasis in bilateral or contralateral lymph nodes, none more than 6 cm in greatest dimension

N3. Metastasis in a lymph node more than 6 cm in greatest dimension
Note: Midline nodes are considered ipsilateral nodes.

4.3. M-Distant Metastasis

MX. Distant metastasis cannot be assessed

M0. No distant metastasis

M1. Distant metastasis

5. pTNM Pathological Classification

The pT, pN, and pM categories correspond to the T, N, and M categories.

pN0. Histological examination of a selective neck dissection specimen will ordinarily include 6 or more lymph nodes. Histological examination of a radical or modified radical neck dissection specimen will ordinarily include 10 or more lymph nodes. If the lymph nodes are negative, but the number ordinarily examined is not met, classify as pN0. When size is a criterion for pN classification, measurement is made of the metastasis, not of the entire lymph node.

6. G Histopathological Grading

GX. Grade of differentiation cannot be assessed

G1. Well differentiated

G2. Moderately differentiated

G3. Poorly differentiated

G4. Undifferentiated

7. Stage Grouping (Table 3)

Table 3 — Stage grouping

Stage 0	Tis	N0	M0
Stage I	T1	N0	M0
Stage II	T2	N0	M0
Stage III	T1, T2	N1	M0
	T3	N0, N1	M0
Stage IVA	T1, T2, T3,	N2	M0
	T4a	N0, N1, N2	M0
Stage IVB	T4b	Any N	M0
	Any T	N3	M0
Stage IVC	Any T	Any N	M1

8. Summary

Larynx

Supraglottis

T1 — Onesubsite, normalmobility

T2 — Mucosa of more than one adjacent subsite of supraglottis or glottis or adjacent region outside the supraglottis; without fixation

T3 — Cord fixation or invades postcricoid area, pre-epiglottic tissues, paraglottic space, thyroid cartilage erosion

T4a — Through thyroid cartilage; trachea, soft tissues of neck: deep/extrinsic muscle of tongue, strap muscles, thyroid, oesophagus

T4b — Prevertebral space, mediastinal structures, carotid artery

Glottis

T1 — Limited to vocal cord(s), normal mobility

a. one cord

b. both cords

T2 — Supraglottis, subglottis, impaired cord mobility

T3 — Cord fixation, paraglottic space, thyroid cartilage erosion

T4a — Through thyroid cartilage; trachea, soft tissues of neck: deep/extrinsic muscle of tongue, strap muscles, thyroid, oesophagus

T4b — Prevertebral space, mediastinal structures, carotid artery

Subglottis

T1 — Limited to subglottis

T2 — Extends to vocal cord(s) with normal/ impaired mobility

T3 — Cord fixation

T4a — Through cricoid or thyroid cartilage; trachea, deep/extrinsic muscle of tongue, strap muscles, thyroid, oesophagus

T4b — Prevertebral space, mediastinal structures, carotid artery

All Sites

N1 — Ipsilateral single ≤ 3 cm

N2 — (a) Ipsilateral single >3 to 6 cm

(b) Ipsilatera lmultiple ≤ 6 cm

(c) Bilateral, contralateral ≤ 6 cm

N3 — > 6 cm

Treatment

Treatment choices depend on patient characteristics (age, comorbidities) and preferences, tumor characteristics.

Surgery

Transoral CO2 laser is a widely accepted approach for early diseases pending an excellent endoscopic access and a complete view of the tumor in all directions. *Open partial surgery* ranges from very limited resections (such as cordectomy, epiglottectomy, or lateral pharyngectomy) to large resections (such as supracricoid partial laryngectomy or supracricoid hemi-laryngopharyngectomy) allowing the surgeon to cope with all local extensions.

Total laryngectomy is required for large tumors and may be associated with either partial or circumferential pharyngectomy, requiring either pedicled or free flaps for closure. A neck dissection is systematically performed (except for tumors confined to true vocal cords).

Radiation and chemotherapy

For early-stage tumors (T1–N0), a standard fractionation regimen delivering a therapeutic dose of 64–66 Gy and a prophylactic neck dose in the order of

50 Gy in daily fractions of 2 Gy, five times a week is recommended. For T1 glottic carcinoma, a dose of 60–64 Gy to the glottic larynx without nodal irradiation is standard. For moderately advanced tumors (T2–N0 or N1), hyperfractionation or accelerated fractionation schedules have shown to be more effective than standard radiotherapy. For these tumor stages, there is no compelling evidence for the use of induction or concomitant systemic treatment (chemotherapy or biotherapy). For locally advanced disease (T3 or T4, more than N1), a therapeutic dose of 70 Gy in daily fractions of 2 Gy, five times a week, and a prophylactic dose of 50 Gy are recommended, in particular when concomitant chemotherapy or biotherapy is used. In case of contraindication to systemic treatment, the use of hyperfractionation, accelerated fractionation, or simultaneous integrated boost radiation therapy is recommended.

Post-operative radiation therapy (RT) is recommended in the case of inadequate resection margins, T3 or T4 tumor, multiple positive lymph nodes, and in the case of extracapsular spread of disease. Typically, a dose of 60–66 Gy will be delivered with daily fractions of 2 Gy, five times a week. In case of R1 resection and/or presence of extracapsular extension, the use of concurrent/concomitant chemoradiation therapy (CCRT) has been demonstrated to be superior to radiation alone.

The use of CCRT is generally accepted as a standard therapy post-surgery in high-risk patients, in patients with resectable disease, when the anticipated functional outcome and/or prognosis is so poor that mutilating surgery is not justified, and in patients with unresectable disease. The optimal chemotherapy regimen for that approach is cisplatin 100 mg/m² days on 1, 22, and 43 during RT.

Voice loss: Treatment that involves removing the entire larynx makes normal speech impossible. In this case, alternate methods of speaking need to be learned.

These are:

- esophageal speech: This is the most basic form of alternate speech, which is done by swallowing air and creating sound by expelling it;
- tracheoesophageal puncture (TEP): A small one-way valve is placed between the trachea and esophagus. By taking in air through their stoma into the lungs, then covering their stoma (from the tracheostomy), sounds can be made through the mouth;
- electrolarynx: When patient holds electronic device next to the skin of the throat or the corner of the mouth, it produces a mechanical voice. Muscle movements stimulate the machine to make sounds.

While these new methods of speech are being learned, other ways of communicating will be needed. This might mean keeping a "magic slate" or pad and pencils easily available. It's important to plan ahead to help avoid frustration after surgery.

Prognosis

Prognosis depends on the following:

- ✓ the stage of the disease;
- ✓ the location and size of the tumor;
- ✓ the grade of the tumor;
- ✓ the patient's age, gender, and general health

Smoking tobacco and drinking alcohol decrease the effectiveness of treatment for laryngeal cancer. Patients with laryngeal cancer who continue to smoke and drink are less likely to be cured and more likely to develop a second tumor. After treatment for laryngeal cancer, frequent and careful follow-up is important.

The five-year survival rate for laryngeal cancer that's detected early is usually 80 % or more. The overall 5-year survival rate in supraglottis cancer is 65–75 %, glottis cancer rate is 80–85 %, in subglottic cancer is 40–47 %.

Most recurrences of cancer happen within the first 2 or 3 years of treatment. Follow-up procedures usually involve monthly checkups for the first year and then every few months thereafter. Unfortunately, because the very same risk factors that might have caused the first tumor may also have caused other damage, the chances of a second tumor developing (often in the head, neck, or lung) can be as high as 25 %.

Prevention

Many risk factors for cancer of the larynx are known, the most common of these being smoking and heavy alcohol use. Many cases of cancer could be prevented by avoiding these known causes.

Other ways to reduce risk include:

- using respirators when in industrial areas with cancer-causing chemicals;
- getting treatment for GERD;
- eating a healthy and balanced diet.

QUESTIONS

1. Epidemiology, etiological agents, histological types of lung cancer.
2. Local spread and metastasis of lung cancer.
3. Signs and symptoms of central and peripheral cancer.
4. Features of bronchioloalveolar carcinoma.
5. Pancoast's syndrome.
6. Diagnosis of lung cancer.
7. Treatment of lung cancer, prognosis.
8. Prevention of lung cancer.
9. Epidemiology, etiological agents of laryngeal cancer.
10. Local spread and metastasis of laryngeal cancer.
11. Signs and symptoms of laryngeal cancer.
12. Diagnosis of laryngeal cancer.
13. Treatment of laryngeal cancer, prognosis.
14. Prevention of laryngeal cancer.

REFERENCES

1. *DeVita, V. T. Cancer: Principles & Practice Of Oncology* / V. T. DeVita, S. Helliman, S. A. Rosenberg. — 7th Edition. — Lippincott Williams & Wilkins, 2004. — 3120 p.
2. Saijo, C. J. H., G., van de V. D., & Haller; David J. Kerr; Michael Baumann; Nagahiro. (2016). *Oxford Textbook of Oncology*. (D. J. Kerr, D. G. Haller, C. J. H. van de Velde, & M. Baumann, Eds.), *Oxford Textbook of Oncology* (3rd ed.). Oxford University Press. <https://doi.org/10.1093/med/9780199656103.001.0001>
3. *Cardesa, A. Pathology of the head and neck* / A. Cardesa, P. J. Slootweg. — Springer, 2006. — 316 p.

Учебное издание

Нестерович Татьяна Николаевна
Михайлов Игорь Викторович

РАК ЛЕГКОГО. РАК ГОРТАНИ
(на английском языке)

Учебно-методическое пособие
для студентов 5 и 6 курсов факультета по подготовке специалистов
для зарубежных стран медицинских вузов

Редактор **Т. М. Кожемякина**
Компьютерная верстка **Ж. И. Цырыкова**

Подписано в печать 12.09.2017.
Формат 60×84^{1/16}. Бумага офсетная 80 г/м². Гарнитура «Таймс».
Усл. печ. л. 1,4. Уч.-изд. л. 1,53. Тираж 60 экз. Заказ № 453.

Издатель и полиграфическое исполнение:
учреждение образования «Гомельский государственный медицинский университет».
Свидетельство о государственной регистрации издателя,
изготовителя, распространителя печатных изданий № 1/46 от 03.10.2013.
Ул. Ланге, 5, 246000, Гомель