

МИНИСТЕРСТВО ЗДРАВООХРАНЕНИЯ РЕСПУБЛИКИ БЕЛАРУСЬ
УЧРЕЖДЕНИЕ ОБРАЗОВАНИЯ
«ГОМЕЛЬСКИЙ ГОСУДАРСТВЕННЫЙ МЕДИЦИНСКИЙ УНИВЕРСИТЕТ»

Кафедра оториноларингологии с курсом офтальмологии

Л. В. ДРАВИЦА, А. АЛЬХАДЖ ХУСЕЙН,
О. П. САДОВСКАЯ

КЛИНИЧЕСКИЕ МЕТОДЫ ИССЛЕДОВАНИЯ ОРГАНА ЗРЕНИЯ

Учебно-методическое пособие
для студентов 4–6 курсов лечебного факультета
и факультета по подготовке специалистов для зарубежных стран
медицинских вузов

CLINICAL METHODS FOR OCULAR EXAMINATION

Teaching guide
for 4–6th year of the faculty of general medicine
and faculty of general medicine for overseas students

Гомель
ГомГМУ
2017

УДК 617.7-07(072)

ББК 56.7я7

Д 72

Рецензенты:

кандидат медицинских наук, доцент,
заведующая кафедрой офтальмологии
Витебского государственного ордена Дружбы народов
медицинского университета

М. В. Морхат;

кандидат медицинских наук, доцент,
заведующая хирургическим отделением
консультативной поликлиники Республиканского научно-практического
центра радиационной медицины и экологии человека

Т. В. Бобр

Дравица, Л. В.

Д 72 Клинические методы исследования органа зрения: учеб-метод. пособие
для студентов 4–6 курсов лечебного факультета и факультета по
подготовке специалистов для зарубежных стран медицинских вузов =
Clinical Methods for Ocular Examination: Teaching guide for 4–6th year of
the faculty of general medicine and faculty of general medicine for over-
seas students / Л. В. Дравица, А. Альхадж Хусейн, О. П. Садовская. —
Гомель: ГомГМУ, 2017. — 44 с.

ISBN 978-985-506-926-4

Учебно-методическое пособие подготовлено для проведения практических
занятий по офтальмологии в медицинских вузах и составлено в соответствии с
учебной программой и требованиями образовательного стандарта.

Предназначено для студентов 4–6 курсов лечебного факультета и факультета
по подготовке специалистов для зарубежных стран медицинских вузов.

Утверждено и рекомендовано к изданию научно-методическим советом
учреждения образования «Гомельский государственный медицинский универси-
тет» 28 февраля 2017 г., протокол № 1.

УДК 617.7-07(072)

ББК 56.7я7

ISBN 978-985-506-926-4

© Учреждение образования
«Гомельский государственный
медицинский университет», 2017

CONTENTS

1. General principles of ophthalmic examination	4
2. General physical and systemic examination	5
2.1. External examination	5
2.2. Visual acuity.....	8
2.3. Determination of refractive error	12
2.4. Binocular vision.	14
2.5. Color vision testing	17
2.6. Visual field testing.	18
2.7. Visual field loss.....	21
3. Anterior segment examination	24
3.1. Slitlamp biomicroscopy of anterior segment and fundus.	24
3.2. Types of illumination	25
3.3. Direct ophthalmoscopy	31
3.4. Indirect ophthalmoscopy	34
4. Intraocular pressure (IOP) measurements for glaucoma or hypotony....	34
5. Tear film adequacy: clinical tests.....	36
6. Corneal sensitivity (esthesiometry).....	37
7. Exophthalmometry	38
8. Gonioscopy.....	39
9. Keratometry.....	40
10. Corneal topography	40
11. Corneal pachymetry	41
12. Fluorescein and indocyanine green (ICG) angiography of the fundus	42
13. Ultrasonography (echography).....	42
14. Optical coherence tomography (OCT).....	43
References	44

1. GENERAL PRINCIPLES OF OPHTHALMIC EXAMINATION

Physical examination and evaluation of the ocular system are greatly facilitated by a detailed history and a number of techniques that are performed in the office using equipment readily available through any optical or medical supply house. However, a specialist in a hospital setting must perform some of the more complicated techniques. These techniques are discussed with a view to (a) their indications, (b) how they are performed, so that the referring examiner can explain to a patient what might be expected, and (c) the necessary information to aid the examiner in management of the patient.

ORDER OF EXAMINATION

Examination of the eye and its surrounding tissues with and without special aids may give valuable information for the diagnosis and treatment of ocular disease. After acquiring the ophthalmic history, a systematic routine should be adopted for the examination, with particular attention paid to the patient's chief complaint. Additional tests may be required after the initial exam.

- The typical order for nonemergency examination is as follows:

History. Chief complaint; present and past ocular problems; family history of eye problems; present and past general illnesses; previous surgeries; ocular and general medications; allergies; social history. Depending on the patient's particular problem, the history may be brief or extensive.

1. Name and address. Name and address are primarily required for patient's identification. It also proves useful for demographic research.

2. Age and sex. In addition to the utility in patient's identification, knowledge of the age and sex of the patient is also useful for noting down and ruling out the particular diseases pertaining to different age groups and a particular sex.

3. Occupation. An information about patient's occupation is helpful since ophthalmic manifestations due to occupational hazards are well known, e. g.: ocular injuries and trauma due to foreign bodies have typical pattern in factory workers, lathe workers, farmers and sport persons. Computer vision syndrome is emerging as a significant ocular health problem in computer professionals. Heat cataract is known in glass factory workers. In addition, information about the patient's occupation is useful in providing ocular health education and patient's visual rehabilitation.

Chief presenting complaints of the patients should always be recorded in a chronological order with their duration.

The common presenting ocular complaints are: defective vision, watering and/or discharge from the eyes, redness, asthenopic symptoms, photophobia, burning/itching/foreign body sensation, pain (eyeache and/or headache), deviation of the eye, diplopia, and black spots in front of eyes, coloured halos, and distorted vision.

History of present illness. The patients should be encouraged to narrate their complaints in detail and the examiner should be a patient listener. While history taking, the examiner should try to make a note of the following points about each complaint: mode of onset with duration, severity, progression, accompaniment of each symptom.

History of past illness. A probe into history of past illness should be made to know: history of similar ocular complaint in the past. It's especially important in recurrent conditions such as herpes simplex keratitis, uveitis and recurrent corneal erosions. History of similar complaints in other eye is important in bilateral conditions such as uveitis, senile cataract and retinal detachment. History of trauma to eye in the past may explain occurrence of lesions such as delayed rosette cataract and retinal detachment. It is important to know about history of any ocular surgery in the past. History of any systemic disease in the past such as tuberculosis, syphilis, leprosy may sometimes explain the occurrence of present disease. History of drug intake is also important.

Family history. Efforts should be made to establish familial predisposition of inheritable ocular disorders like congenital cataract, ptosis, strabismus, corneal dystrophies, glaucoma and refractive error.

2. GENERAL PHYSICAL AND SYSTEMIC EXAMINATION

General physical and systemic examination should be carried out in each case. Sometimes it may help in establishing the aetiological diagnosis.

Ocular examination

- External ocular examination.
- Testing of visual acuity.
- Fundus examination.

2.1. External examination

A stepwise approach that includes inspection and palpation helps ensure that no details are overlooked. This process occurs automatically with increased experience.

Inspection. The inspection should take place in a well lighted room. The patient's actions and appearance should be observed for clues as to the overall health of the patient, including signs for mental, neurological, medical, and dermatological diseases. Extremities, for example, can give clues to systemic diseases, such as rheumatoid arthritis, gout, or tuberous sclerosis. The head and face should be inspected for any masses or lesions, and these should be measured and drawn if present. The face is assessed for symmetry, signs of prior trauma, and motility of facial muscles. If a neurosensory deficit is suspected, the facial nerve function is assessed by asking the patient to close eyes forcefully, to smile and show teeth, and to lift the forehead, while muscle function is also assessed. The facial nerve sensation is then tested by comparing corresponding ar-

eas of both sides of the face with fingertips or cotton wisp, testing all three trigeminal dermatomes. The facial skin is evaluated for color, moisture, tone, texture, and vascular changes.

The mouth and nose are then examined with a penlight for changes. The orbits can be evaluated for their anatomic relationship. In addition, if abnormalities are suspected, the intercanthal distance and interpupillary distance are measured with a ruler. The average pupillary distance is 61 mm. Any apparent signs of proptosis (exophthalmos) or enophthalmos should be noted and measured with an exophthalmometer. Further, the relative position and symmetry of the eyebrows are evaluated. Old photographs are an invaluable tool when abnormalities are detected to determine longstanding asymmetry and lesions. It is also important that the examiner take pictures when new findings or changes are noted.

Palpation. Tactile, temperature, and proprioceptive senses are important when feeling for abnormalities. However, the examiner should be gentle and inform the patient about the process. In general, the thumb and index fingers are used to open the eyelids. The middle fingers are used to examine the preauricular lymph nodes. Masses are recorded for shape, size, tenderness, composition, and mobility.

Bony changes of the head and face are noted. Patients with sinusitis might complain of tenderness over the maxillary and frontal sinuses that can be elicited on palpation. In elderly patients, the temporal artery is palpated to reveal tenderness and tortuosity when giant cell arteritis is suspected. Neck vessels are palpated to evaluate the carotid artery pulse and jugular vein hum. Lymph nodes are than palpated to evaluate signs of enlargement or tenderness. Preauricular, submandibular, superficial cervical, jugular, post-sternocleidomastoid, and supra-clavicular lymph nodes should be palpated.

When trauma is suspected, the orbital margins are palpated for signs of orbital fracture that include a step-off. The examiner should start laterally and proceed in a clockwise fashion, palpating along the orbital rim. It is, however, important to be certain that no globe rupture is present before doing so.

To evaluate eyelid masses, the closed eyelid is palpated gently by sliding the index fingers over the eyelid skin. Even when a mass cannot be seen, it can be felt.

In patients with epiphora, the evaluation of the lacrimal sac involves compression of the sac with the index finger or a cotton-tipped applicator to assess any refluxed material from the puncta. Mucus or mucopurulent material can be expressed and confirm an obstructed nasolacrimal duct. The color of the refluxed material should be noted. It should be noted that pressure on the globe might elicit the oculocardiac reflex with bradycardia.

Extraocular motility

Normally, the two eyeballs are symmetrically placed in the orbits in such a way that a line joining the central points of superior and inferior orbital margins just touches the cornea. Normally the visual axes of the two eyes are simultaneously directed at the same object which is maintained in all the directions of gaze (figure 1).

With the patient's head immobilized, the examiner asks the patient to look in each of the nine diagnostic positions of gaze: 1, straight ahead; 2, right; 3, upper right; 4, up; 5, upper left; 6, left; 7, lower left; 8, down; and 9, lower right. This allows the examiner to diagnose strabismus, paralysis of ocular muscles, and gaze paresis. Evaluating the six cardinal directions of gaze (right, left, upper right, lower right, upper left, lower left) is sufficient when examining paralysis of one of the six extraocular muscles. The motion impairment of the eye resulting from paralysis of an ocular muscle will be most evident in these positions (table 1). Only one of the rectus muscles is involved in each of the left and right positions of gaze (lateral or medial rectus muscle). All other directions of gaze involve several muscles.

Table 1 — The six cardinal positions of gaze and their corresponding primary extraocular muscle actions

Movement	Right Eye	Left Eye
Right	Right lateral rectus	Left medial rectus
Up and right	Right superior rectus	Left inferior oblique
Down and right	Right inferior rectus	Left superior oblique
Left	Right medial rectus	Left lateral rectus
Up and left	Right inferior oblique	Left superior rectus
Down and left	Right superior oblique	Left inferior rectus

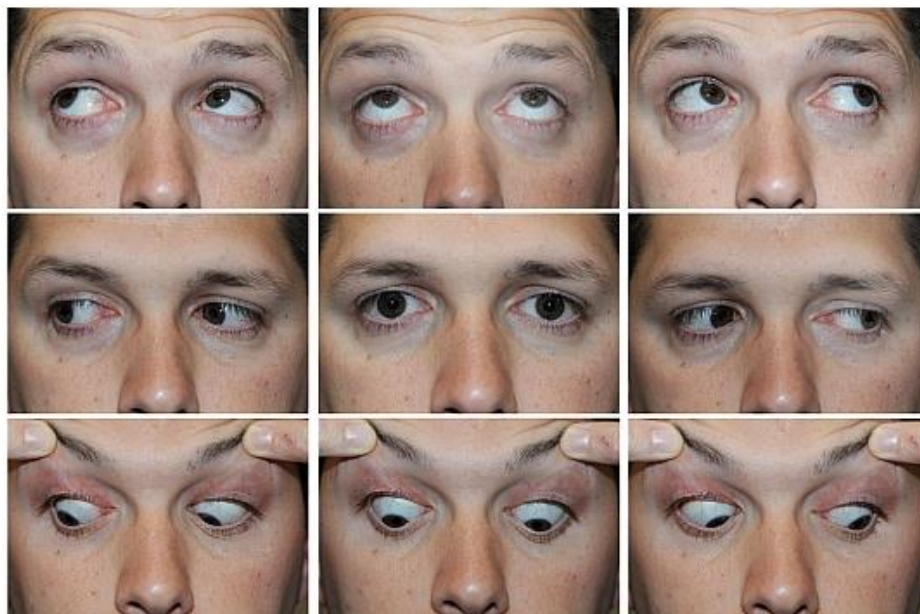

Figure 1 — Extraocular motility

Binocular alignment is evaluated with a cover test. The examiner holds a point light source beneath his or her own eyes and observes the light reflections in the patient's corneas in the near field (40 cm). The reflections are normally in the center of each pupil. If the corneal reflection is not in the center of the pupil in one eye, then a tropia is present in that eye. Then the examiner covers one eye with a hand or an occluder and tests whether the uncovered eye makes a compensatory movement. Compensatory movement of the eye indicates the presence

of tropia. However, there will also be a lack of compensatory movement if the eye is blind. The cover test is then repeated with the other eye. If tropia is present in a newborn with extremely poor vision, the baby will not tolerate the good eye being covered.

The near point of convergence (NPC) is the point closest to the patient at which both eyes converge on an object as it is brought toward the eyes. This point is normally between 6 cm and 10 cm in front of the eye. The moment one eye begins to deviate outward or the image doubles, the limit of convergence has been reached. A NPC greater than 10 cm is considered abnormal and may result in excessive tiring of the eyes on close work such as reading or sewing.

Pupillary examination. The pupil size, shape, location, and reaction to light, can be altered by numerous pathologic disorders. The examiner begins with observation of the pupil. The pupillary reflexes are tested with the light-reflex test, the swinging flashlight test, and the near-reflex test.

Pupillary observation and light-reflex test. The patient should be asked to fixate a distant target to minimize accommodation and miosis. In a semidark room, a flashlight is held from below the nose to illuminate the pupil. The pupil size should be measured with a ruler or near vision chart. A difference in pupil size between eyes (anisocoria), as well as the shape and location, should be noted. Further, the direct pupillary response to the light in terms of briskness should be graded separately for each eye from 0 for no response to 4+ for brisk response. In addition, the consensual response should be evaluated by observing the pupillary response of the nonilluminated eye.

Swinging flashlight test. This test determines the presence or absence of a relative afferent pupillary defect (RAPD). Similar to the light-reflex test, the handheld flashlight is used to illuminate the pupils. The constriction of the pupils is observed. The light is then moved immediately over the patient's nose to the other eye, and the pupillary response is noted. In a normal patient, the pupil will slightly constrict or stay unchanged. However, if the pupil dilates, a RAPD is present, indicating optic nerve or severe retinal damage. The light is then moved back swiftly to the other eye and the response noted. This process should be performed several times, spending equal amount of time illuminating each eye. The presence or absence of a RAPD and the location should be noted.

Near-reflex test. This test is based on the fact that looking at a near target is associated with convergence, accommodation, and miosis (near synkinesis). These three processes occur simultaneously. The patient is initially instructed to look at a distant target. A target or a finger is then held in the patient's line of vision, and the patient is asked to shift fixation to the near target. The pupillary response is observed. Normally both pupils constrict simultaneously. The test may need to be repeated several times to obtain best results. Under normal conditions, if the pupil reacts to light, it will react to accommodation, as well.

Visual acuity should be tested in all cases, as it may be affected in numerous ocular disorders. In real sense acuity of vision is a retinal function (to be more precise of the macular area) concerned with the appreciation of form sense.

2.2. Visual acuity

Testing visual acuity is a simple procedure based on fairly complex optical principles. The test demonstrates how well an eye distinguishes the size and shape of objects in the visual axis. The normal visual axis is composed of clear media (cornea, aqueous, lens, and vitreous) that focus light rays on the retinal fovea. Images that fall on the fovea and peripheral retina are then processed by the nervous system to produce the sense we know as vision.

The visual angle is defined as the angle that an object's outermost rays subtend on the retina and is measured in degrees or minutes of arc (figure 2). At a given distance, a larger object subtends a larger angle; the same object subtends a larger angle when it is closer to the eye. The details of an object are what make it identifiable. For instance, an «E» and an «H» would look the same if the details within the outermost boundaries were not resolvable by the eye. An eye can resolve the details of an object when it can distinguish spatially separated parts of that object. The minimum angle resolvable by the normal human eye is about 1 minutes (min) of arc.

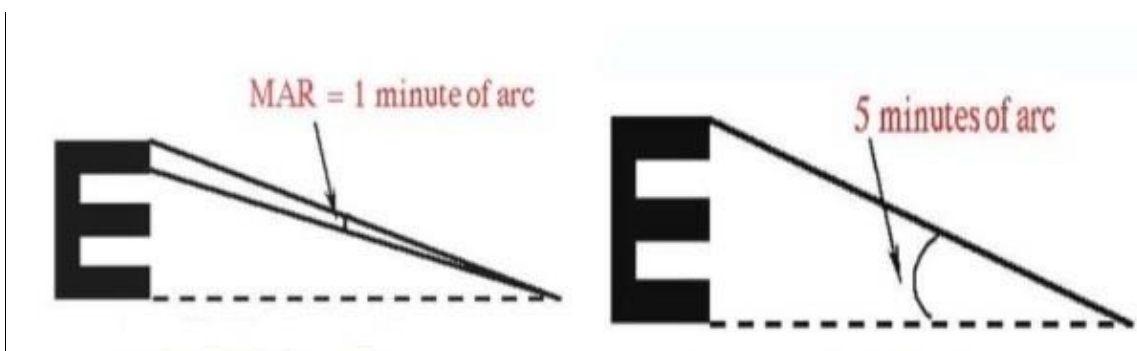
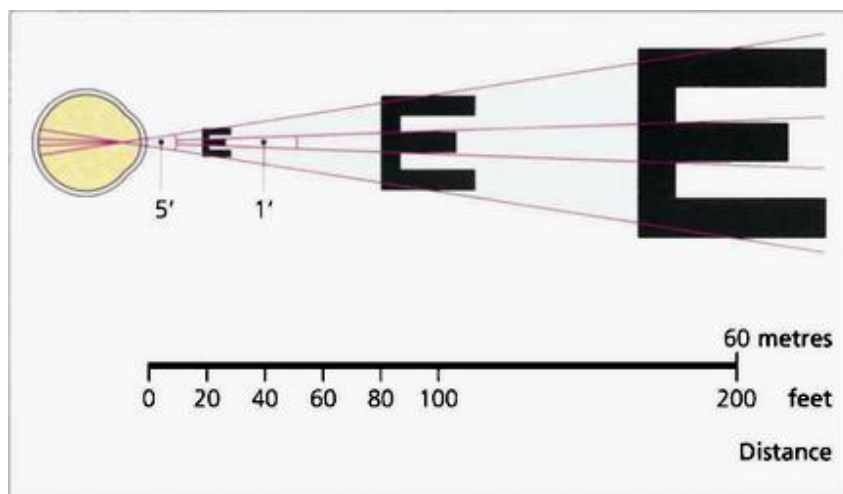


Figure 2 — Visual angle

Distant and near visual acuity should be tested separately. Visual acuity is examined one eye at a time, the other eye being occluded. By convention, the right eye is tested first. Pressure on the occluded eye should be avoided so that there will be no distortion of the image when that eye is subsequently tested. On the initial exam, the test should be made both with and without corrected lenses (if used) and recorded. On subsequent visits, glasses are worn for the test.

Distant visual acuity

The chart most commonly used for distance vision with literate patients is the Snellen chart and chart Golovina-Sivceva, which is situated 20 ft (6 m) away for Snellen chart and 5m for Golovina-Sivceva chart from the patient and diffusely illuminated without glare. At this distance, the rays of light from the object in view are almost parallel, and no effort of accommodation (focusing) is necessary for the normal eye to see the subject clearly. The charts are composed of letters of graduated sizes; the distance at which each size subtends an angle of 5 minutes of arc is indicated along the side of the chart. The farther one is from an object, the smaller the retinal image. By combining the two factors of size and distance, it is possible to determine the minimum visual angle (the smallest retinal image that can be seen by a given eye). A normal visual system can identify an entire letter subtending an angle of 5 minutes of arc and any components of the letter subtending 1 minute of arc at a distance of 20 ft. Some patients, however, may resolve letters subtending even smaller visual angles.

Procedure of testing. For testing distant visual acuity, the patient is seated at a distance of 6m from the chart, so that the rays of light are practically parallel and the patient exerts minimal accommodation. The chart should be properly illuminated (not less than 20 ft candles). The patient is asked to read the chart with each eye separately and the visual acuity is recorded as a fraction, the numerator being the distance of the patient from the letters, and the denominator being the smallest letters accurately read. When the patient is able to read up to 6 m line, the visual acuity is recorded as 6/6, which is normal.

The vision is recorded as a fraction. The number in the numerator position is the equivalent of the testing distance from the eye to the chart in feet or meters. The number in the denominator position is the distance at which a subject with normal vision can read the same figure. The vision of a normal eye is therefore recorded as 20/20, or 6/6 in metric measurement or 1.0. If the patient is able to read down only to the 20/30 line, the vision is recorded as 20/30.

If the patient cannot discern the symbols on the eye chart at a distance of 5meters (20 feet), the examiner shows the patient the chart at a distance of 1meter or 3 feet (both the ophthalmologist and the general practitioner use eye charts for this examination).

If the patient is unable to read the top line even from 1 m, he is asked to count fingers (CF) of the examiner. His vision is recorded as CF-3', CF-2',

CF-1' or CF close to face, depending upon the distance at which the patient is able to count fingers. When the patient fails to count fingers, the examiner moves his hand close to the patient's face. If he can appreciate the hand movements (HM), visual acuity is recorded as HM +ve. When the patient cannot distinguish the hand movements, the examiner notes whether the patient can perceive light (PL) or not. If yes, vision is recorded as PL +ve and if not it is recorded as PL - ve.

Table 2 — Visual acuity transcription

VISUAL ACUITY TRANSCRIPTION TABLES (Adopted by the International Council of Ophthalmology, 1954)			
Decimal V Notation	6 metre Equivalent	20 feet Equivalent	Visual Angle (minutes)
1.0	6/6	20/20	1.0
0.9	—	—	1.1
0.8	5/6	20/25	1.3
0.7	6/9	20/30	1.4
0.6	5/9	15/25	1.6
0.5	6/12	20/40	2.0
0.4	5/12	20/50	2.5
0.3	6/18	20/70	3.3
0.2	—	—	5.0
0.1	6/60	20/200	10.0

Other tests (figure 3) which are based on the same principle as Snellen's test types are as follows:

- (a) Simple picture chart: used for children
- (b) Landolt's C-chart: used for illiterate patients
- (c) E-chart: used for illiterate patients.




Figure 3 — Eye charts for testing visual acuity at a distance of 6 meters

Pinhole vision is tested if the patient is unable to read the 20/30 line. A pinhole aperture is placed in front of the eye to ascertain any improvement in acuity. The pinhole admits only central rays of light that do not require refraction by the cornea or lenses. This will allow the patient to resolve finer detail without the use of glasses. The eye not being tested is occluded, and the patient holds the pinhole occluder in front of the eye being tested. Through the pinhole, a patient's visual acuity should improve two or more lines, if a refractive error is present. However, if the pinhole fails to improve the patient's visual acuity score, the examiner must suspect another cause for the reduced vision, such as cataracts, macular or optic nerve disease. The visual acuity obtained is recorded with a preceding abbreviation of PH to note a pinhole was used.

Visual acuity for near. Near vision is tested by asking the patient to read the near vision chart (figure 4), kept at a distance of 35 cm in good illumination, with each eye separately. In near vision charts, a series of different sizes of printer type are arranged in increasing order and marked accordingly. Commonly used near vision charts are as follows:

1. Jaeger's chart. In this chart, prints are marked from 1 to 7 and accordingly patient's acuity is labelled as J1 to J7 depending upon the print he can read.
2. Roman test types. According to this chart, the near vision is recorded as N5, N8, N10, N12 and N18 (Printer's point system).
3. Snellen's near vision test types.

N.24
DISPLAY and advertisements

N.18
LARGE headlines and children's primers.
nose—one—cause—even

N.14
Book titles and paragraph headings in newspapers are often set in type like this, usually in CAPITAL LETTERS.
were—crone—our—summer

N.12
Books printed on very large pages and having many words on each line frequently use letters similar to this specimen.
name—use—means—arose

N.10
Novels, magazines, text-books and printed instructions are generally set in characters of about this size.
near—can—remove—sure

N.6
This is the smallest size type in general use. It is used for the classified advertisements in some papers, telephone directories, time tables, pocket diaries, and similar lists and books of reference.
assume—once—vane—sum

N.8
The news columns in most of the daily papers use this as the average size of print. Sometimes, the letters are larger than this, but seldom are they smaller.
crow—verse—see—renew

N.5
Printing of this size is only used for special purposes, for example, the small advertisements and financial columns in some journals, for small index lines and references, and pocket bibles and prayerbooks.
aware—caves—sea—cream

Figure 4 — Roman test type

2.3. Determination of refractive error

There are two methods of evaluating the refractive error of an eye:

1. A subjective refraction where the result depends on the patient's ability to discern changes in clarity. This process relies on the cooperation of the patient.
2. An objective refraction (usually retinoscopy) where the result depends purely on the examiner's judgement to determine the optimum optical correction objective refraction.

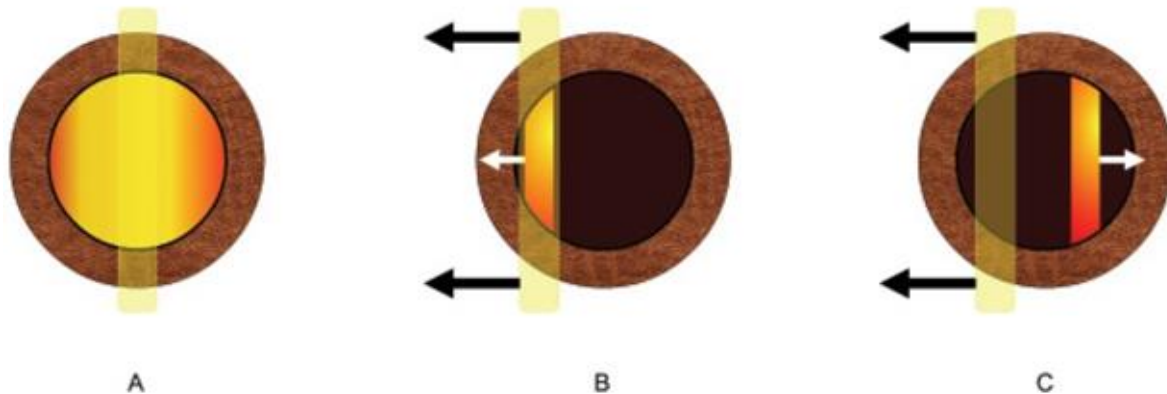
Retinoscopy

The observer, sitting at arm's length (usually a 67 cm working distance) from the patient shines a beam of light directed by a retinoscope (a mirror with a small central hole or hole in the silvering) into the patient's eye and inclines the mirror from side to side and up and down. Thus an illuminated patch of retina moves correspondingly and in turn acts as a source of light. Light from this moving area of illuminated retina will form an image at the far point of the eye and will when viewed by the observer through the hole in the mirror appear to move relative to the patient's pupil (figure 5).

The myopic eye of more than -1.5 D will produce a real inverted image between the patient and the observer, hence the image will move in the opposite direction both to the patch of illuminated retina and to the movement of the mirror by the observer. This is known as an 'against' movement.

The hypermetropic eye will produce a virtual erect image behind the patient's eye, and the image seen by the observer will move in the same direction as the illuminated retina and mirror, a 'with' movement.

The emmetropic eye forms an image at infinity, and a myopic eye of less than -1.5 D forms a real inverted image falling behind the eye of the observer. In both cases a 'with' movement is seen.



Red reflex during streak retinoscopy: A, neutralization point; B, with movement; C, against movement.

Figure 5 — Retinoscopy

Trial lenses are placed in front of the patient's eye either manually using a trial frame, or a refracting unit which mechanically changes the lenses, until the point of reversal is found. The distance refraction of the patient is calculated by correcting for the working distance (add -1.5 D for 67 cm). The refraction may not be the same in all meridians. The difference in power between the maximum and minimum meridian and their orientation gives both a measure of the degree and the axis of the astigmatism.

In children whose accommodation is active and uncontrolled and therefore variable every few seconds, it is necessary to paralyse the accommodation before retinoscopy with a cycloplegic agent. Cyclopentolate 1 % drops may be used (0.5 % in infants).

Methods of subjective refraction

Testing for distance vision. The patient views a Snellen distance type at 6 metres (20 feet). The trial frame is fitted ensuring that the frame is not tilted but horizontal and that the lens apertures are centred to the patient's eyes. Subjective refraction is an attempt to determine, by trial and error using the patient's cooperation, the combination of lenses that will provide the best corrected visual acuity (BCVA).

It is usual to start with the right eye, the left being occluded. This is called a monocular refraction. The procedure is repeated on the left eye with the right occluded. However, it is possible and often preferable to refract under binocular conditions. In both binocular and monocular refraction, it is important to control accommodation in the person with pre-presbyopia, so a 'fogging' technique is

employed whereby the spherical element is deliberately over-plussed and then reduced to find the final spherical power. Traditionally, the right eye is usually refracted first, because it is the nearest one to the practitioner in most consulting rooms. However, when the left eye has significantly worse acuity as a result of amblyopia or pathology, or if the right eye is markedly dominant, the left eye should be refracted first. The practitioner must find the maximum amount of positive power or the minimum amount of negative power that can be tolerated by the eye, without causing blurring of the retinal image.

2.4. Binocular vision

Binocular vision is one of the hallmarks of the human race that has bestowed on it the supremacy in the hierarchy of the animal kingdom. It is an asset with normal alignment of the two eyes, but becomes a liability when the alignment is lost.

Binocular vision may be defined as the state of simultaneous vision, which is achieved by the coordinated use of both eyes, so that separate and slightly dissimilar images arising in each eye are appreciated as a single image by the process of fusion. Thus binocular vision implies fusion, the blending of sight from the two eyes to form a single percept.

Binocular vision can be:

1. Normal — Binocular Single vision can be classified as normal when it is bifoveal and there is no manifest deviation.

2. Anomalous — Binocular Single vision is anomalous when the images of the fixated object are projected from the fovea of one eye and an extrafoveal area of the other eye i.e. when the visual direction of the retinal elements has changed. A small manifest strabismus is therefore always present in anomalous Binocular Single vision.

Normal Binocular Single vision requires:

1. Clear Visual Axis leading to a reasonably clear vision in both eyes
2. The ability of the retino-cortical elements to function in association with each other to promote the fusion of two slightly dissimilar images i. e. sensory fusion.

3. The precise co-ordination of the two eyes for all direction of gazes, so that corresponding retino-cortical element is placed in a position to deal with two images i.e. motor fusion.

The advantages of a Binocular vision are:

1. The first and the foremost advantage of a binocular vision is single vision.
2. In addition to single vision it results in stereopsis – the most precise kind of depth perception

3. Enlargement of the field of vision

4. Compensation for blind spot and other differences

Visual Axis (Line of direction or direction ray of Helmholtz)

It is the line which connects an object point with its image on the retina. If the visual axis of the two foveas also known as the principle visual axis inter-

sects at the fixation point, it is said that there is binocular fixation. If only one principle line of direction goes through the fixation point, then fixation is monocular. All object points that simultaneously stimulates the two fovea appears in one and the same subjective visual direction coinciding with the median plane of the head. This is known as the common subjective visual direction of the fovea. It lies in an imaginary plane passing through the root of the nose known as the third central imaginary eye or the binoculus or cyclopean eye.

Retinal elements of the two eyes that share a common subjective visual direction are called corresponding retinal points. All other retinal elements are non-corresponding or disparate with respect to a given retinal element in the fellow eye for a particular visual direction.

Law of Sensory Correspondence

It states that existence of corresponding retinal elements with their common relative subjective visual direction is the essence of binocular vision.

Retinal Correspondence can be of two types:

1. Normal Retinal Correspondence

Retinal correspondence is called normal when both the fovea have a common visual direction and the retinal elements nasal to the fovea in one eye corresponds to the retinal elements temporal to the fovea in the other eye.

2. Abnormal Retinal Correspondence

Retinal correspondence is abnormal when the fovea of one eye has a common visual direction with an extrafoveal area in the other eye. This is generally seen if the angle of squint is small and the extrafoveal point is close to the fovea. It is an attempt to regain the binocular advantage, although anomalous (because it is foveo-extrafoveal and not foveofoveal).

This results in the eyes seeing binocularly single in spite of a manifest squint. In ARC under binocular conditions the fovea and the extrafoveal point share the common subjective visual direction. But when the normal eye is closed the extrafoveal element loses any advantage over the fovea of that eye, which retains its primary visual direction.

Thus under monocular conditions the central fixation is retained by the fovea, this is the basis of the cover test.

DEVELOPMENT OF BINOCULAR VISION

During the first few years of life certain normal anatomical and physiological conditions are required for the development of binocular vision. The factors concerned in the development of binocular vision and which enable the eyes to function in a coordinated manner are:

A) Anatomical factors: The two eyes are so situated in the orbit that the visual axis is directed in the same direction. This is due to: shape of the orbit and presence of adjacent ligaments, muscles and connective tissues. The extra-ocular muscles have an important role to play as they provide motor correspondence because of the reciprocal innervation of the extra-ocular muscles.

The aim of the motor correspondence is to enlarge the field of view by transforming the field of vision into the field of fixation. Bring back the object of attention on to the fovea and to maintain it. Position the two eyes in such a way that at all the times they are properly aligned.

B) Physiological factors: The development of binocular vision (BV) depends upon certain normal physiological binocular reflexes. The reflexes can either be inborn or acquired as a result of appropriate stimulation. The various binocular reflexes

At birth the fixation reflex is poorly developed, with the child having only random, nonconjugate and aimless ocular movements. There is inability to carry out pursuit movements during the first few weeks of life. The development of optomotor reflex is essentially a post natal event, with the approximate time schedule being: 2–3 weeks –follows light unilaterally, 6 weeks to 6 months — follows light binocularly.

TM Convergence which is absent at birth starts developing at 1 month of age and is well established by 6 months. The development of accommodation lags behind the development of convergence due to the delay in the development of ciliary muscles, parallels with the convergence by 6 months of age.

TEST FOR RETINAL CORRESPONDENCE

Worth Four Dot Test (figure 6): For this test patient wears goggles with red lens in front of the right and green lens in front of the left eye and views a box with four lights — one red, two green and one white.

Interpretation:

- If the patient sees all the four lights in the absence of manifest squint, he has normal binocular single vision

- In abnormal retinal correspondence (ARC) patient sees four lights even in the presence of a manifest squint.

- If the patient sees only three green lights, he has right suppression
- When the patient sees only two red lights, it indicates left suppression
- When he sees three green lights and two red lights, alternately, it indicates presence of alternating suppression.
- If the patient sees five lights (2 red and 3 green), he has diplopia

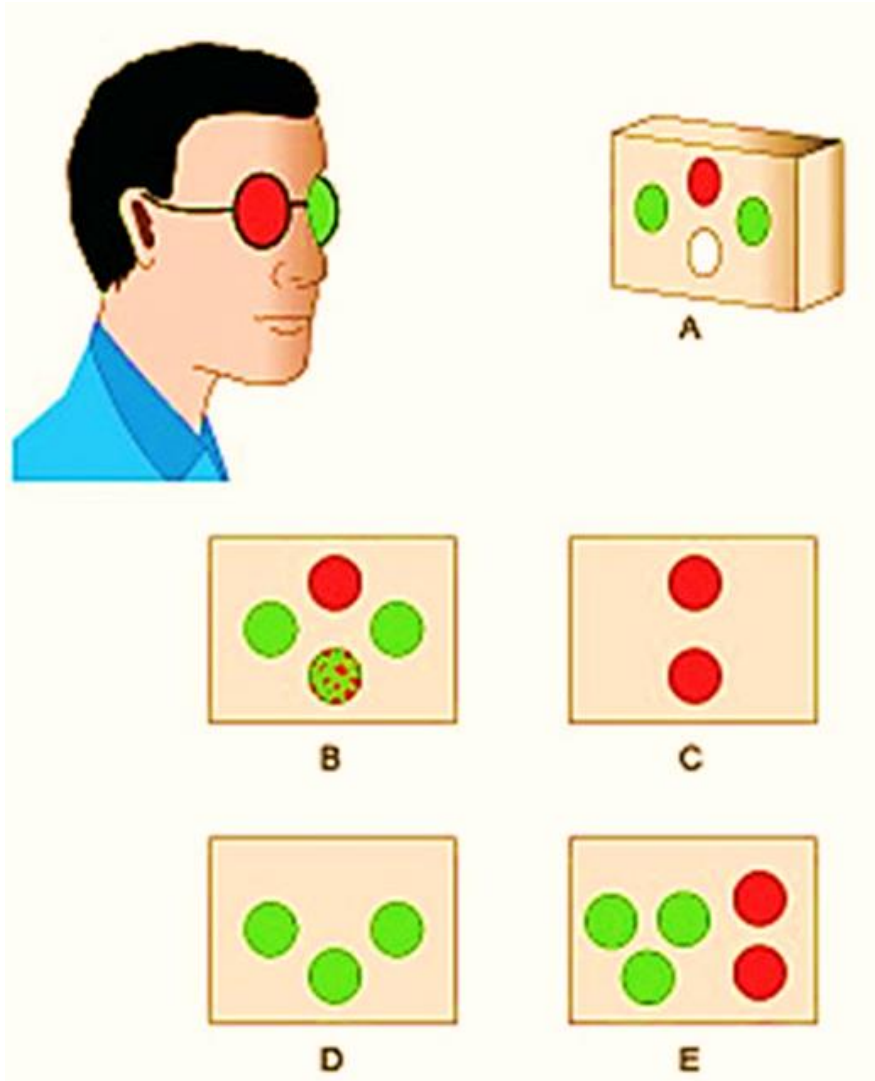


Figure 6 — Worth Four Dot Test

2.5. Color vision testing

Refracted white light forms a spectrum with increasing wavelengths from 380 nm in the violet through indigo, blue, green, yellow, orange to 700 nm in the red. Young and Helmholtz proposed the existence of three colour perceptive elements in the retina, for red, green and blue. White light is perceived when all three elements are stimulated equally and colours of various kinds when there is unequal stimulation. The trichromatic theory of colour vision is supported by histological evidence of three types of cone containing pigments with maximum absorption at 445, 535 and 570 nm. Trichromatic vision extends 20–30 degrees out from fixation and this can be assessed clinically using a coloured (red) target to confrontation.

Purpose. Impaired colour discrimination may be congenital or acquired. An acquired colour defect is an important sign of optic nerve dysfunction. Red/green discrimination is reported to be poor in early demyelinating optic neuritis whereas the blue/yellow axis is thought to be affected earliest in thyroid optic neuropathy and in chronic glaucoma. Colour vision may also be impaired in macular disease. A recent history of colours appearing 'washed out' or desaturated and/or symmetry of colour vision between eyes is highly significant and excludes congenital colour defects.

Qualitative classification as to type of defect.

Congenital 'colour blindness' is genetically determined and has a complex classification:

1) the anomalous trichromat has a weakness, not an absence, of the response to one of the colours and shows impaired discrimination between colours when compared to normals. Red or green anomaly has an X-chromosome linked inheritance and so is much more frequent in males (8 %) than females (0,4 %);

2) the dichromat lacks one of the visual pigments and is called a deuteranope if the green factor is absent and a protanope or tritanope if the red or blue response is missing;

3) the monochromat has an absence of colour appreciation. Rods or cones may both be defective. The very rare blue cone monochromats and rod monochromats have poor acuity and nystagmus.

Quantitative analysis of degree of deficiency: mild, medium, or marked.

Technique. The progressively more subtle and difficult pseudoisochromatic plates of Ishihara, Rabkin, Stilling, or Hardy-Rand-Ritter (figure 7) are made up of dots of primary colors printed on a background of similar dots in a confusion of colors or grays. These dots are set in patterns, shapes, numbers, or letters that would be recognized by a normal individual but not perceived by those with color perception defects. Patients are shown a series of plates, the number of correct answers is totaled in various color test areas, and the type and severity of any deficiency are thus defined. Lanthony tritan plates may be used specifically to detect blue-yellow color defects, but are less commonly available. For more detailed color testing, the Farnsworth Panel D-15 test or the Farnsworth-Munsell 100-hue test detect earlier, more subtle changes. The patient has to arrange colors in a specific sequence. To a normal patient, the sequence is obvious. A color-deficient patient, however, arranges color chips differently.

2.6. Visual field testing

The purpose of visual field testing is to determine both the outer limits of visual perception by the peripheral retina and the varying qualities of vision within that area. The visual field is an inverted and reversed map of the corresponding retinal location. Visual field interpretation is important for diagnosing disease, localizing it in the visual pathway between the retina and the occipital cortex in the brain, and noting its progress, stability, or remis-

sion. As a result, repeated tests of the visual field are important both diagnostically and in ascertaining the effects of therapy. Each eye is tested separately with one or more tests. With one eye fixing on a given test object, the sensitivity of various areas of the visual field may be tested with varying size and color of test objects moved throughout that field. The greatest sensitivity, of course, is at the fovea and represents the highest visual acuity of central fixation. This visual acuity decreases rapidly as the test objects are moved away from central fixation. Therefore, an object may be too small to be detected by peripheral retinal receptors but quite effective in mapping out central visual field within 10 to 15 degrees of foveal fixation.

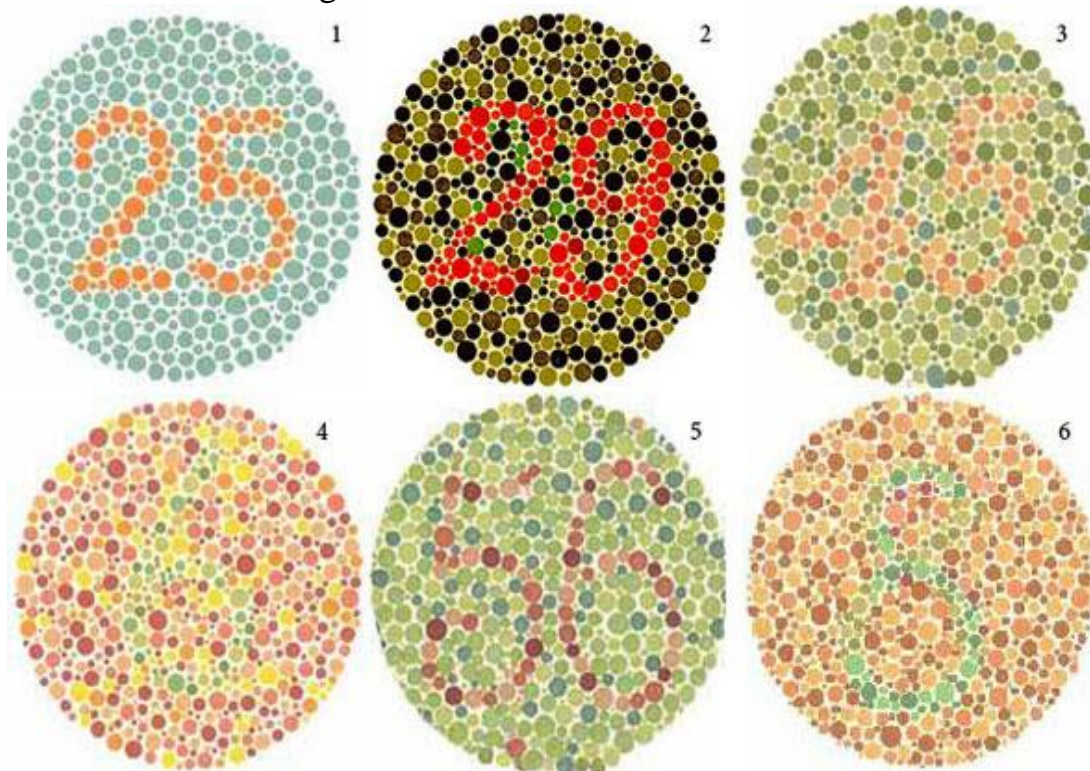


Figure 7 — pseudoisochromatic plates

The monocular confrontation field test. No special instruments are required for this screening test, which provides a rough estimate of the patient's visual field by comparing it with the examiner's visual field. It is assumed that the examiner's visual field is normal. This technique is highly recommended for use in the emergency room and is the technique of choice in the bedridden and in children.

Technique. The patient and examiner face each other at a distance of 1 m. With the left eye covered, the patient is instructed to look with the right eye at the left eye of the examiner, whose own right eye is covered. A small object, such as a pencil or pin, or a larger one, such as a wiggling finger, may be used as a target. The examiner places his or her hand midway between the patient and him- or herself and initially beyond the limits of field of vision of either in a given meridian (e. g., far temporal to both patient and examiner). As the test object is moved slow-

ly toward the line of vision between patient and examiner, the patient is asked to respond as soon as he or she is able to see the target. The physician compares this to the time when he or she is able to perceive the target. This is repeated at 8 to 10 equally spaced meridians at approximately 360 degrees. The visual field is considered normal if the patient sees the target 90 degrees temporally, 50 degrees nasally, 50 degrees upward, and 65 degrees downward. The test is then repeated on the other eye. With careful testing, the blind spot and focal scotomas can be detected. To evaluate the central 20 degrees, a red pin (5 mm or 10 mm) can be used. If in one spot the red appears pale or hazy, a relative scotoma is present. The central scotoma in optic neuritis is rapidly detected this way.

Perimetry is done to obtain accurate examination of the peripheral extent of the visual field. Perimetry may be done as manual kinetic (moving target from nonseeing to seeing areas of vision) using a Forsters or Goldmann-type bowl perimeter or static (nonmoving target flashed at different locations in visual field) by automated Humphrey visual field analyzer or the Octopus.

Forsters perimeter (figure 8) has a metallic semicircular arc, graded in degrees, with a white dot for fixation in the centre. The arc can be rotated in different meridians. The patient is seated facing the arc with his chin firmly in the chin-rest and usually 33cm from it. With one eye occluded, he fixates the white dot in the centre. A test object (usually white and of size 3 to 5 mm) is moved along the arc from extreme periphery towards the centre, and the point at which the patient first sees the object is registered on a chart. The arc is moved through 30° each time and 12 such readings are taken. The details of the object regarding its colour and size are noted. With the help of this perimeter extent of peripheral field is charted.

The extent of normal visual field with a 3 mm white colour object is superiorly 50°, inferiorly 70°, nasally 60° and temporally 90°. The field for blue and yellow is roughly 10° less and that for red and green colour is about 20° less than that for white (figure 8).

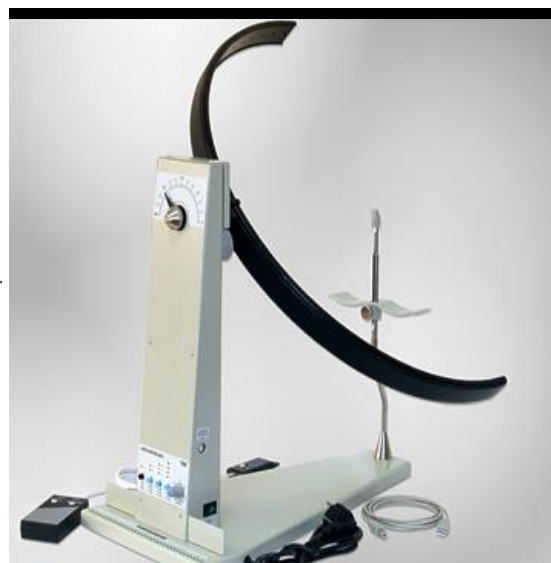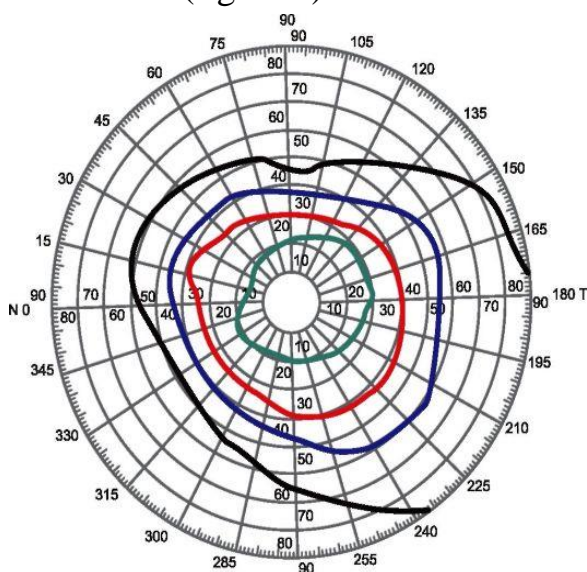


Figure 8 — Normal visual field

Static perimetry

The light stimulus is flashed on and off within suspicious areas of the patient consistently identifies the stimulus. This light intensity constitutes a crude threshold for that field location. This concept was developed in early static perimeters e. g. the Friedmann Visual Field Analyser Mkl which used a semi-automated process with multiple stimuli to measure luminance thresholds at different retinal locations.

Modern (automated) static perimeters e. g. Octopus, Zeiss-Humphrey perform a similar estimation of the differential light sensitivity at many field locations which are arranged in a regular grid pattern covering the field. Computerisation of the thresholding process ensures that the stimuli are presented at each location in a random order so there is less incentive for the patient to lose fixation (figure 9).

The test typically takes longer than a Goldmann field test because it is a more detailed measurement of the visual status. Automated perimetry also requires less highly trained operators. Such detailed examinations may not be appropriate for all patients but are important in the follow-up of glaucoma patients because small changes in the size or depth of a scotoma may indicate the need for more aggressive treatment of raised intraocular pressure.

2.7. Visual field loss

Lesions at the level of the retina. These affect one eye only.

Retinal detachment and occlusion of blood vessels at a level smaller than the central retinal artery or vein, give defects with boundaries in the horizontal meridian.

Retinal detachment tends to be fairly rapid in onset. It may follow trauma or there may be predisposing factors. It may be preceded by floaters and flashes before what the patient describes as "a curtain" coming across the visual field. A crescentic red or orange slip of detachment may be apparent at the periphery of the retina.

Central retinal artery occlusion tends to be a sudden and complete loss of vision in one eye but, if occlusion is at the level of one of the four arteries to the retina, there will be loss of just a quadrant of field. The affected area will look pale and poorly supplied with blood vessels. One of the four arteries will not be seen. Central retinal vein occlusion presents in a fairly similar way to arterial occlusion but the retina looks very different. Haemorrhages are scattered throughout the fundus in a typical blood-storm pattern with cotton-wool spots. With less complete blockage, sparse scattered haemorrhages occur.

Age-related macular degeneration which affects the macular area and the periphery is spared until very late.

Drugs can cause disturbance of vision (tend to be bilateral); chloroquine can cause a classic bull's-eye maculopathy affecting the center of the field.

Lesions before the chiasm

These will produce a field deficit in the ipsilateral eye. Field defects (figure 9) from damage to the optic nerve tend to be central, asymmetrical and unilat-

Lesions at the chiasm

These classically produce a bitemporal hemianopia.

If they spread up from below (for example, pituitary tumours), the defect is worse in the upper field.

If the tumour spreads down from above (for example, craniopharyngioma), the lesion is worse in the lower quadrants.

Lesions of the optic chiasm may show a phenomenon where two identical coloured objects are shown to one eye in the two vertical halves of the visual field, but one appears to be brighter and sharper than the other. For example, with a right hemianopia the left hemifield is brighter than the right.

Lesions after the chiasm

These produce homonymous field defects; a lesion in the right optic tract produces a left visual field defect. Fibres in the optic tracts gradually rotate until the fibres reach the geniculate body, so lesions in the tract before the geniculate body may produce incongruous defects.

Lesions in the main optic radiation or optic peduncle cause complete (left or right) homonymous hemianopia without macular sparing. This is seen in stroke and middle cerebral artery lesions.

Lesions in the temporal radiation cause congruous upper quadrantic homonymous hemianopia commonly with macular sparing -eg, tumours.

Lesions in the parietal radiation (rare) cause inferior quadrantic homonymous hemianopia without macular sparing.

Lesions in the anterior visual cortex (common) produce a contralateral homonymous hemianopia with macular sparing, posterior cerebral artery occlusion.

Lesions in the macular cortex produce congruous homonymous macular defect, blunt injury to the occiput.

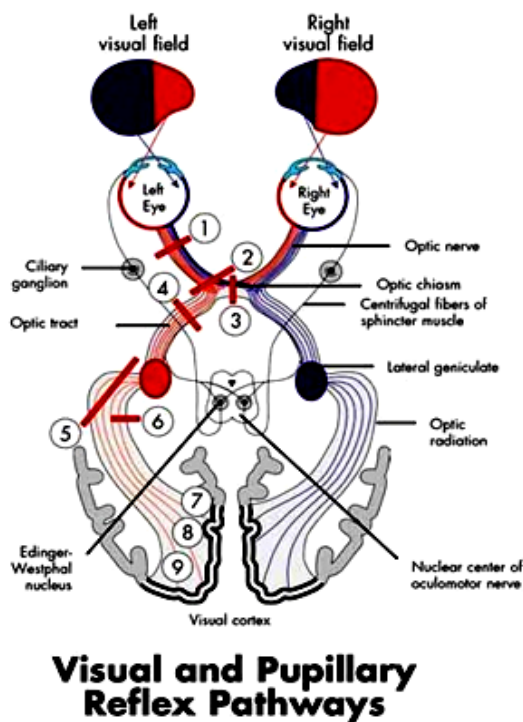
Lesions of the intermediate visual cortex produce an homonymous arc scotoma, with sparing of both macula and periphery. This is seen in a distal posterior cerebral artery occlusion.

Occipital lobe lesions

If both occipital lobes are injured then the patient is in a state of cortical blindness. The patient is unable to process visual information and behaves in a similar fashion to someone who suffers a peripheral blindness. However, some patients deny their blindness and attempt to behave as if they have vision. This state of denial of cortical blindness is called Anton's syndrome.

Lesion of the primary visual perception area of the right or left occipital lobe will produce a clear loss of visual perception from the contralateral visual field. Patients are usually aware of the deficit and do not neglect that side of the visual field.

Ventral stream damage; this area is involved with recognition, and damage here does not tend to produce visual field defects.



Site of lesion		Visual field defect
1	Left optic nerve	Left amaurosis
2	Optic nerve near left chiasma	Left amaurosis, right temporal hemianopia
3	Medial chiasma	Bitemporal hemianopia
4	Left optic tract	Right homonymous hemianopia (strongly incongruent defects indicate a tractal lesion)
5	Proximal portion of left optic radiation	Right superior incongruent quadrantanopia
6	Inferior portion of left optic radiation	Right inferior incongruent quadrantanopia
7	Anterior portion of left calcarine fissure	Right temporal crescent defect
8	Middle portion of left calcarine fissure	Right congruent hemianopia with retention of temporal monocular crescent
9	Distal left calcarine fissure	Right congruent hemianopic central scotoma

Figure 10 — visual pathway and their defects

3. ANTERIOR SEGMENT EXAMINATION

3.1. Slitlamp biomicroscopy of anterior segment and fundus

Biomicroscopy involves examination of the external ocular structures and the front of the eye to a depth of the anterior vitreous using a specially designed microscope and light source that allow for a binocular, stereoscopic view and permit the examiner to perform applanation tonometry. Slitlamps (figure 11) are most commonly stand-mounted, but for bedside exam, handheld lamps are available. Patient and examiner are seated on either side of the slitlamp, the patient placing his or her chin on a chin rest and the forehead against a frame while the examiner views the eye through the microscope. By moving the microscope in and out with a hand control, the examiner can adjust the depth of focus so that the object of interest is brought clearly into view. The general order of examination is to start with the lids and then progress to the conjunctiva, cornea, anterior chamber, iris and pupil, lens, and anterior vitreous. The fundi are seen by use of double aspheric 60, 78, 90 D lenses, or digital wide field lens that combines a high magnification with a wide field of view. The examiner holds these lenses in front of the patient's eye and shines the slit beam straight through the (usually) dilated pupil to focus on the retina, thus obtaining a stereoscopic but inverted view. This is useful for evaluating macular edema, optic nerve lesions, or other posterior pole lesions. It is less useful for the peripheral retina beyond the equator. Other techniques for views of the deeper vitreous, retina, and optic nerve are described below.

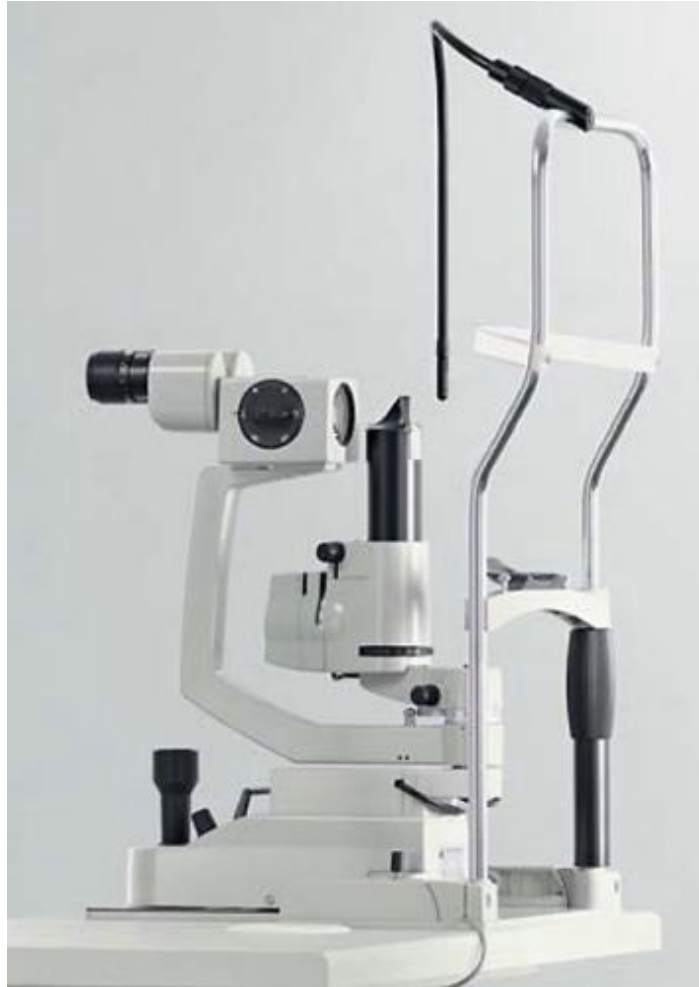

Figure 11 — the slitlamp

3.2. Types of illumination

The light source and viewing angle can be adjusted relative to each other to allow a view of different parts of the anterior segment that would not otherwise be visible.

1. Direct illumination:
 - Direct diffused illumination.
 - Direct focal illumination.
 - Paralleliped illumination.
2. Indirect illumination:
 - Indirect proximal illumination.
 - Scleral scatter.
3. Retro-illumination.
4. Oscillatory illumination.

Direct diffuse illumination (figure 12-1) permits a direct view of a broad section of the external structures, cornea, and iris. The beam is at full width, and the light source is moved to about 45 degrees from the microscope. The light intensity should be just bright enough to do the examination but not so bright as to cause the patient discomfort.

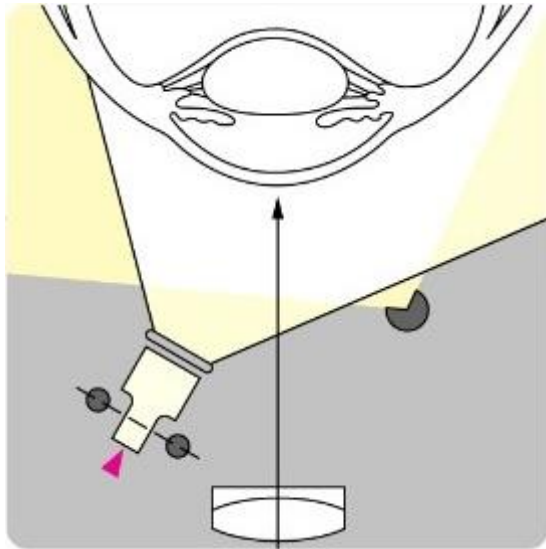


Figure 12-1 — Direct diffuse illumination

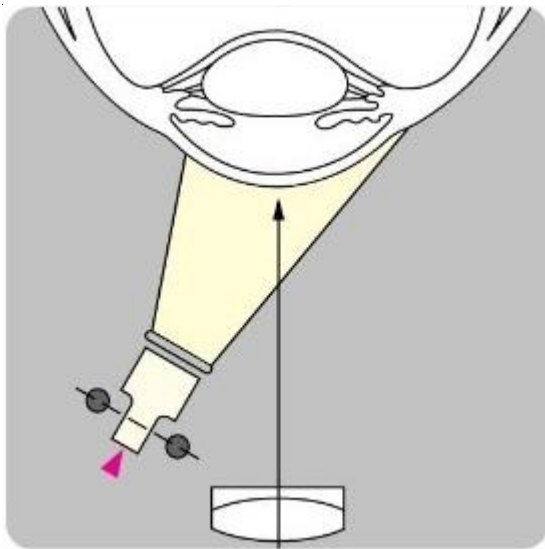


Figure 12-2 — Direct focal illumination

Direct focal illumination (figure 12-2) uses a very narrow beam directed from 45 degrees. This angle and slit lamp position sends the beam past the pupil margin and through the lens so that there is no reflection from an internal surface. This technique allows a view of the corneal surface and anterior layers.

Parallelipiped illumination (figure 13-1) uses a slightly broader beam than the direct focal and is used to view a cross section of the cornea and endothelium. When the slit lamp is moved peripherally and the focus is shifted posteriorly, the iris is clearly visible. In this case, the slit beam is directed at the iris, not past it, in what is called tangential illumination.

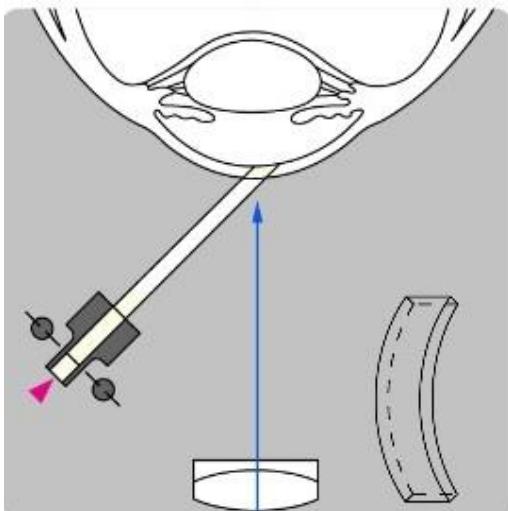


Figure 13-1 — Paralleliped illumination

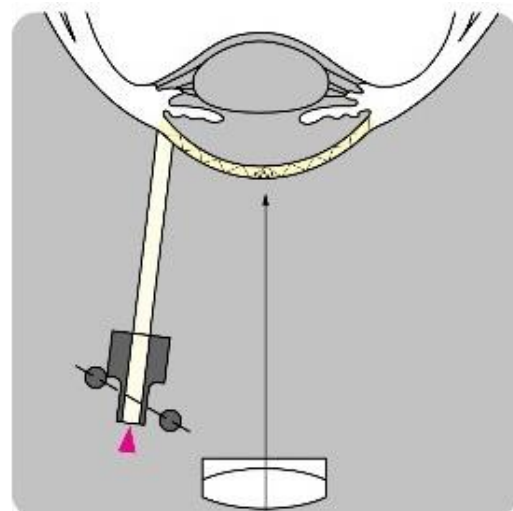


Figure 13-2 — Scleral scatter illumination

Scleral scatter illumination (figure 13-2) is used to visualize abnormalities of the cornea that are not visible with direct illumination. A narrow beam is directed at the temporal limbus and reflected internally to detail changes that are usually transparent.

Retroillumination. Examination of normal or pathological structures in light reflected from tissue situated more posteriorly. Finally, the light may be

moved to a position directly in front of the microscope so the beam is aimed through the pupil and lens to the retina. The light reflected back to the viewer from the retina and is used to visualize certain structures or abnormalities of the lens, iris, or cornea. Direct retroillumination observer in direct pathway of light (figure 14). Light is reflected from structures, so pathology seen against illuminated background. Indirect retroillumination observer is right angle observed structures not in line so pathology seen against dark non-illuminated background.

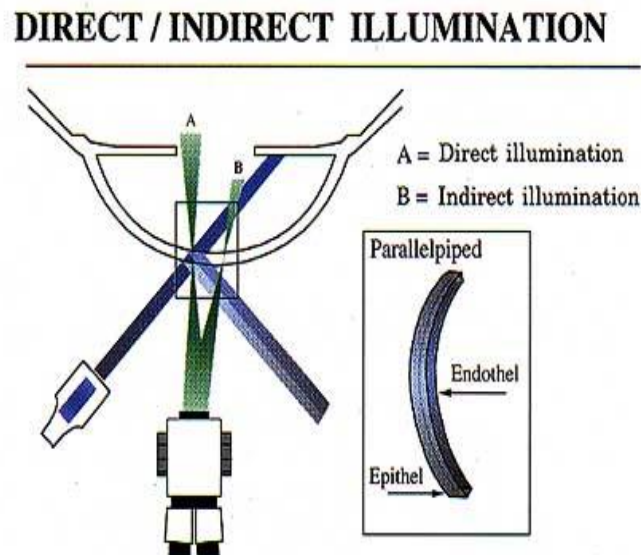


Figure 14 — Direct/indirect illumination

Oscillatory illumination of Koppe. Slit beam is given an oscillatory movement by which is it often possible to see minute objects and filaments especially in the aqueous.

Eyelids and palpebral tissues. Under good lighting conditions the lashes and eyebrows should be inspected for the presence of inflammation, scaling, or dandruff, and the lashes for orientation, that is, being turned in or out, misdirected (trichiasis), whitening (poliosis), missing (madarosis), or present as more than one row. Focal changes in pigmentation or vesicular changes are also important to note. The observer should inspect the general appearance of the lid margins as to color, texture, swelling, position, and motility. Note should be made of signs of inflammation, pouting of the meibomian gland openings, rash, unusual vascularity, or old scars. The normal lid margins should overlie the corneal limbus by 1 mm to 2 mm above and below with no exposure of sclera. Voluntary lid closure should be complete with no inferior exposure. Involuntary blinking should occur every 3 to 6 seconds with complete closure of the lids. Both upper lids should elevate well on upward gaze and drop on downward gaze. The space between the upper and lower lid margin ranges normally between 8 and 12 mm. This measurement is not as critical as is a disparity in the size of this measurement between the two eyes in a given patient. The lid margins should follow the globe synchronously on downward and upward gaze without evidence of lid lag. The

borders should have good anatomic apposition to the globe with the tear puncta (upper and lower punctal openings are located 2 to 4 mm temporal to the medial canthus in contact with the tear film that they drain).

Lid eversion. The upper lid may easily be everted for inspection of the palpebral conjunctiva by having the patient look down while the examiner grasps the lashes with the thumb and index finger of one hand, pulling out and down, pressing on the lid with a cotton-tipped applicator stick 1 cm above the edge of the lid margin, i. e., at the superior border of the tarsal plate, and flipping the lid over the stick (figure 15). In the presence of pain, a topical anesthetic may assist in this part of the examination. To restore the everted upper lid, the examiner simply asks the patient to look up and simultaneously pulls the lashes down gently.

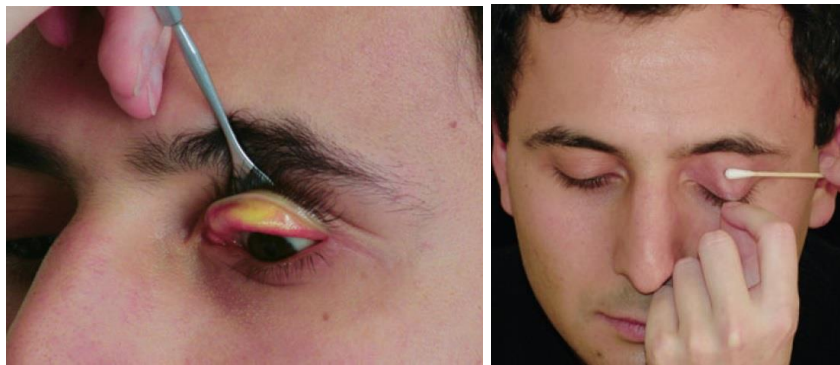

Figure 15 — Upper lid eversion

The lower palpebral conjunctiva (figure 16) is easily seen by pressing down over the bony maxilla to pull the lid down with a finger and asking the patient to look up.

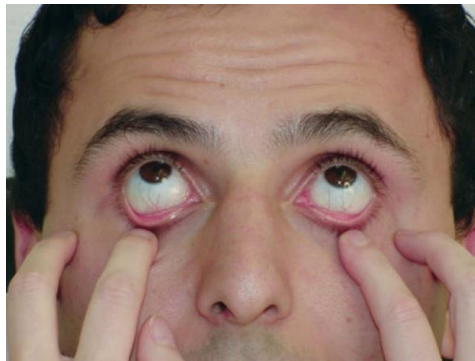

Figure 16 — Lower lid eversion

The main lacrimal gland is situated at the superotemporal quadrant of the orbit. It may be seen as a globulated pink mass under the upper eyelid when the patient is asked to look down and nasally, and traction is placed on the upper outer eyelid. Tears are carried from this gland as well as from the accessory lacrimal glands in the conjunctiva from the superotemporal quadrant of the eye down toward the inferonasal area, where tears pass through the lacrimal canaliculi via the puncta and down into the lacrimal sac. From there they enter the nasolacrimal duct opening under the inferior turbinate of the nose. Tears flow

down the back of the throat, occasionally giving patients the taste of medication instilled into the conjunctival cul-de-sac.

The palpebral conjunctiva is seen by lid eversion and varies in appearance with age. Above and below the tarsal plate it has many shallow folds; frequently, small bumps that represent follicles or lymphoid tissue formation are present. Follicles are normally absent in infants, prominent in children, and less notable in adults. Over the tarsal plate, the conjunctiva is firmly bound to the fibrous plate and normally shows no follicles. Papillae, small dome-shaped nodules with a central vascular core, can be seen in any acute or chronic inflammation of the conjunctiva. Foreign bodies, membranes, pseudomembranes, or granulomas can also be seen. The examiner may see faint yellow lines of the meibomian glands running vertically in the tarsal plate through the translucent overlying tissue. Conjunctival lacerations or abrasions are easily detected with a drop of sterile fluorescein solution or the application of a sterile fluorescein paper strip to the tear film. A white light will show the injured area as yellow-green. A cobalt blue light will show the area as bright green.

The bulbar (eyeball) conjunctiva is examined by gently separating the lids and asking the patient to look in all directions of gaze up, down, right, and left. The normal conjunctiva is a thin membrane that is almost entirely transparent and appears white, although a few patients may normally have hyperemic (red) eyes due to dilation of the many fine conjunctival vessels running throughout the membrane. In general, the examiner should be able to observe the white sclera through the transparent bulbar conjunctiva without difficulty, although occasionally deposits of pigment may be seen. On either side of the limbus, a slightly raised yellow area (pinguecula) may normally be seen and, with age, may slightly yellow due to benign degeneration of elastic tissue. Benign pigmented nevi may be present; these are flat and often translucent under magnification.

Deep to the conjunctiva are the episcleral vessels, which run in a radial direction from the cornea. Inflammation in these vessels is indicative of deeper disease than inflammation involving just the conjunctival tissues. Although superficial conjunctival vessels can be moved with a cotton swab, the deep episcleral vessels do not move with manipulation.

The normal corneal surface is so smooth that it is analogous to a convex reflecting surface. Any minor disruption in this surface will be readily apparent, particularly under magnification, as a break in a normally perfect light reflex. The size of each cornea should be noted and normally measures 12 mm horizontally and 11 mm vertically in an adult. A flashlight and loupe are extremely useful for examination in the absence of a slitlamp. Scars, old and active vessels, and deposits in the stroma and on the back of the cornea are difficult to see with the unaided eye. Small foreign bodies may be missed without illumination and magnification. The application of a sterile fluorescein, rose bengal, or lissamine green dye strip (wet with sterile saline) to the tear film is extremely important in detecting the

presence of abrasions or foreign bodies on the corneal surface. Under white light, an abrasion will stain yellow-green and under cobalt blue light, bright green with fluorescein. Rose bengal stain will stain and outline the defect in red and is easily seen with a white light. Lissamine green will stain and outline the defect in green under white light. The defect is easier to see with the use of a red filter, which outlines the defect in black. A drop of local anesthetic will greatly aid the examination of a patient suffering lid spasm secondary to a corneal lesion.

Anterior chamber. Detailed examination of the anterior chamber is difficult without the use of a slitlamp biomicroscope, but a good light and the use of the naked eye or a magnifying loupe will allow the examiner to detect chamber depth, clearness, or cloudiness of the aqueous fluid and the presence of blood, either diffuse or settled out in hyphema layering. Hypopyon (the accumulation of pus in the anterior chamber) may also be detected in the inferior anterior chamber.

Depth of anterior chamber. Normal depth of anterior chamber is about 2,5 mm in the centre (slightly shallow in childhood and in old age). On slit-lamp biomicroscopy, an estimate of depth is made from the position of iris. Anterior chamber may be normal, shallow, deep or irregular in depth. Anterior chamber contains transparent watery fluid — the aqueous humour.

Iris. The color of each iris should be noted and differences in color, texture, and pattern recorded. Colour of the iris varies in different races; it is light blue or green in caucasians and dark brown in orientals. Pattern of normal iris is peculiar due to presence of collarette, crypts and radial striations on its anterior surface. Under magnification, the examiner may detect the presence of nevi, abnormal areas of very dark pigmentation, new vessels, atrophy, tears, or surgical openings.

The pupils should be inspected for size, shape, and location. Normal pupils are equal in size, although in blue-eyed patients there may be a 0,5 mm difference under normal conditions. The range of normal pupils is 3 mm to 5 mm in room light. Pupils smaller than 3 mm in diameter are miotic; pupils larger than 7 mm are mydriatic. Pupils may be miotic if the patient is taking certain drugs for glaucoma or is taking heroin. They may be abnormally large in cases of ocular contusion, systemic poisoning, and neurologic disease of the midbrain. The pupil is normally round in shape.

The lens may be observed under magnification for opacity using biomicroscopy, a loupe or the plus lenses of an ophthalmoscope. This procedure is more easily done with the pupil dilated so that as much of the lens as possible can be seen. A normal lens is positioned in the patellar fossa (space between vitreous and back of iris) by the zonules. Normal lens is a biconvex structure, which is nicely demonstrated in an optical section of the lens on slit-lamp examination. The optical section of the lens shows from within outward embryonic, foetal, infantile and adult nuclei, cortex and capsule. On focal illumination the normal lens in young age appears almost clear or gives a faint blue hue. Normal lens is a transparent structure. Any opacity in the lens is called cataract, which looks greyish or yellowish white on focal illumination.

3.3. Direct ophthalmoscopy

Examination of the posterior segment of the eye (vitreous, optic nerve head or disc, vessels, retina, choroid) is performed with the aid of an ophthalmoscope. A satisfactory examination of the posterior pole can usually be made through an undilated pupil, provided that the media (aqueous, lens, vitreous) are clear. However, a greater extent of the peripheral posterior segment can be examined through a dilated pupil. Ophthalmoscopy (figure 17) is best done in a darkened room. For optimum dilated fundus examination, mydriatic agents in common use are cyclopentolate 0,5 % or tropicamide 1 %, phenylephrine 2,5 %; the latter should be used with caution in any patient with a history of significant cardiovascular disease. No mydriatic agent should be instilled in an eye in which a shallow anterior chamber is suspected. An estimate of the anterior chamber depth can be made by illuminating it from the side with a penlight. If the iris seems abnormally close to the cornea or patient has high IOP, dilation is contraindicated because of the risk of inducing acute angle-closure glaucoma.

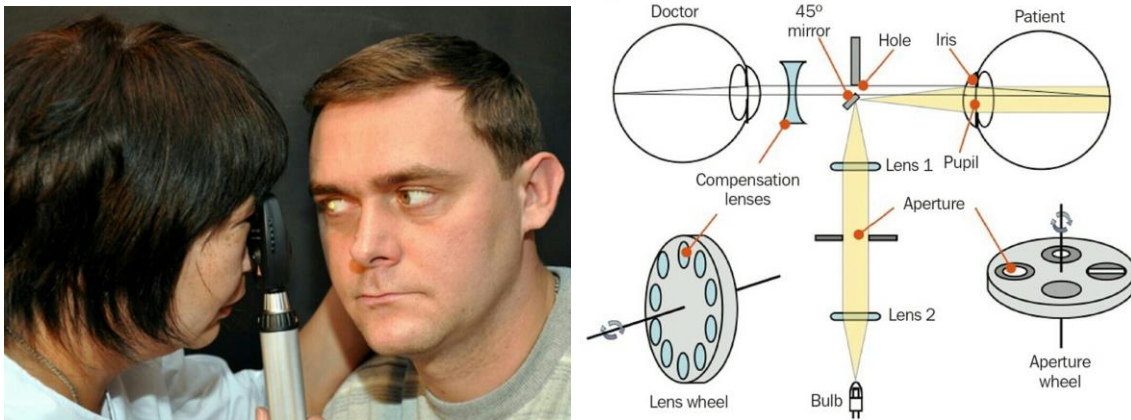


Figure 17 — Direct ophthalmoscopy

Ophthalmoscopes. There are many forms of ophthalmoscopes, the most commonly used being handheld direct ophthalmoscopes designed to provide a direct magnified view. The source of illumination is projected by means of a mirror or prism coinciding with the observer's line of vision through the aperture.

Direct ophthalmoscopy. No one had observed the ocular fundus until 1847, when the mathematician Charles Babbage, and later Helmholtz in 1851, independently recognised that rays of light entering the eye and illuminating the retina retraced almost the same path on leaving the eye. They realised that this accounts for the blackness of the pupil, because little light from the retina reaches the observer's eye unless he places his eye in line with the source. Babbage solved this problem by directing light into the patient's eye by an inclined mirror which had an aperture in its silvering through which some rays emerging from the patient's eye could pass to the observer's eye. Lenses may be necessary to focus the fundus view and the strength of these will depend on the sum of both the patient's and the observer's spectacle correction.

The ophthalmoscope is held close to the observer's eye and approximately 15 cm from the patient's eye, in the observer's right hand to examine the patient's right eye and in the observer's left hand to examine the patient's left eye. The observer uses his or her right eye for the patient's right eye and his or her left eye for the patient's left eye. The patient should have no glasses on, have chin straight, and be fixating on a distant target with the eye as steady as possible. The physician may have to adjust the ophthalmoscope power setting to accommodate for the patient's or his or her own refractive errors red-numbered minus lenses are used for nearsighted errors, black-numbered plus lenses are used for farsighted errors. Eyes that have undergone cataract removal but no lens implantation (aphakia) should be examined with a +8 to +12 lens to obtain a view of the fundus. If both patient and examiner have normal eyes and the lens is set at 0, a red reflex will be seen, which is considered normal. Moving the ophthalmoscope as close to the patient's eye as possible, the observer uses black or positive lenses.

Vitreous opacities, such as hemorrhages and floaters, should be localized and noted, and changes in the posterior segment structures focused and studied.

The optic nerve head should be brought into focus and examined. This structure is generally circular to oval with vertical orientation and pink in color. The temporal side is usually lighter pink than the nasal side. The center of the disk may have some depression, which is referred to as the cup, the bottom of which may be fibrous in appearance and represents the fibers of the lamina cribrosa of the sclera. Normal physiologic cupping is round and may vary from absence to 80% involvement of the nerve head. The size of the normal nerve head may vary with the refractive error of the patient, being small in farsighted patients and large in myopic patients. The border of the nerve head is usually discretely demarcated from the retina but may merge gradually into the surrounding tissue without any clear-cut edge. A white border representing a scleral ring or crescent is often present and formed by exposure of sclera between the choroidal vasculature and the opening for the optic nerve. There may be excessive choroidal pigment in this area.

Retinal arteries and veins (AV). The arteries are red and smaller than the veins in about a 4:5 ratio (Figure 18). Because of a thicker wall, the arteries have a shiny central reflex stripe. The column of blood traversing these vessels may be seen through the transparent walls. Branching is variable. The examiner should evaluate the transparency of the vessels, the presence of pressure effects such as AV compression (nicking) where vessels cross each other, and presence of focal narrowing of arterioles, as well as increased tortuosity and widening of venules, hemorrhages, and exudates around the vessels. Round hemorrhages may occur in patients with diabetes mellitus and are generally located deep intraretinal. Flame-shaped hemorrhages are usually superficial in the retina, located in the nerve fiber layer, and commonly found in patients with high blood pressure and blood dyscrasias.

The macular area located about 2 dd temporal to the optic nerve head is darker than the surrounding retina and, in a young person, will have a lustrous central yellow point called the fovea centralis. This appears as a small area of dark red with a tiny yellow light reflex at the center of the fovea. The foveal reflex dulls with age or certain drug-induced retinal toxicities.

This method of examination was devised four years later than direct ophthalmoscopy, by Ruete (1851), who reflected light from a bright source into the patient's eye using a mirror with a central hole, but who interposed a convex lens between them.

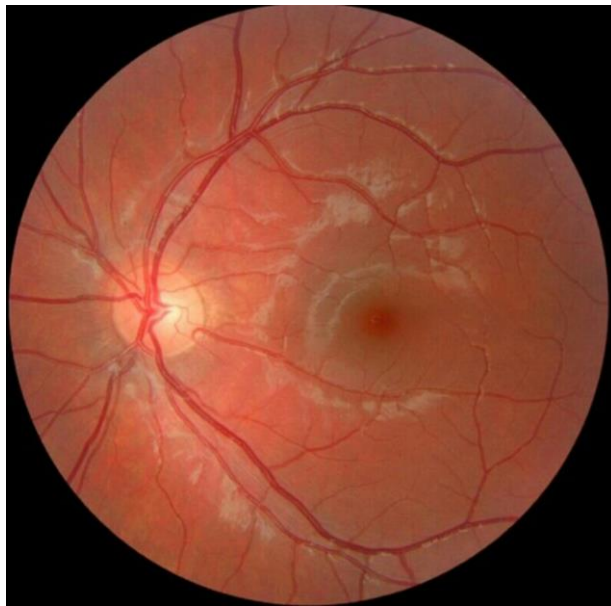


Figure 18 — normal ophthalmoscopy picture

3.4. Indirect ophthalmoscopy

Is a technique generally used by specialists and involves the use of a head-mounted, prism-directed light source coupled with use of double aspheric (+14, +20, or +28) diopter condensing lenses to see the retinal image. Several designs of indirect ophthalmoscopes are available, but all produce a stereoscopic image that is inverted, real, and capable of being seen on a semitransparent film held at the focal plane of the lens (figure 19). Although most indirect ophthalmoscopes are designed for use through dilated pupils, some may be used through a miotic or undilated pupil; this is a great advantage in patients who cannot be dilated either because they do not respond to topical drugs, are at risk of angle-closure glaucoma, or have pupil scarred to the lens.

The image covers approximately ten times the area usually seen in the field of the direct ophthalmoscope but is smaller than a direct ophthalmoscope, although the larger field of view gives great perspective to the entire fundus and is helpful in locating multiple lesions or in evaluating retinal detachment. Another advantage is stronger illumination, which allows light to pass through opacities of the vitreous obstructive to a direct ophthalmoscope.

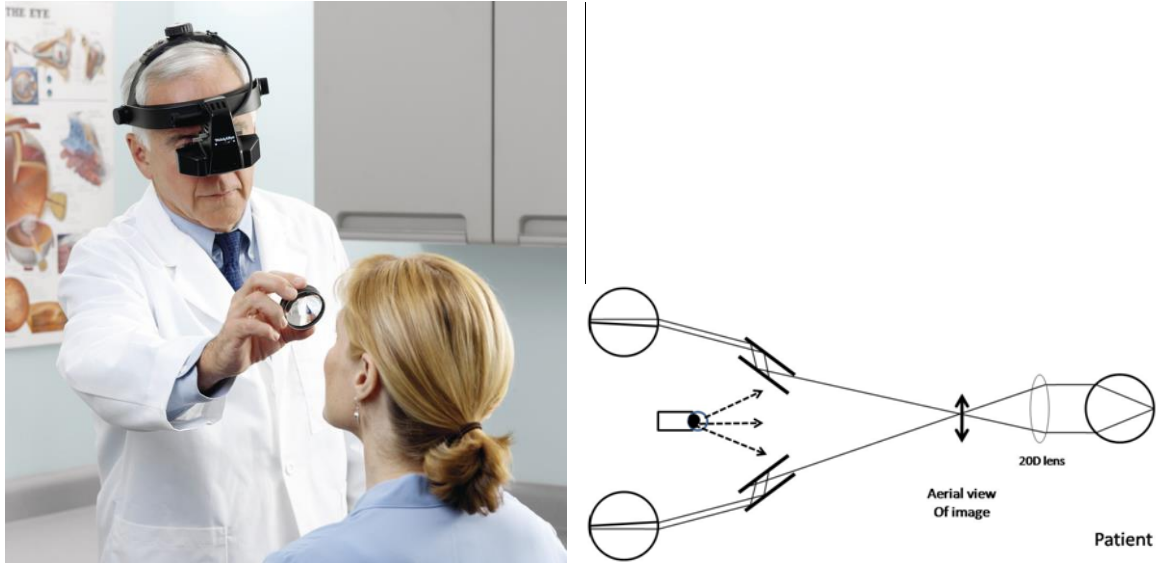


Figure 19 — indirect binocular ophthalmoscopy

4. INTRAOCULAR PRESSURE (IOP) MEASUREMENTS FOR GLAUCOMA OR HYPOTONY

Intraocular pressure (IOP) is the fluid pressure inside the eye. Intraocular pressure is mainly determined by the coupling of the production of aqueous humor and the drainage of aqueous humor mainly through the trabecular meshwork located in the anterior chamber angle.

An important quantitative relationship is provided below:

$$IOP = F / C + PV.$$

Where F = aqueous fluid formation rate, C = outflow rate, PV = episcleral venous pressure. The above factors are those that drive IOP.

It is usually found in health to be between 10 and 20 mm Hg., the eye thereby having sufficient rigidity to function as an optical instrument. The mean intraocular pressure in a white population aged over 40 years is 15,5 mm Hg. With a standard deviation of 2,5 and it is usually accepted that the upper limit of 'normal' intraocular pressure is 21 mm Hg., but this is a statistical concept. It is important to realise (as it has not been in the past) that for the individual a pressure moderately in excess of 21 mm Hg. Will not necessarily cause injury to the eye, nor will eyes with pressures of 21 mm Hg. And below necessarily be free of the chronic type of optic nerve and other damage usually associated with moderately higher levels of intraocular pressure viz. glaucoma.

Finger tension. A rough estimate of IOP may be made by palpation of the eyeball through closed lids (figure 20). The patient is asked to look down (but not close the eyes), and the examiner places two forefingers on the upper lid over the globe, exerting pressure alternately with each forefinger while the other rests on the globe. Pressure just sufficient to slightly indent the globe should be applied. In the absence of inflammation, this is a painless procedure, but it should be avoided if

rupture of the globe is suspected. After experience with palpating a number of normal eyeballs, the examiner will learn what normal resistance is and by comparison may determine whether an eyeball is either too hard or too soft.

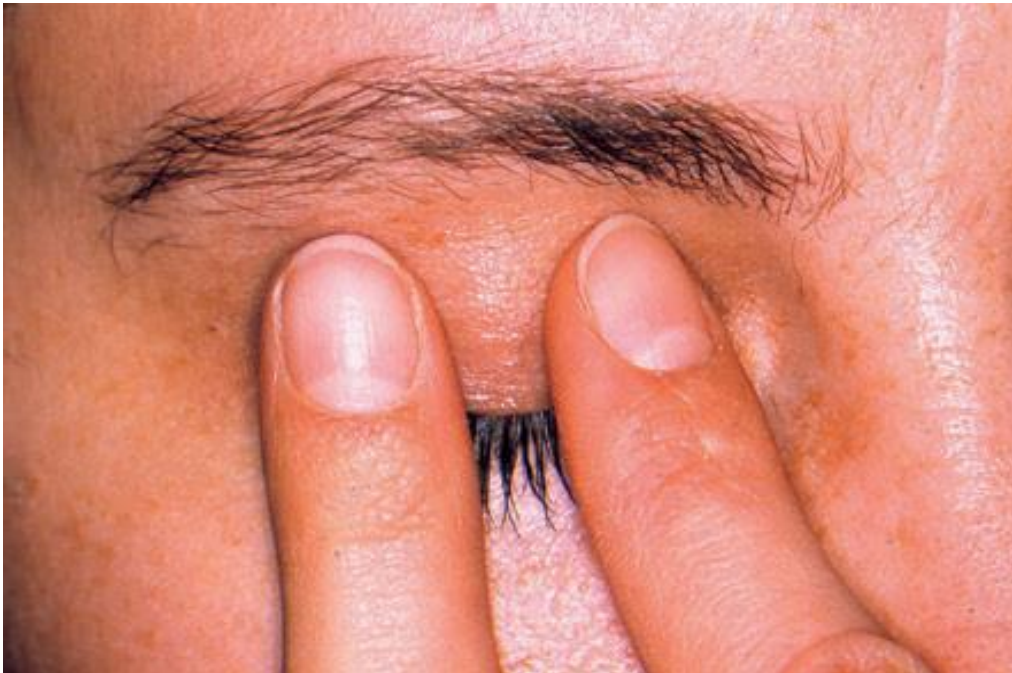

Figure 20 — finger tension

Tonometry. Accurate IOP may be determined by use of tonometers.

Applanation tonometry by the Goldmann tonometer (this is the standard method in many countries). Using a spring balance the pressure required to flatten a standard area of the anaesthetised cornea is estimated by an optical method. The tear film is stained with fluorescein and viewed with blue light through a plastic applanation head containing a prism splitting the image. The circular meniscus of contact is seen through the prism as two yellow semicircles (figure 21). The observer varies the pressure of applanation by a spring balance until the semicircles touch. The balance is calibrated to record directly in mm Hg. of intraocular pressure. It is less liable to error than the Schiøtz tonometer. The applanation tonometer is normally attached to a slit lamp microscope.




Figure 21 — Goldmann applanation tonometry

The pneumotonometer (figure 22) is an electronic tonometer that has its greatest use in patients with corneal scarring or alter. The soft tip of a blunt pencil-like device connected by wire to an electronic recorder is momentarily touched to the anesthetized cornea. Pressure is calculated by the jump in scale readings from baseline noncontact curve to that of the momentary touch flattening the cornea or indicated directly on a digital screen. The tonopen is portable, battery operated, and similar in use to the pneumotonometer.

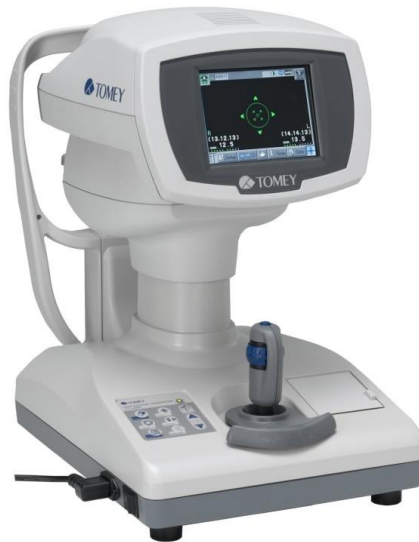

Figure 22 — Electronic pneumotonometer

5. TEAR FILM ADEQUACY: CLINICAL TESTS

Schirmer test. The purpose of this test is the measurement of the total (reflex and basal) tear secretion. To minimize reflex tearing, the eyes should not be manipulated before starting this test. There is no contraindication to this test. The materials used are commercially available Whatman no. 41 filter paper strips 5 mm wide 30 mm in length, known as Schirmer tear test filter strips (figure 23). The patient is seated in a dimly lit room, and the filter paper strips are folded 5 mm from the end. The folded end is placed gently over the lower palpebral conjunctiva at its lateral one-third. The patient keeps the eyes open and looks upward. Blinking and closing the eyes is permissible, although squeezing should be discouraged. After 5 minutes, the strips are removed and the amount of wetting is measured from the folded end. If the strips are completely wetted before 5 minutes, they may be removed prematurely. A normal patient will wet from 10 mm to 30 mm in 5 minutes; this is age dependent and decreases after the age of 60 years, but is rarely less than 10 mm in 5 minutes. Measurements greater than 30 mm at 5 minutes indicate that reflex tearing is intact but not controlled and, therefore, is of little diagnostic value. Between 10 mm and 30 mm of tear secretion may be normal, or basal secretion may be low but compensated for by reflex secretion.

Values less than 5 mm on repeated testing indicate hyposalivation of basic tearing. There is a 15 % chance of diagnostic error in this test.

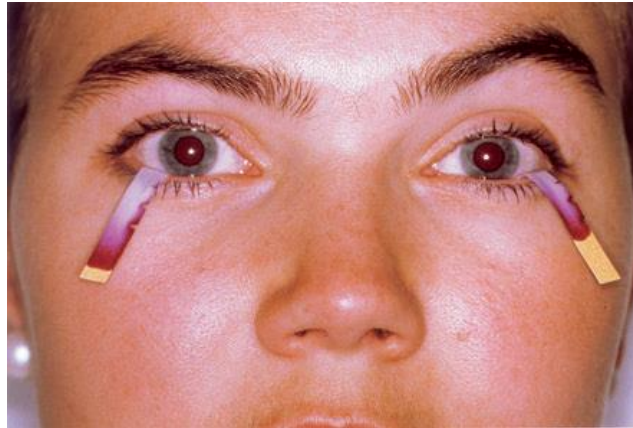


Figure 23 — Schirmer test

Rose bengal and lissamine green staining. The purpose of these tests is to ascertain indirectly the presence of reduced tear volume through detection of damaged epithelial cells. The eye is anesthetized topically with proparacaine 0,5 %. Tetracaine or cocaine may give false-positive tests because of their softening effect on corneal epithelium. One drop of 1 % rose bengal solution/lissamine green or a drop from a saline-wetted rose bengal/lissamine green solution is instilled in each conjunctival sac. Rose bengal and lissamine green are vital stains taken up by dead and degenerating cells that have been damaged by the reduced tear volume, particularly in the exposed interpalpebral area. These tests are particularly useful in early stages of conjunctivitis sicca and keratoconjunctivitis sicca syndrome. A positive test will show triangular stipple staining of the nasal and temporal bulbar conjunctiva in the interpalpebral area and possible punctate staining of the cornea, especially in the lower two-thirds. False-positive staining may occur in conditions such as chronic conjunctivitis, acute chemical conjunctivitis secondary to hair spray use and drugs such as tetracaine and cocaine, exposure keratitis, superficial punctate keratitis secondary to toxic or idiopathic phenomena, and foreign bodies in the conjunctiva. The stain will also color mucus and epithelial debris, which may mask the results. Certain patients who are normal will show some positive staining to rose bengal or lissamine green on the cornea. Because of this, conjunctival as well as corneal staining should be present before the diagnosis of keratoconjunctivitis sicca is made.

6. CORNEAL SENSITIVITY (ESTHESIOMETRY)

Should be ascertained prior to the instillation of topical anesthetics, particularly if the examiner is suspicious of herpetic viral disease. To determine corneal sensitivity, the cornea is lightly touched with a wisp of cotton drawn out to a few threads while the lids are held apart (figure 24). The approach should be from

the side so that the patient does not see the cotton tip coming toward him or her and reflexively close the eye.

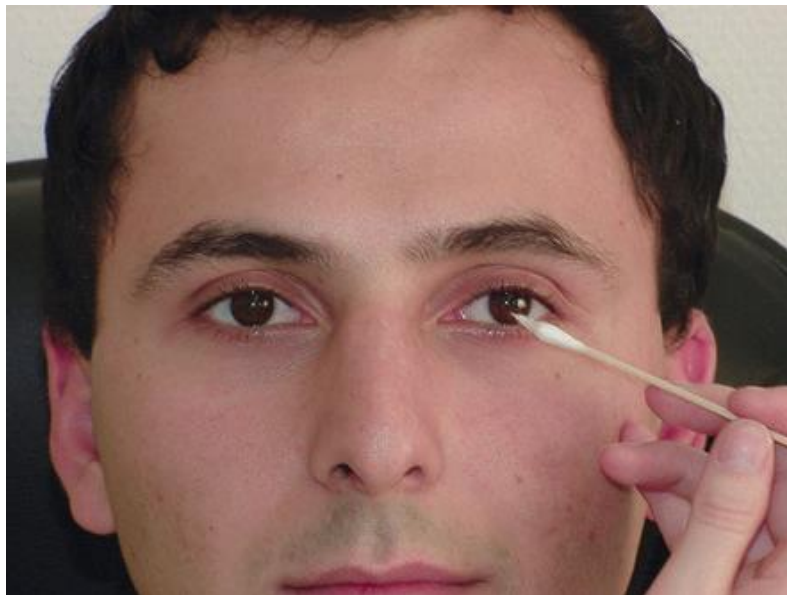

Figure 24 — Corneal sensitivity test

7. EXOPHTHALMOMETRY

The exophthalmometer (Hertel) is used to determine the degree of anterior projection or prominence of the eyes (figure 25). This instrument is helpful in diagnosing and in following the course of exophthalmos or enophthalmos. Technique. The patient holds his or her head straight and looks directly at the examiner's eyes. Two small concave attachments of the exophthalmometer are placed against the lateral orbital margins, and the distance between these two points is recorded from the central bar. This distance must be constant for all successive examinations in order to accurately judge the status of ocular protrusion. The examiner views the cornea of the patient's right eye with his or her left eye in the mirror. Simultaneously, the cornea is lined up in the mirror with the scale, which reads directly in millimeters the distance from the lateral orbital rim to the corneal apex. A similar reading is then taken from the left eye with the patient fixing on the examiner's right eye. The bar reading is then recorded in millimeters (e. g., a bar reading of 100 might have right eye 17 mm, left eye 18 mm). Interpretation. The normal range of exophthalmometry readings is 12 mm to 20 mm with an average value of 17 mm. The readings are normally within 2 mm of each other and indicate the anterior distances from the corneas to the lateral orbital margins. Exophthalmos is present if the reading is greater than 20 mm in one eye and may indicate a search for an underlying cause such as thyroid ocular disease or orbital tumor. A disparity of 3 mm or greater between readings taken from each eye during a test is also an indication for further investigation, even though both readings may fall within the normal range.

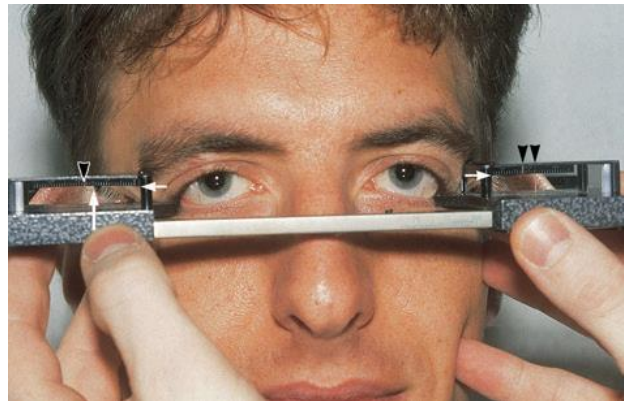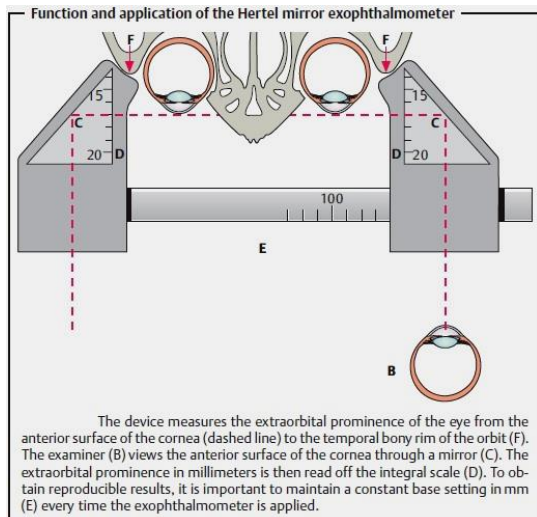


Figure 25 — Exophthalmometry

8. GONIOSCOPY

The visually inaccessible anterior chamber angle may be viewed directly with gonioscopic techniques that involve the use of a contact lens, focal illumination, and magnification. The contact lens eliminates the corneal curve and allows light to be reflected from the angle so that its structures may be seen in detail. Technique. This procedure may be performed with topical anesthetic drops at the slitlamp and such lenses as the Alan-Thorpe, Goldmann (figure 26), Sussman, or Zeiss, all of which have periscopic mirrors by which the angle is examined with reflected light. The patient may also undergo gonioscopy without the slitlamp while in the supine position when the Koeppel contact lens is used. The angle is viewed through a handheld microscope, with the Barkan light held in the other hand giving bright focal illumination. Greater magnification is achieved with the Koeppel lens than with lenses on the slitlamp, thereby allowing greater magnification of details of the angle, but this technique is used less frequently because of relative inconvenience compared to lenses applied with the patient at the slitlamp. Purpose. This technique is most useful in determining various forms of glaucoma, such as open-angle, narrow-angle, angle-closure, and secondary angle-closure glaucoma, by allowing evaluation of the angle width (distance of the iris root from the trabecular meshwork) and study of the tissues in the angle of the glaucomatous eyes at various stages. Gonioscopy is also of great use in examining other problems within the anterior chambers, such as retained intraocular foreign bodies hidden in the recess of the angle. It is useful in the study of iris tumors and cysts, as well as in the evaluation of trauma to the tissues in the area of the angle and identification of iris neovascularization. With wide pupillary dilation, the area behind the iris (posterior chamber), including ciliary processes, zonules, lens, and equator, may be seen in many patients.

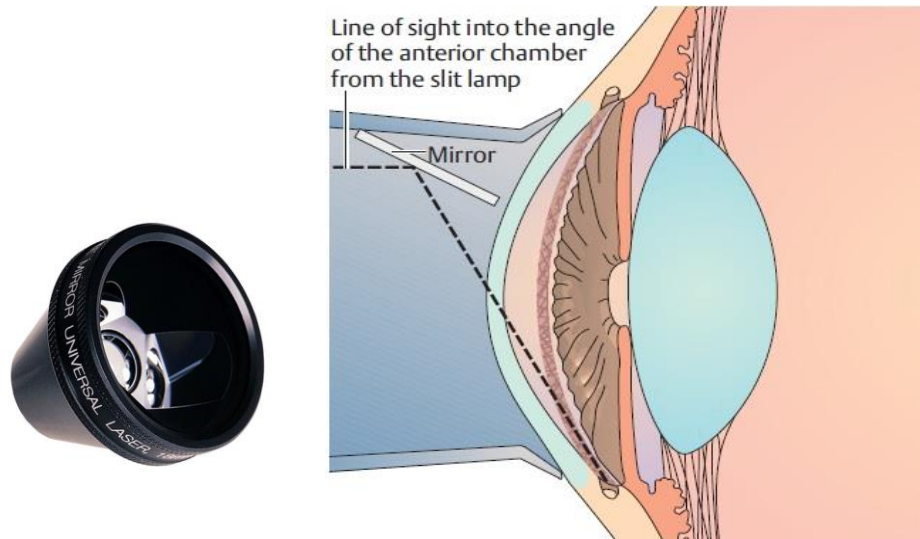


Figure 26 — Goldmann gonioscop

9. KERATOMETRY

The keratometer is an instrument generally used for measuring corneal astigmatism in two main meridians. It is particularly useful in the fitting of corneal contact lenses, but may also be used to detect irregular astigmatism and early pathologic states such as keratoconus. Successive readings several months apart will indicate progression or stability of corneal disease. The device is similar to a slitlamp in use. The corneal reflex is evaluated for regularity and measured at 90-degree axes in the two meridians of greatest difference, i. e., the flattest and steepest planes.

10. CORNEAL TOPOGRAPHY

Is done with computerized machines, which use video capture and analysis of concentric circle Placido disk images to produce videokeratographs in the form of color-coded dioptric contour maps (figure 27). These maps show even subtle variations in power distribution plots and can calculate the power and location of the steepest and flattest meridians, similar to values given by a keratometer. Cool colors are lower in power than warm colors (e. g., blue = flat, red = steep, green = normal). Corneal diagnosis and changes may be monitored by sequential topography and include disorders such as keratoconus, contact lens warping of the cornea, postoperative healing patterns (laser and incisional; keratoplasty, cataract, tight sutures, radial keratotomy, excimer laser photorefractive keratectomy), marginal degenerations, and keratoglobus. Corneal topography is very important in the preoperative evaluation of refractive surgery patients. Patients with keratoconus or pellucid marginal degeneration are not routinely considered for refractive surgery. Even subclinical or form fruste keratoconus is considered a contraindication for LASIK surgery. Corneal topography is also

invaluable in the management of post-keratoplasty astigmatism and aids in deciding the order of sutures that must be removed.

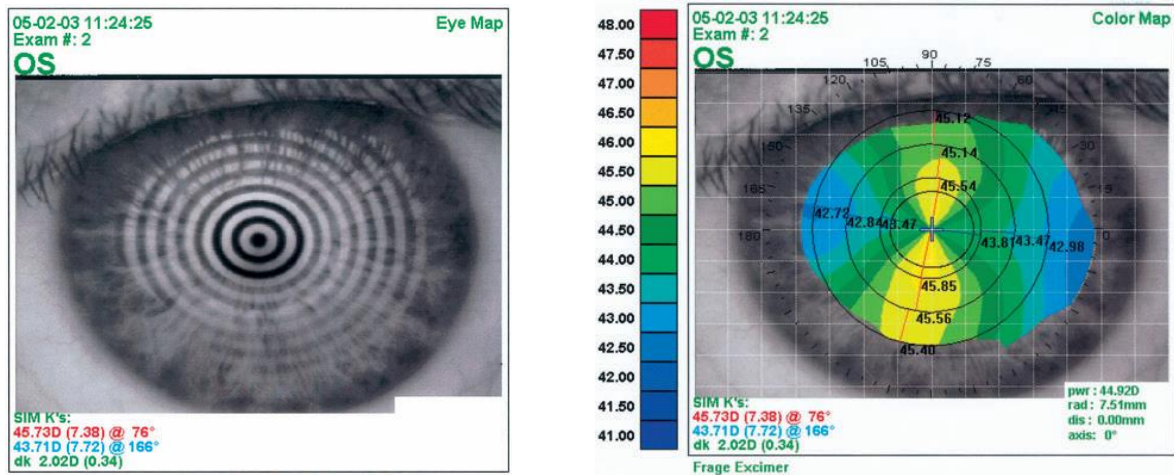


Figure 27 — Corneal topography

11. CORNEAL PACHYMETRY

Pachymeters measure corneal thickness and are good indicators of endothelial function (figure 28). While thick corneas may suggest Fuchs' endothelial dystrophy, thin corneas may be an indicator for keratoconus. Further, corneal thickness determines whether a patient is a candidate for refractive surgery and which procedure is more appropriate. Normal central corneal thickness is 0,52 to 0,54 mm, and is 0,63 to 0,67 mm peripherally.

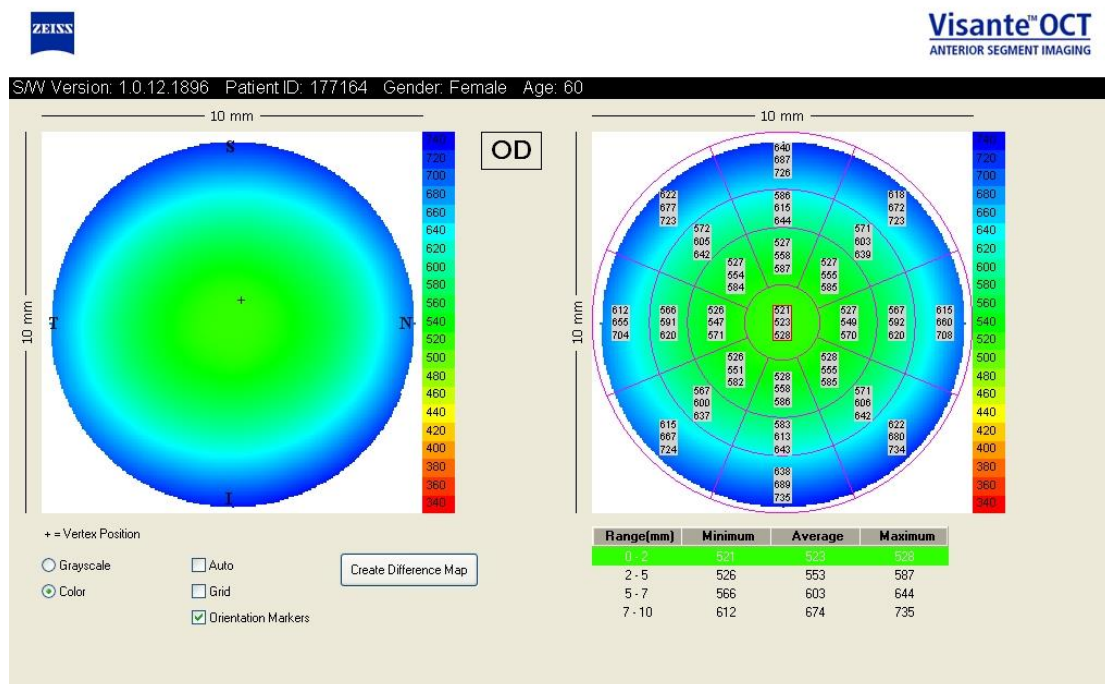


Figure 28 — Pachymetric map

12. FLUORESCEIN AND INDOCYANINE GREEN (ICG) ANGIOGRAPHY OF THE FUNDUS

Purpose. Fluorescein angiography (FA) has proved to be a valuable tool in the diagnosis and management of a large number of retinal disorders that affect the retinal vascular system or the choriocapillaris, Bruch's membrane, or the pigment epithelial layers. Disease states particularly amenable to evaluation by angiography include diabetic retinopathy (figure 29), ocular histoplasmosis, macular edema, idiopathic preretinal macular fibrosis, age-related macular degeneration, retrolental fibroplasia, vascular occlusive disease, flecked retina syndrome, sickle cell retinopathy, viral retinopathy, retinal telangiectasis, von Hippel-Lindau disease, Eales disease, choroidal tumor, both primary melanoma and metastatic carcinoma, and benign hemangioma.

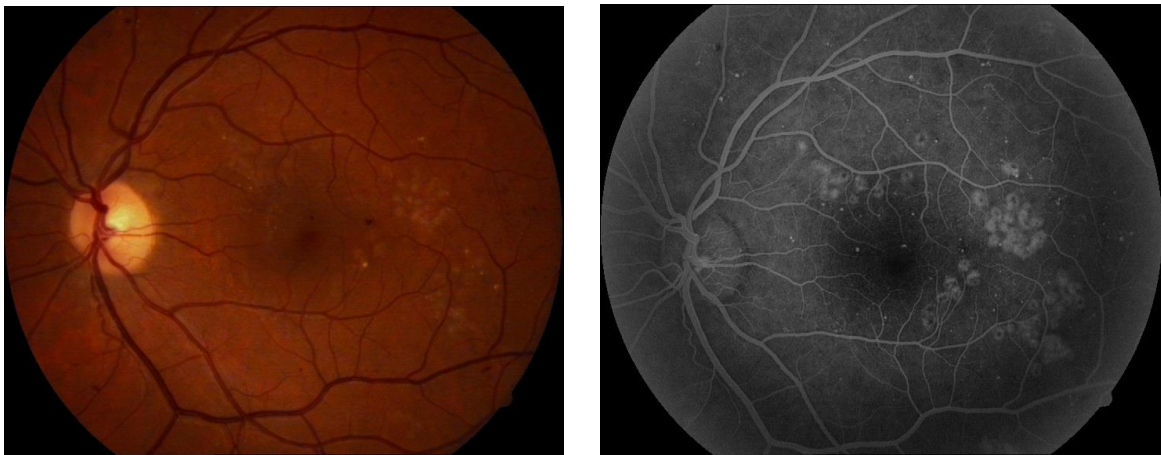


Figure 29 — Fluorescein angiography of the fundus in diabetic retinopathy

13. ULTRASONOGRAPHY (echography)

Diagnostic ocular ultrasonography (figure 30) allows the detection of intra-ocular abnormalities not visualized clinically because of opacification of the cornea, anterior chamber, lens, or vitreous, as well as pathologic processes involving the periorbital tissues. It provides similar information as a computed tomography (CT) scan. This technique has an advantage over x-rays or CT scans because it is a dynamic examination allowing innumerable views, including studies of the moving globe. Ultrasonography consists of the propagation of high-frequency sound waves through soft tissue, with the differential reflection of these waves from objects in the beam pathway. The reflected waves create echoes that are displayed on an oscilloscope screen, producing a picture that is amenable to clinical interpretation. Because of the highly sophisticated and expensive equipment involved and the necessity of dynamic interpretation of data, this technique is performed only by specialists within the field.

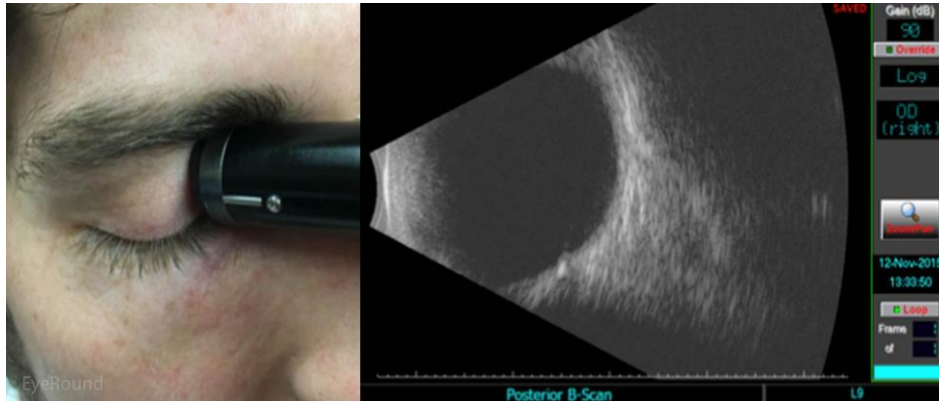
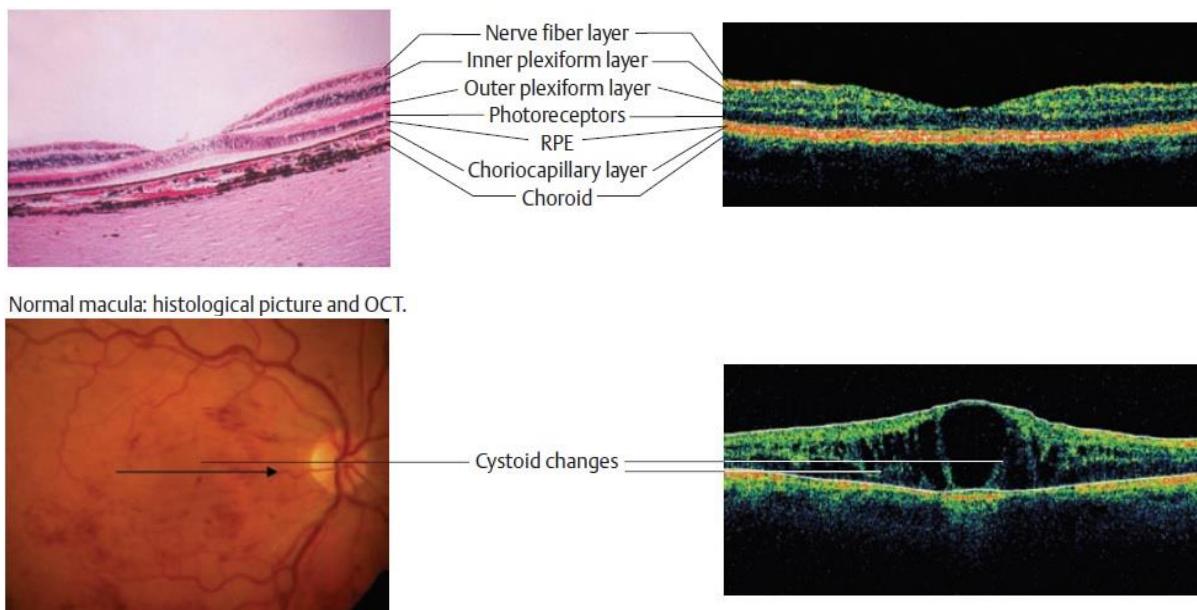


Figure 30 — Ultrasonography

14. OPTICAL COHERENCE TOMOGRAPHY (OCT)

OCT is a noncontact, noninvasive, high-resolution, cross-sectional imaging technique that does not require immersion of the eye and can detect and measure changes in tissue thickness with micron-scale sensitivity to produce high-resolution measurements and images of the eye. This system uses a 40 B μ m low coherent light to penetrate the tissue and contains a camera to analyze reflected images. The light is reflected back from the tissue, giving an image similar to ultrasonography. However, instead of using sound, it uses infrared light waves. The acquired image provides around 500 points of information from the depth at a single point. Hundred scans are put together to provide a linear cross-section of the tissue. In addition, the image shows colors that correspond to the reflectivity of the tissue. Highly reflected tissues such as RPE or nerve fiber layer are shown as red or white, while low reflected tissues such as photoreceptors or the choroid are shown as blue or black (figure 31).



Normal macula: histological picture and OCT.

Cystoid maculopathy, hemorrhages and microaneurysms in diabetic retinopathy.

Figure 31 — Optical coherence tomography

REFERENCES

1. *Khurana, A. K.* Comprehensive Ophthalmology / A. K. Khurana. — New Delhi: New Age International, 2014. N. pag. Print.
2. *Duane, T. D.* Clinical Ophthalmology. Hagerstown, MD: Medical Dept / T. D. Duane. — Harper & Row, 1976.
3. *Duane, T. D.* Duane's Clinical Ophthalmology / T. D. Duane, W. Tasman, A. Edvard. — Philadelphia: Lippincott, 1991.
4. *Kanski, J. J.* Clinical Ophthalmology: A Systematic Approach / J. J. Kanski. — Edinburgh: Butterworth-Heinemann/Elsevier, 2007.
5. *Lang, G. K.* Ophthalmology: Pocket textbook. Stutthard: Appl Aprinta Druck / G. K. Lang. — Wending, 2006.
6. *Spalton, D. J.* Atlas of Clinical Ophthalmology / D. J. Spalton. — Philadelphia: Elsevier Mosby, 2005.
7. *Crick, R. P.* A Textbook of Clinical Ophthalmology: A Practical Guide to Disorders of the Eyes and Their Management. River Edge / R. P. Crick, P. T. Khaw. — NJ: World Scientific, 2003.
8. *Yanoff, M.* Ophthalmology. Edinburgh / M. Yanoff, J. S. Duker. — Mosby, 2008.

Учебное издание

**Дравица Людмила Владимировна
Альхадж Хусейн Анас
Садовская Ольга Петровна**

**КЛИНИЧЕСКИЕ
МЕТОДЫ ИССЛЕДОВАНИЯ
ОРГАНА ЗРЕНИЯ
(на английском языке)**

**Учебно-методическое пособие
для студентов 4–6 курсов лечебного факультета
и факультета по подготовке специалистов для зарубежных стран
медицинских вузов**

Редактор ***Т. М. Кожемякина***
Компьютерная верстка ***Ж. И. Цырыкова***

Подписано в печать 15.05.2017.
Формат 60×84^{1/16}. Бумага офсетная 80 г/м². Гарнитура «Таймс».
Усл. печ. л. 2,56. Уч.-изд. л. 2,80. Тираж 120 экз. Заказ № 262.

Издатель и полиграфическое исполнение:
учреждение образования «Гомельский государственный медицинский университет».
Свидетельство о государственной регистрации издателя,
изготовителя, распространителя печатных изданий № 1/46 от 03.10.2013.
Ул. Ланге, 5, 246000, Гомель